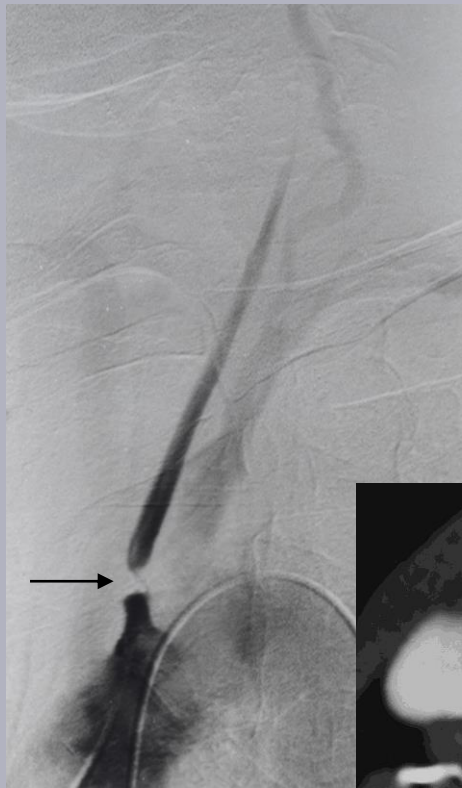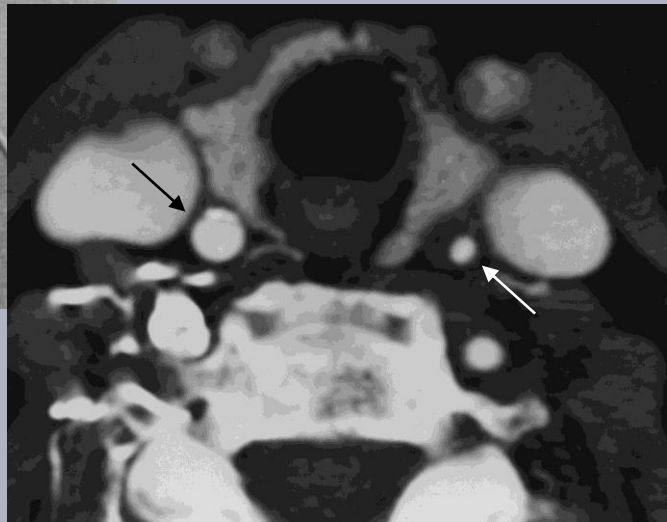


a.



b.

**Figure 17.** a. DSA image demonstrates subtotal occlusion of the left CCA (arrow). b. Axial CT image shows the normal caliber right CCA (black arrow), and the reduced diameter of the left CCA (white arrow).