

**Slings and meshes in the therapy of prolapse and urinary incontinence:
Efficacy and side-effects**

Ph.D. Thesis

Zoltan Fekete, M.D.

University of Szeged
Faculty of Medicine
Department of Obstetrics and Gynaecology

Supervisors:

Gábor Németh, M.D., Ph.D., Med. Habil.

University of Szeged
Faculty of Medicine
Department of Obstetrics and Gynaecology

Zoltán Bajory, M.D., D.Sc.

University of Szeged
Faculty of Medicine
Department of Urology

Director of Doctoral School of Clinical Medicine:

Lajos Kemény, M.D., D.Sc.

Director of Reproductive Health Programme:

György Bártfai, M.D., D.Sc.

University of Szeged
Faculty of Medicine
Department of Obstetrics and Gynaecology and Urology
Albert Szent-Györgyi Medical Centre

Szeged, 2018

CONTENTS

LIST OF PAPERS RELATED TO THE SUBJECTS IN THE THESIS	4
LIST OF ABBREVIATIONS	5
SUMMARY	6
1. INTRODUCTION	8
1.1. Urinary incontinence	8
1.1.1. Urethral anatomy and the Pathomechanism of SUI	8
1.1.2. Operative treatment of SUI	10
1.1.2.1. Background of operative treatment	10
1.2. Pelvic Organ Prolapse	12
1.2.1. Pathomechanism of POP	12
1.2.2. Staging of POP	13
1.2.3. Treatment of POP	14
1.3. Complications of urogynaecological operations	15
2. AIMS OF THE THESIS	16
3. HYPOTHESIS	16
4. MATERIALS AND METHODS	17
4.1. The experimental protocol in Study 1	17
4.1.1. Material and methods	18
4.1.2. Exclusion criteria	18
4.1.3. Efficacy criteria	18
4.1.4. Diagnosing DNUS	19
4.1.5. Side-effects under examination	19
4.1.6. The operative method used	19
4.1.7. Statistical analyses	20
4.2. The experimental protocol in Study 2	20
4.2.1. Material and methods	21
4.2.2. Efficacy criteria	21
4.2.3. The operative method used	21

4.3.	The experimental protocol in Study 3	23
4.3.1.	Materials and methods	24
4.3.2.	Exclusion criteria	24
4.3.3.	Efficacy criteria	24
4.3.4.	The recently invented device	24
4.3.5.	The surgical technique	25
4.3.6.	Statistical analysis	26
4.4.	The experimental protocol in Study 4	26
4.4.1.	Material and methods	27
4.4.2.	Introital ultrasound findings	28
4.4.3.	Inclusion criteria	28
4.4.4.	Exclusion criteria	28
4.4.5.	Operative method	29
4.4.6.	Efficacy criteria	30
4.4.7.	Data collection	31
4.4.8.	Sample size calculation	32
4.4.9.	Statistical analyses	33
5.	RESULTS	35
5.1.	Comparison of the effectiveness of vaginal prosthesis and colporrhaphy operations	35
5.2.	Effectiveness of Lehoczy's island flap method in reconstructing the mesh related bladder perforation	39
5.3.	Feasibility of the Self-Retaining Support Implant in the POP-Q Stage 2-4 reconstruction	40
6.	DISCUSSION	44
7.	LIMITATIONS OF THE METHODS USED	48
8.	CONCLUSION	49
9.	REFERENCES	50
10.	ACKNOWLEDGEMENTS	57
11.	APPENDIX	58

LIST OF PAPERS RELATED TO THE TOPICS IN THE THESIS

List of full papers

1. Bajory Z, **Fekete Z**, Kiraly I, Szalay I, Pajor L. (2011) Consecutive vesicovaginal fistula for transobturator sling perforations and successful repairs with skin flap. Neurourol. Urodynamics; 30(8):1530-2. doi: 10.1002/nau.21114. **IF: 2.67**
2. Levy G, Padoa A, **Fekete Z**, Bartfai G, Pajor L, Cervigni M. (2017) Self-retaining support implant: an anchorless system for the treatment of pelvic organ prolapse-2-year follow-up. Int. Urogynecol J; 29(5):709-714. doi: 10.1007/s00192-017-3415-3. **IF: 1.93**
3. **Fekete Z.**, Surányi A., Rénes L., Németh G., Kozinszky Z., (2017) Efficacy of anchoring the four-arm transvaginal mesh to the mid-urethra vs original surgery as a surgical correction for stress urine incontinence in coexisting anterior vaginal prolapse grades II and III: study protocol for a randomized controlled trial. BMC Trials; 18(1):624. Doi: 10.1186/s13063-017-2314-8. **IF: 1.96**
4. **Fekete Z.**, Kőrösi Sz., Németh G., (2018) Hüvelyi hálóműtétek gyakorlata az amerikai korlátozó figyelmeztetés után Merjem, vagy ne merjem? [The vaginal mesh operations in the urogynecological practice after the FDA warnings. Use or not to use mesh?] Orv Hetil. 2018; 159(10): 397–404 p Doi: 10.1556/650.2018.30963 **IF: 0.349**

LIST OF ABBREVIATIONS

ANOVA	Analysis of Variance
anti-SUI	anti-stress incontinence
ATFP	arcus tendinous fascia pelvis
BMI	body mass index
CD	Clavien–Dindo classification
CRADI-8	Colorectal Anal Distress 8
DNUS	<i>de novo</i> urge symptoms
FDA	US Food and Drug Administration
ICS	International Continence Society
ISD	intrinsic sphincter deficiency
MUI	mixed type urinary incontinence
PFDI-20	Pelvic Floor Disability Index 20
PISQ-12	Pelvic Organ Prolapse/Urinary Incontinence Sexual Questionnaire `
PMFT	pelvic floor training
POP	pelvic organ prolapse
POPDI-6	Pelvic Organ Prolapse Distress Inventory 6
POP–Q	Pelvic Organ Prolapse Quantification
SUI	stress urinary incontinence
SRS	Self Retaining Support System
TVT	tension-free vaginal tape
TVT-O	transobturator sling
UDI-8	Urinary Distress Inventory 8
UHM	urethral hypermobility
UI	urinary incontinence
UUI	urge urinary incontinence
UTI	urinary tract infection
VVF	vesicovaginal fistula

SUMMARY

Pelvic organ prolapse (POP) is an important health issue for women, with up to 20% of women undergoing one or more operations to correct prolapse over their lifetime [1]. The reported rate of stress urinary incontinence (SUI) coexisting with POP is as high as 63–80% [2]. The classical anterior colporrhaphy has a high relapse rate for anterior compartment descent (26–58%), and anti-SUI effectiveness of this non-prosthesis method is only negligible (42%–62%) [3,4], so according to the current guidelines anterior colporrhaphy is not indicated in case of SUI. It is also known that the postoperative complication rate for very effective prosthesis operations is high. Permanent implants have been associated with higher rates for *de novo* stress incontinence (relative risk 1.39), bladder perforation (relative risk 3.92) and postoperative dyspareunia [5].

Synthetic transvaginal mesh has been employed in the treatment of POP with increasing popularity and is usually highly effective in controlling the principal symptoms of prolapse. Based on the US Food and Drug Administration (FDA) warnings of 2008 and 2011, specialists should arrive at a more precise balance between the low success rate for non-mesh techniques and the higher number of postoperative complications of prosthesis methods [6]. Therefore, in a retrospective study, we aimed to evaluate and compare anti-POP efficacy, anti-stress incontinence (anti-SUI) efficacy, and the early (six weeks) and late (36 months) postoperative complication rates for anterior vaginoplasty and the most commonly used transvaginal mesh (TVM) operations. In our series, we found that the TVM operations were significantly better in the reconstruction of POP (91.3% vs. 66.3%; $p < 0.001$) and SUI (90% vs. 55%, $p < 0.001$) after three years of follow-up. Hence, in our study, *de novo* urge incontinence (DNUS) was significantly more frequently observed (11.86% vs. 0%). Extrusion of the implanted mesh was found in 8.3% of cases involving a prosthesis.

In our cases, the implanted mesh was fixed to the peri-urethral tissue with two anchoring stitches, as we had hypothesised; this is superior to the original TVM for anti-incontinence. Previous studies have reported that mesh operations provide unfavourable SUI cure rates. Therefore, the anchoring used as additional anti-incontinence surgical strategies is increasingly being scrutinized to achieve better postoperative continence without any significant side-effects for

patients with both POP and SUI. A randomized prospective study was designed to evaluate the anti-SUI effectiveness of that anchoring technique.

Mesh contraction and bunching may cause nerve entrapment as well as excessive tension on the fixed mesh arms, which both lead to pain. It is documented that mesh folding and contraction are among the reasons for chronic pelvic pain, dyspareunia and mesh extrusion. A new concept involving an anchorless implant was developed to reduce the side-effects of prosthesis operations. The assumption was that an anchorless neo-pubocervical fascia would accurately mimic the physiological support system, therefore providing adequate support. A new type of mesh was designed with a flexible frame. In our multi-centre study, seventeen patients (84.2%) had Stage 0 prolapse and three patients (15.8%) had Pelvic Organ Prolapse Quantification system (POP-Q) (International Continence Society (ICS)) Stage 1 prolapse after two years of follow-up. No cases of mesh erosion or chronic pelvic pain were documented at follow-up.

There has been a drop in the rates for intra-operative bladder perforations and vesicovaginal fistulas (VVF) after the introduction of infra-pubic operative techniques, but the suitable reconstructive technique is still questionable. We reintroduced an “oldy but goody” operative technique of Lehoczy’s island flap implantation for prosthesis-induced VVF. In our short series, all the operated cases were free of fistulas after three months of follow-up.

Although the rate for concomitant SUI in patients with POP is as high as 63–80% [2], the effective treatment for coexisting SUI and POP is still debated. The anti-SUI efficacy of the prosthetic placement is barely 72–83% [34-36]. Therefore, the research group developed a modification to the transobturator four-arm TVM to increase its anti-incontinence effect. The proposed modification to the original surgical procedure includes the suture of the anterior part of the mesh to the mid-urethra to prevent the mesh sliding. We think that the appropriate elevation of the mid-urethra would thus occur with the anterior arms and that would achieve a more effective anti-incontinence. We designed a single-centre, prospective, double-blind (participant, investigator/surgeon, outcome assessor), randomized, controlled trial to evaluate the anti-SUI success rate for the modified TVM.

1. INTRODUCTION

The rapid development of technology and progress in the medical sciences have resulted in an amazing extension of life expectancy at the time of birth, so an aging population has presented the healthcare system with new challenges. Two main urogynaecological symptoms, such as stress urinary incontinence (SUI) and pelvic organ prolapse (POP), have been prevalent lately, and the cumulative risk of surgery for POP by the age of 80 years has been estimated at 11.1% [1].

1.1. Urinary incontinence

The International Continence Society (ICS) defines urinary incontinence (UI) as the complaint of any involuntary loss of urine [7]. Urinary incontinence is highly prevalent. Several authors report that UI may affect up to 22.7% of women in Europe [2]. The prevalence of UI increases with rising age. Almost half of these women have SUI, 11% have urge urinary incontinence (UII), and 36% have the mixed type (MUI) [8].

1.1.1. Urethral anatomy and the pathomechanism of SUI

The mechanism of female urinary continence is based on three different factors. First, the urethra and bladder neck are supported by the interaction of the pubourethral ligaments, the perineal membrane and the muscles of the pelvic floor. The pubourethral ligaments extend from the inferior edge of the pubic bone to the anterior surface of the urethra. The proximal urethra and the bladder base are supported by the vaginal musculofascial attachments, which is a sling-like tissue formed by the anterior vaginal wall. The structure is attached bilaterally to the levator ani muscles at the level of the arcus tendinous fasciae pelvis [9] (Figure 1).

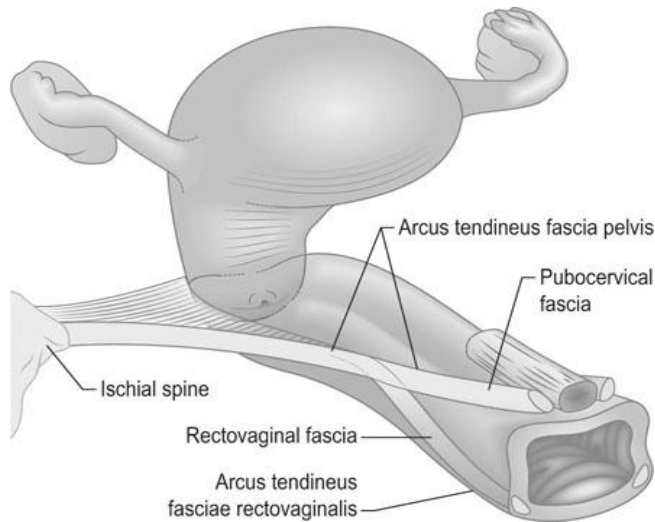


Figure 1. The lateral attachments of the pubocervical fascia (PCF) and the rectovaginal fascia (RVF) to the pelvic sidewall

These attachments contribute to the urethral closure by providing a stable base onto which the proximal urethra and bladder neck are compressed by increasing intra-abdominal pressure during physical activities. The anatomical defects of the pubourethral ligaments and paravaginal fascia are contributing factors in urethral hypermobility (UHM) as a form of SUI in women. The contraction of the levator ani muscles elevates the anterior vaginal wall, thus causing it to cover the bladder neck and proximal urethra, leading in turn to bladder neck closure, according to the Hammock hypothesis [10].

Second, a normal tone and innervation of the urethral sphincter is needed to achieve urinary continence. The sphincter urethrae, urethrovaginal sphincter and compressor urethrae are all parts of the urethral sphincter. The urethral sphincter is a rhabdosphincter, a circular muscle encompassing the urethral lumen. The other two somatic muscles of the female urethral sphincter (compressor urethrae and urethrovaginal sphincter) that arch over the urethral lumen apply downward compression with contraction against the fixed anterior vaginal wall. The pudendal nerve (S2–S4) innervates all the muscles (Figure 2).

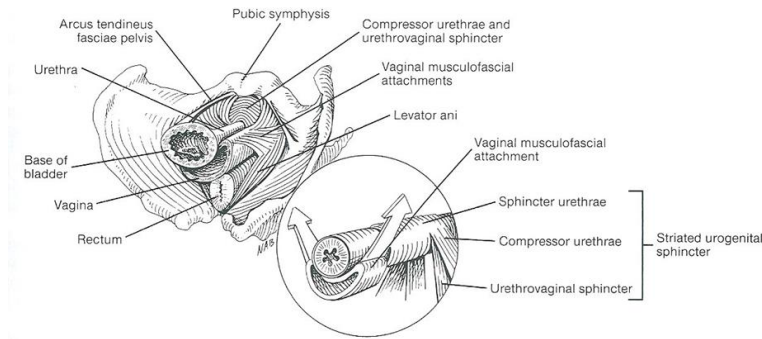


Figure 2. The muscular layers and connective tissues at the level of the urethra (Walters M.D, Karram M.M. Urogynecology and Reconstructive Pelvic Surgery.

Third Edition ISBN 0-323-02902-7).

Any failure at the level of the striated urogenital sphincter may lead to intrinsic sphincter deficiency (ISD).

Finally, the urethral wall itself must be sufficiently soft so that external forces can act on it to effect closure. The clinical importance of a rigid urethra is great. Multiple suburethral operations like tape implantations or irradiation may lead to what is referred to as a “water-pot” urethra, which has poor urethral closure properties.

1.1.2. Operative treatment of SUI

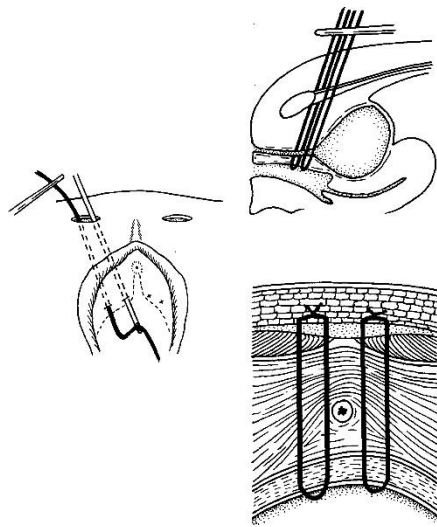
The treatment of SUI associated with UHM and ISD has included a wide variety of surgical procedures.

1.1.2.1. Background of operative treatment

The first suburethral sling procedure was described in 1907, and several types of muscular or fascial sling modifications were used in the last century. The most popularly and extensively used sling variation was introduced by Aldrige in 1942 [12]. To overcome the limitations of using autologous fascia or muscle for slings, such as poor quality of autologous tissue, and the need for harvesting procedures with high morbidity, synthetic materials began to be used for sling grafts. Until the 1990s, anterior colporrhaphy with Kelly-Stoeckel plication, Burch colposuspension or transvaginal needle suspension methods like Pereyra, Stamey and Gittes’ operations were used for the repair of SUI [11]. According to the Pereyra suspension technique, two small suprapubic incisions are made. No vaginal incision is required. The Pereyra needle is passed twice on each

side of the urethra from the rectus fascia through the full thickness of the vaginal mucosa at the level of the urethrovesical junction [13] (Figure 3).

Figure 3. The Pereyra operation (Richardson D.A. Preliminary report: Modification of the needle urethropexy in the management of stress incontinence. Int Urogynecol J (1991) 2: 123).



Tension-free vaginal tape (TVT) surgery was developed by Ulmsten and Petros in the 1990s [14]. The concept behind the suburethral procedures is that SUI results from the weakness of the pubourethral ligaments. Since TVT, the mid-urethral sling operation has become the first-line gold standard therapy for correction of female SUI. In 2001, the original procedure was modified by Delorme and described as the transobturator sling (TVT-O) method [15] (Figure 4). The advantages of the needle passage modification to the obturator

zone are the less prevalent complications in vascular, bladder or bowel injuries. Nowadays, these sub-urethral sling methods are the first-line operative treatments for SUI according to the current international guidelines.

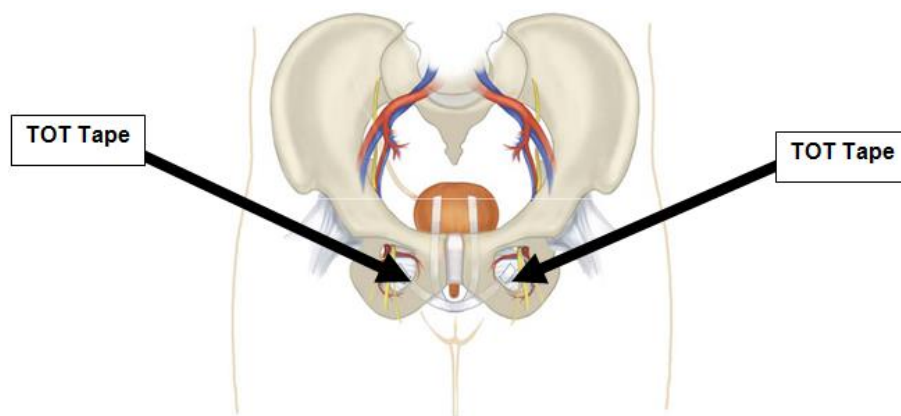


Figure 4. The transobturator tape technique by Delorme

1.2. Pelvic organ prolapse

The other common urogynaecological condition is POP. Incidence increases with age. The risk of reconstructive surgery for women aged over 50 years is 3.3 per 1000 women [16]. The most common form of pelvic descent is the anterior vaginal prolapse, which according to the ICS standardized terminology for prolapse is preferred over the old term cystocele.

1.2.1. Pathomechanism of POP

The cause of anterior vaginal prolapse is multifunctional, with different reasons suggested for POP. The anatomical support for pelvic organs is provided by interactions of pelvic connective tissue and musculature. The upper part of the vagina lies on the levator plate and is stabilized by connective tissues superiorly and laterally. The upper vagina in conjunction with the uterus cervix is supported by connective tissue attachments to the sacrum, coccyx and lateral pelvic sidewalls. These supportive tissues are identified as cardinal and uterosacral ligaments. The vagina is attached anteriorly to the endopelvic fascia, which is a musculofascial layer attached to the arcus tendinous fasciae pelvis on both sides laterally. It is of importance that a real fascia is not presented histologically between the adjacent organs, such as the rectum, vagina and bladder; the pubocervical and rectocervical fascia is simply formed by a firming of the vaginal muscularis [17] (Figure 5). Loss of support may result in POP. Two types of anterior vaginal prolapse are known: displacement and distension [17]. Distension results from overstretching and weakening of the paravaginal fascia and the vaginal wall with vaginal delivery or atrophic changes after menopause. The loss of midline support of the paravaginal fascia ends in an absence of rugal folds and a protrusion of the bladder into the vagina. The other type of anterior vaginal prolapse was ascribed to elongation of the anterolateral vaginal supports to the arcus tendinous fasciae pelvis. This can occur unilaterally or bilaterally with urethral hypermobility and a different degree of apical prolapse.

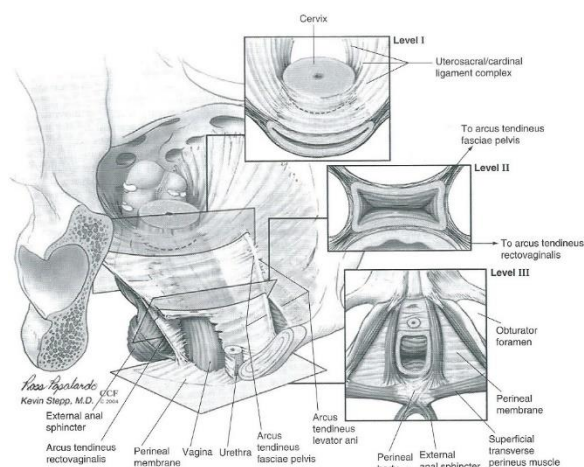


Figure 5. Integrated levels of support by DeLancey (1992) (Walters M.D., Karram M.M. Urogynecology and Reconstructive Pelvic Surgery. Third Edition ISBN 0-323-02902-7).

1.2.2. Staging of POP

A systematic classification of POP is useful to aid in documenting and communicating the severity of the pelvic organ descent. Lately, two classification systems have been in use, but the ICS standardization of terminology is preferred for clinical and scientific work [18]. For many years, the severity of POP has been described by the criteria published by Baden et al. (in 1968) [19]. The Baden–Walker system was simple for gynaecological surgeons to use and easy for them to understand. This system has been found to have broad interobserver variability for all segments of the female pelvis.

The Pelvic Organ Prolapse Quantification (POP–Q) system contains a series of site-specific measurements of female pelvic organ support. Prolapse in each segment is assessed and measured relative to the hymen. The anatomical position of the six evaluated points for measurement should be a certain number of centimetres above the hymen (negative number) or a certain number of centimetres below the hymen (positive number) or located at the level of the hymen, which is defined as zero. In describing the anterior vaginal wall, the term anterior vaginal wall prolapses or anterior–middle compartment descent is preferable instead of cystocele or anterior enterocele. The uterus or vault descent is described as an apical prolapse, and the terms posterior wall prolapse and posterior compartment descent are preferable to the term rectocele (Figure 6).

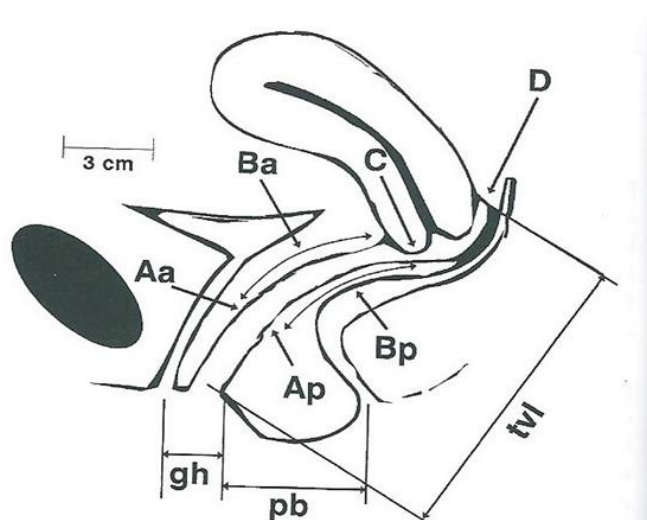


Figure 6. The predetermined points of the female pelvis according to the POP-Q system (Walters M.D, Karram M.M. *Urogynecology and Reconstructive Pelvic Surgery. Third Edition* ISBN 0-323-02902-7).

1.2.3. Treatment of POP

Historically, the aim of anatomical repair of anterior vaginal wall defects was the plication of the pubovesical fascia (layers of vaginal muscularis and adventitia covering the bladder wall) to reduce the protrusion of the bladder to the vagina. The cystocele repair was modified several times depending on how laterally the dissection was carried out, where the placating sutures were placed and whether additional layers (natural or synthetic) were placed for extra support of the anterior vaginal wall. Nowadays several types and shapes of prosthetic material are used to aid in support. The anchoring points of the inserted mesh are usually at or near both side of the arcus tendinous fasciae pelvis and/or the sacrospinal ligaments or the bilateral obturator fascia. Vaginal prosthetic surgery has been proposed for anterior compartment POP-Quantification (Q) Stage 2–3 (ICS) [20] in view of the low recurrence rate (6.7–24%) [5,21–23] relative to that after classical anterior colporrhaphy (30–40%) [5,22,24]. A recent Cochrane review confirms the superiority of repairing prolapse of the mid-anterior vaginal wall with permanent mesh over native tissue repair [5]. However, a worldwide spread of a range of vaginal mesh operations has resulted in a huge number of complications (e.g. infection, extrusion and *deNovo* urge symptoms). Consequently, the US

Food and Drug Administration has published warnings with the aim of restricting the use of vaginal prosthesis to centres with specially trained surgeons after patients have been thoroughly informed [6]. Furthermore, it is assumed that a combination of a synthetic mesh with the sling operation [25–27] will substantially increase the cure rate for concomitant SUI. In contrast, the combined techniques represent an increased complication rate and elevated financial burden.

Despite the availability of a wide variety of prolapse surgeries, there is no consensus on the optimal treatment, and the effectiveness of the treatment of severe side-effects, such as protrusion or bladder perforation, is questionable. Coexisting stress urinary incontinence (SUI) and pelvic organ prolapse (POP) are highly prevalent (63–80%) [2].

1.3. Complications of urogynaecological operations

The potential complications of using transvaginal mesh are wide-ranging, from mild to seriously life-threatening. The most common complications, as reported in the US Food and Drug Administration (FDA) Public Health Notification, include mesh erosion at the site of vaginal incision, lower urinary tract infection, pelvic pain, dysuria, recurrence of prolapse or incontinence, *de novo* UUI, *de novo* SUI dyspareunia, and perforation of the bowel, and/or vessels during mesh insertion [5]. Due to the very low rate for bladder perforation [28,29], the VVF formation is an extremely rare but severe complication of prosthesis methods [30,31].

Many of these complications require additional interventions, including medical or surgical treatments and hospitalization.

The FDA recommends that healthcare providers should inform patients that implantation of surgical mesh is permanent and that some complications associated with the implanted mesh may require additional surgery that may or may not correct the complication. Healthcare providers should thus choose mesh surgery only after weighing the risks and benefits of surgery with mesh versus all non-mesh surgical and non-surgical alternatives.

2. AIMS OF THE THESIS

- The aims of our series were to ascertain the feasibility of vaginal prosthesis operations following the FDA warnings.
- We examined an “oldy but goody” method for the of some of the most serious mesh-related complications, including VVF.
- We investigated the long-term utility of a newly developed anterior vaginal mesh method for the correction of POP–Q Stage 2–4 anterior vaginal prolapse.
- We designed a prospective randomized study for evaluating the effectiveness of an alternative operative method for reconstructing POP–Q 2–3 concomitant with genuine SUI.

3. HYPOTHESIS

Several incongruities can be found in the available literature on the effectiveness and side-effects of vaginal prosthesis operations. Therefore, a retrospective study was organized to ascertain the feasibility of vaginal prosthesis operations in our practice following the FDA warnings. We hypothesised that the long-term success rates for TVM operations on POP and SUI reconstruction with an acceptable frequency of side-effects are better than those found in the literature.

Vesicovaginal fistula (VVF) formation is an extremely rare but embarrassing complication of mesh methods [30,31]. A prospective short series study was organized to evaluate the utility of the Lehoczy’s island flap [32] method in reconstructing the mesh-related bladder perforation and VVF. We assumed that the Lehoczy’s island flap method is highly effective in reconstructing prosthesis-formed fistulas.

Mesh extrusions, dyspareunia or vaginal discharges are more frequent issues after vaginal prosthesis operations. Reviewing the literature, we have provided good evidence that the folding and contraction of the implanted meshes may cause pain, dyspareunia and the extrusion of the implants [33,34]. For this purpose, a new concept involving an anchorless implant was developed. We have hypothesised that our new anchoring technique and non-folding meshes result in better long-term results than other vaginal prosthesis methods.

The anti-SUI efficacy of the prosthetic placement is barely 72–83% [35-37]. Our previous study, where the anterior arms of the TVM were anchored by two stitches, resulted in greater anti-SUI efficacy (90%). We hypothesise that the original TVM operation may be followed by residual SUI since the strengthening of the back arms may result in a backward dislocation of the entire mesh.

4. MATERIALS AND METHODS

All of our studies were carried out between 2011 and 2016 in accordance with the Code of Ethics of the Declaration of Helsinki for scientific research involving humans. They were approved by the institutional research ethics committee under the following protocol numbers (Prot. No. 194/2010; Prot. No. 55/2016). Study 3 was registered at the Medical Research Council of the Ministry of Human Capacities under No. CD-1410005 rev.00. The protocol for Study 4 was also registered at the ClinicalTrials.gov site under registration number NCT02935803. Informed consent was signed by the person under observation after being provided a detailed and clear explanation of the conditions and aims of the study.

4.1. The experimental protocol in Study 1

In Study 1 we evaluated and compared the anti-POP effect, anti-stress incontinence (anti-SUI) efficacy, and the early (six weeks) and late (36 months) postoperative complication rates for the anterior vaginoplasty and the transvaginal mesh (TVM) operations.

4.1.1. Material and methods

The retrospective cohort study comprised 120 women who presented for the correction of SUI in conjunction with symptomatic anterior compartment POP–Q 2–3 at the Departments of Urology and Obstetrics and Gynaecology at the University of Szeged, Hungary, between January 2013 and January 2014. Sixty patients had undergone Kelly–Stoeckel vaginoplasty and the other 60 cases had had TVM surgery. Both study groups were homogenized as much as possible according to age, parity, body mass index (BMI) and menopausal status. The symptomatic POP–Q Stage 2–3 anterior prolapse is defined as the maximum extent of the prolapsed anterior vaginal

wall being within 1 cm above and 6 cm below the hymen [20,38]. Coexisting symptomatic SUI was determined with pad or cough tests.

4.1.2. Exclusion criteria

The exclusion criteria were as follows: a history of mesh use or anti-incontinence pelvic procedures, antidepressant therapy, pregnancy and cancer of the pelvic organs.

4.1.3. Efficacy criteria

The efficacy of the POP repair was taken as a significant (>1 cm) improvement at points Aa, Ba and C and total vaginal length (TVL) according to the POP-Q system (International Continence Society) during the follow-up [20,38]. Anti-incontinence efficacy was classified as no further SUI diagnosed by cough or pad test.

Early surgical complications were classified using the Clavien–Dindo (CD) classification system [39] (Table 1).

Grade I	Any deviation from the normal postoperative course without the need for pharmacological treatment or surgical, endoscopic, and radiological interventions. Allowed therapeutic regimens are: drugs such as antiemetics, antipyretics, analgetics, diuretics, electrolytes, and physiotherapy. This grade also includes wound infections opened at the bedside.
Grade II	Requiring pharmacological treatment with drugs other than allowed for grade I complications. Blood transfusions and total parenteral nutrition are also included.
Grade IIIa	Surgical, endoscopic, or radiological intervention that is not under general anesthesia
Grade IIIb	Surgical, endoscopic, or radiological intervention that is under general anesthesia
Grade IVa	Life-threatening complication requiring intermediate care or intensive care unit management, single organ dysfunction (including dialysis, brain hemorrhage, ischemic stroke, and subarachnoidal bleeding)
Grade IVb	Life-threatening complication requiring intermediate care or intensive care unit management, multi-organ dysfunction (including dialysis)
Grade V	Death of a patient
Suffix “d”	If the patient suffers from a complication at the time of discharge, the suffix “d” (for “disability”) is added to the respective grade of complication. This label indicates the need for a follow-up to fully evaluate the complication

Table 1. Clavien–Dindo classification for surgical complications

4.1.4. Diagnosing DNUS

A diagnosis of DNUS was determined if detrusor pressure changes were observed in cystometrographic pressures after the surgeries. The postoperative complications that led to reoperation were infection, recurrent descent or incontinence, implant extrusion, chronic pelvic pain and total retention. Prosthetic extrusion was diagnosed by the presence of exposed graft material in the vagina. Post-void residual is a measurement of the urine that remains in the bladder less than 20 minutes following voiding; it represents urinary retention.

4.1.5. Side-effects under examination

As concerns the long-term postoperative complications of the sling and mesh procedures, we determined the erosion rate, the presence of DNUS or urinary tract infection (UTI) and the need for reoperation.

4.1.6. The operative method used

All prosthesis operations were carried out with 100% polypropylene monofilament permanent meshes produced by Aspide® SURGIMESH® PROLAPSE (Aspide Médical, La Talaudière, France). The implanted vaginal prosthesis has pores which are 1.6 x 1.7 mm in size and is approved for anterior vaginal repair. Surgery was performed under general anaesthesia with the patient in the lithotomy position and with an indwelling urinary catheter. The anterior vaginal wall was incised longitudinally throughout its thickness from the cervix to 1 cm below the urethral meatus, under the mid-urethra. The thickness of the dissection, the location of the vaginal incision, the placement of the mesh and the closure of the incision varied only minimally, and the length of the incision only varied between 6 and 7 cm. Before insertion, all sterile meshes were soaked in iodine fluid (Betadine®). The Surgimesh® device was introduced beneath the dissection. Its four arms were then passed through the obturator membrane. The posterior part of the mesh was anchored to the anterior side of the cervix using two Prolene® 2-0 sutures (Ethicon, Issy-les-Moulineaux, France). The mesh was then adjusted in a tension-free manner beneath the distal part of the urethra and bladder, and the anterior vaginal wall was closed using Monocryl® 3-0 absorbable sutures (Ethicon, Issy-les-Moulineaux, France), with a slight colpectomy. Prophylactic preoperative antibiotics (cefazolin 1g, amoxicillin and clavulanic acid 1.2g or gentamycin 160mg)

were administered intravenously. A urinary catheter was removed on the morning of the postoperative day.

Traditional anterior colporrhaphy was augmented with Kelly's-Stoeckel plication in order to thicken the cervicopubic fascia which promotes the appropriate elevation of the bladder neck and closure of the urethra, enhancing the anti-incontinence effect.

Both types of operations were performed by the same two experienced senior surgeons (F.Z. and R.L.), and there were no differences in the operative processes.

In all cases, a vaginal gauze pack (gauze soaked in Betadine iodine) was placed for 12h. The post-voided residual urine was measured by ultrasonography before each patient was discharged. All the patients participated in topical intravaginal oestrogen cream treatment for at least twelve months following the operation (Ovestin® 1mg/gram daily), but none of the patients took part in preoperative oral hormone replacement therapy. The follow-up period after the TVM and Kelly–Stoeckel vaginoplasty operations were 36 months.

4.1.7. Statistical analyses

The SPSS 17.0 program package was used to analyse the data. The non-parametric design of the continuous variables was verified with the Shapiro–Wilk test. Categorical and continuous variables were compared with the χ^2 test and Kruskal–Wallis test, respectively. Univariate logistic regression was employed to determine the odds for continuous variables. Multiple logistic regression was used to adjust the comparisons of the groups in terms of age, previous parity, postmenopausal stage, previous vaginal operations, chronic systemic diseases, POP–Q stage and urge symptoms due to inequalities between cases and controls. A two-tailed p-value of <0.05 was judged as significant. The power of the statistical tests ranged between 74% and 99% in the study.

4.2. The experimental protocol in Study 2

A prospective short series study was organized to evaluate the utility of the Lehoczky's island flap method for reconstructing the mesh-related bladder perforation.

4.2.1. Material and methods

Women (mean age 62, n=3) with clear stress urinary incontinence underwent a TOT procedure using monofilament polypropylene tapes (Surgimesh sling 45x1cm VS112-KY, Aspide Médical, La Talaudière, France) at different hospitals. The transobturator approach was performed as described by Delorme [15] using a helical needle tunnelling from the outside entrance point to adjust the tape from the vagina to the skin without any tension. The clinical data on the primary operation was taken retrospectively from the medical charts. From four to seven months after the initial sling operations, all the patients reported urine leakage with improvement. Transabdominal ultrasonography, cystoscopy and bimanual examinations as preoperative tests were performed in all cases. The preoperative examinations showed normal bladder structures through ultrasonography, and the cystoscopies revealed serious inflammations in the bladders and fistulas where 2–3 cm-long parts of the polypropylene tapes were visible, which eroded the trigonal mucosa close to the ureteral orifices.

4.2.2. Efficacy criteria

The method was effective if the patients involved at the three-month final follow-up self-reported no urine leakage and if all of them were free of fistulas, without any complaint of dyspareunia.

4.2.3. The operative method used

After premedication with IV antibiotics (2x750 mg cefuroxim/day) and SC low molecular weight heparin (1x0.2 ml enoxaparin sodium/day), the patients underwent surgical VVF repairs. The surgical method was very similar in all cases. The patients were positioned in lithotomy positions. The vagina was exposed with a deep episiotomy, and the vaginal part of the fistula and the wide inflamed area were then excised, with the sling completely excised from the vaginal and bladder wall. Six French ureteral catheters were introduced into the ureter, which was located close to the edge of the fistula to protect the catheters during the operation. The opening of the fistula in the bladder was closed with absorbable interrupted sutures. The bladder wall was closed, and a drain was fixed. The vaginal wall defects were covered with Lehoczky's skin flaps. The oval-shaped fatty-skin flaps were dissected from the area of the *genitofemoral* sulcus in all

cases with a diameter of 3–4 cm on the same side as the fistula was located. The skin and the underlying voluminous adipose tissue were mobilized down to the fascia of the muscles with an intact blood and nerve supply. The island flap was pulled into the vagina through a tunnel under the *bulbocavernous* muscle (Figure 6). The fatty part of the flap was situated between the vagina and the bladder wall (Figure 7) and protected against retraction in the *paracolpium* with deep sutures, while the skin covered the vaginal defect as a patch and its edges were sutured to the wall of the vagina. The donor site of the flap was closed with interrupted sutures (Figure 8). A urethral catheter was fixed for ten days. The final follow-up was three months, when a cystoscopy and a bimanual examination were performed.

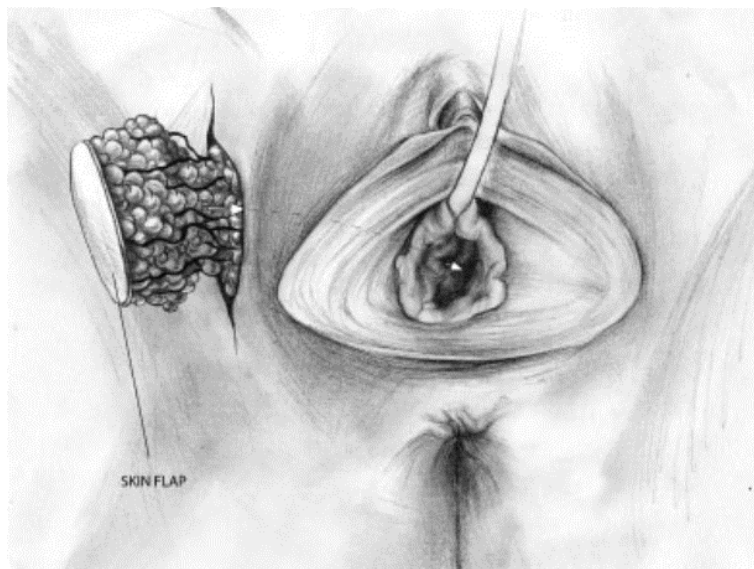


Figure 6. Lehoczky's flap formation. The island flap of the skin and the underlying adipose tissue were widely mobilized.

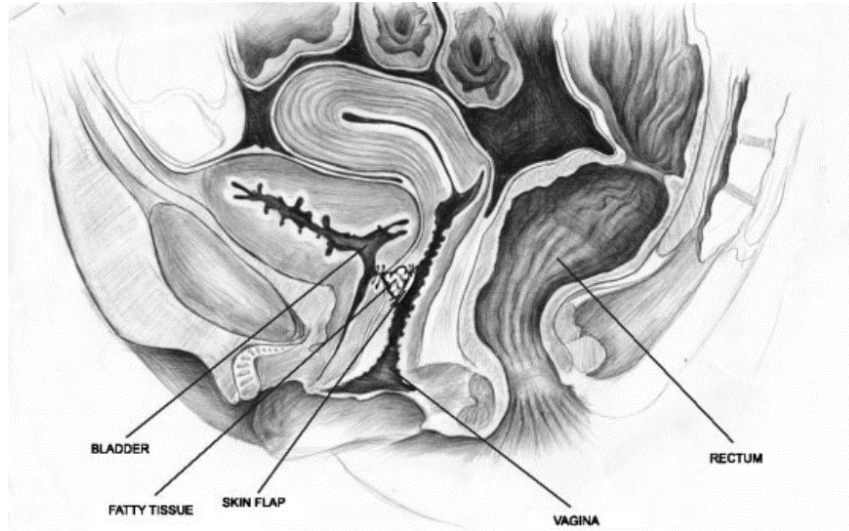


Figure 7. The fatty part of the flap was interposed between the vagina and the bladder.

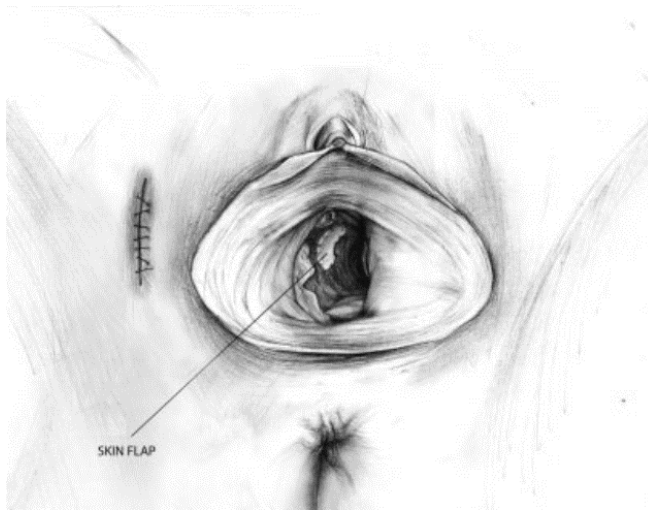


Figure 8. The donor site of the flap was closed with interrupted sutures.

4.3. The experimental protocol in Study 3

The available international literature provides good evidence that the anchoring techniques used in the placement of vaginal implants are a major factor in the occurrence of complications: organ perforation involved in the anchoring technique, unbalanced scar formation at the anchoring points, tension, folding and contraction that can cause pain and/or dyspareunia [33, 34]. For this purpose, a new concept involving an anchorless implant was developed. The assumption was that an anchorless neo-pubocervical fascia would accurately mimic the physiological support system, therefore providing adequate support.

4.3.1. Materials and methods

A prospective, multi-centre, international study was organized to evaluate the feasibility, safety and cure rate for POP surgery using the so called “Self Retaining Support System (SRS) implant. The patients involved (n=20) with at least POP–Q Stage 2 anterior compartment prolapse were recruited from the gynaecological clinics in each participating hospital (Ma’ayanei HaYeshua Hospital, Bnei Brak, Israel; Catholic University Gemelli Hospital, Rome, Italy; University of Szeged, Szeged, Hungary). All participants provided informed consent, translated into the local language, after a detailed explanation of the risks involved in vaginal implants was provided.

Demographic and background morbidity data, pre-surgical POP–Q scoring and QoL questionnaires (validated PFDI and PISQ-12) were collected.

4.3.2. Exclusion criteria

Exclusion criteria included: previous POP repair with mesh, age > 75 years, old POP–Q less than Stage 2 or asymptomatic POP.

4.3.3. Efficacy criteria

Objective anatomical success was defined as POP–Q Stage 0 and 1 prolapse using the NIH criteria [40]. The Pelvic floor disability index (PFDI-20) is divided into three domains: Pelvic Organ Prolapse Distress Inventory 6 (POPDI-6), Colorectal Anal Distress (CRAD-8) and Urinary Distress Inventory (UDI-8). Patients were followed at two weeks and two, six, twelve and 24 months after surgery. Objective and subjective primary end points were defined at 24 months.

4.3.4. The recently invented device

The device is composed of an ultra-light titanized polypropylene mesh (16 g/m²) stretched and held in place by a U-shaped flexible frame made of a biocompatible implantable polymer (Figure 9). The SRS lateral arms have been designed to mimic the shape of the ATRP. The arms are connected ventrally by a bridge designed to allow the passage of the urethra. The frame is composed of a solid but flexible material. The frame functions as a mesh-retaining system by holding the mesh stretched under preload tension. Such tension prevents the mesh from bunching

or contracting during the healing process. The shape of the device, which accurately imitates the anterior vaginal wall hammock, prevents it from moving, and therefore no anchoring or fixation is required.

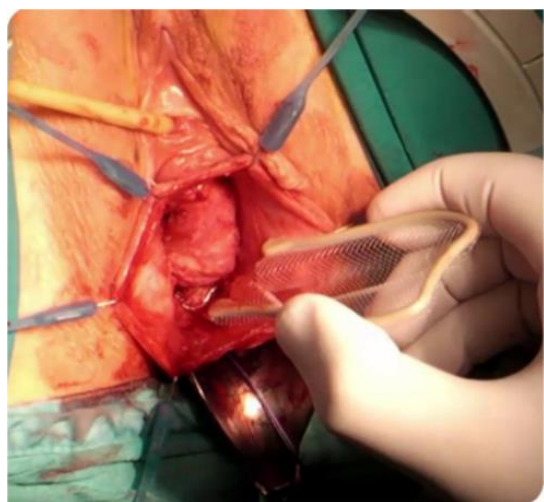
Figure 9. The self-retaining support (SRS) implant



4.3.5. The surgical technique

The surgical technique involves performing an incision on the anterior vaginal wall and a central dissection of the bladder from the vagina (Figure 10). Dissection is then extended to the para-vesical space for direct bilateral palpation of the ischial spines. The implant is

positioned in place with no tension, with the arms not flexed and the mesh fully stretched. The device is inserted between the bladder and the vaginal mucosa with the lateral arms following the anatomy of the ATFP. The connecting bridge is positioned under the pubic symphysis.



Appropriate location is confirmed by visualization of a symmetrically positioned device and a fully stretched mesh under the bladder. In the case of uterine preservation, the cervix is sutured to the proximal edge of the mesh. No other anchoring techniques are used. The vaginal incision is closed with no tension, and vaginal packing is used for 24 hours.

Figure 10. Implanting the SRS device

4.3.6. Statistical analysis

Statistical analysis involved the Analysis of Variance (ANOVA) test, where the null hypothesis is that all subgroup means are equal. The results from the two-way ANOVA on changes in points Aa, Ba and C by subject and visit were analysed, looking at the p-values of the term visit in the model to evaluate statistical significance. Pre- and post-surgery POP-Q measurements were calculated using a non-parametric Wilcoxon signed ranks test.

4.4. The experimental protocol in Study 4

Although the rate for concomitant SUI in patients with POP is as high as 63–80% [2], the effective treatment for coexisting SUI and POP is still debated. The anti-SUI efficacy of the prosthetic placement is barely 72–83% [34-36]; however, it is assumed that a combination of a synthetic mesh with the sling operation [26,27,41] will substantially increase the cure rate for concomitant SUI.

Therefore, the research group developed a modification to the transobturator four-arm TVM to increase its anti-incontinence effect. In the original TVM, the posterior part of the mesh is anchored to the anterior aspect of the cervix and the anterior arms are spread under the bladder neck with stabilizing sutures. We hypothesise that the original TVM operation can be followed by residual SUI since the strengthening of the back arms may result in a backward dislocation of the entire mesh. The posterior movement of the mesh allows the dorsal rotation of the urethra since the mid-urethra is not suspended. The proposed modification to the original surgical procedure includes the suture of the anterior part of the mesh to the mid-urethra to prevent the mesh sliding. We think that the appropriate elevation of the mid-urethra would thus occur with the anterior arms and that would achieve a more effective anti-incontinence. The pubourethral ligament is usually loose in SUI, but the anchored mesh would theoretically normalize its function and stabilize the urethra.

4.4.1. Material and methods

We designed a single-centre, prospective, double-blind (participant, investigator/surgeon, outcome assessor), randomized, controlled trial to evaluate the anti-SUI success rate for the modified TVM. The study is being conducted in accordance with the Declaration of Helsinki and has been approved by the local medical ethics committee at the University of Szeged under reference number 55/2016.

Patients will be recruited from the urogynaecology consultation at the Division of Urogynaecology, Department of Obstetrics and Gynaecology, University of Szeged, Hungary. All study participants will be provided an information sheet and a consent form describing the study in brief, so they can decide whether or not to participate in the study. This longitudinal study involving patients all successively scheduled for surgery for symptomatic prolapse POP–Q Grade 2 or 3 and coexisting SUI. The study will be conducted for an estimated maximum of 18 months.

The symptomatic POP–Q Stage 2–3 (determined by the gynaecological examination using the International Continence Society quantification system) [18] anterior vaginal wall prolapse is defined as the maximum extent of the prolapsed anterior and middle compartments being within 1 cm above and 6 cm below the hymen [20,38]. According to the international POP guidelines (the EBU and NICE guidelines) [42,43], if the condition disrupts the patient's life and nonsurgical treatment options have not helped, it should be treated surgically.

In all cases, SUI will be visualized after a complete physical examination is performed (confirmed by pad test/Bonney test/two dimensional (2-D) introital sonography and urodynamic examination). The severity of SUI is assessed using the Ingelman–Sundberg classification [44]. Urodynamic examinations comprising uroflowmetry, cystometrography, the pressure-flow study and the abdominal leak point pressure test will be performed before surgery to objectively determine the coexisting symptomatic SUI based on the international guidelines (the EBU and NICE guidelines) [42,43]. The abdominal leak point pressure test will be used as a standardized examination method for the evaluation of SUI with urine leakage as a sign. If the intraabdominal pressure recorded at the point of urine leakage is less than 40 cmH₂O, the origin of the SUI is set as intrinsic sphincter deficiency (ISD) [45]. In the case of ISD, preoperative pelvic floor training (PMFT) will be recommended. If the patient is unwilling to participate in PFMT or if the training is unsuccessful, we will recommend mesh surgery. This will also be the case for suspected

urethral hypermobility – i.e. if the intraabdominal pressure at the point of urine leakage is higher than 60 cmH₂O [45].

4.4.2. Introital ultrasound findings

In all cases, introital ultrasound (GE Voluson 730) will be performed with a standardized bladder-filling volume of 300 mL. The vaginal probe (5–9 MHz) will be placed in the area of the vaginal introitus at the level of the external urethral orifice, with the patient in a semi-sitting position. Ultrasound assessment of the bladder and urethra starts in the midsagittal plane.

During sonography, we measure the longitudinal (L) distance between the bladder neck and the line through the lower edge of the pubic symphysis and the horizontal (H) distance between the bladder neck and the upper edge of the symphysis. The two distances are measured at rest (L1, H1), during contraction (L2, H2), on pressing or while coughing (L3, H3). Changes in these parameters during contraction of the levator muscle and on pressing serve to evaluate the reactivity of the pelvic floor muscles and the adequacy of the supportive structures of the urogenital organs [26]. The funnelling of the proximal urethra during coughing as a typical stress urinary sign will also be examined [46].

4.4.3. Inclusion criteria

Female adults aged over 40 with coexisting pelvic floor defects will be recruited, at least one year following delivery, irrespective of parity and pre- or postmenopausal state, medically and physically fit for the measurement and therapeutic surgeries, and, in the case of systemic or local oestrogen treatment, stable for the past three months prior to inclusion. The patients will be randomized to one of the study groups using a computer-generated list.

4.4.4. Exclusion criteria

Exclusion criteria are urge; mixed incontinence; prolapse < Grade 2 or > Grade 3 POP–Q; apical or posterior compartment prolapse; dysuria (bladder tumour and/or neurogenic urinary bladder damage); a history of mesh use or anti-incontinence pelvic procedures; pregnancy (urine test); lactation period not yet finished; current urinary tract or vaginal infection; menstruation on the day of examination; contraindications for measurements or interventions, for example, acute inflammatory or infectious disease, tumour or fracture; *de novo* systemic or local oestrogen treatment (<3 months); *de novo* drug treatment with anticholinergics or other active substances

for bladder-related disorders (tricyclic antidepressants and selective serotonin reuptake inhibitors); and cancer of the pelvic organs.

4.4.5. Operative method

All operations will be carried out using 100% polypropylene monofilament meshes produced by Aspide® SURGIMESH® PROLAPSE (Aspide Médical, La Talaudière, France). The implanted vaginal prosthesis has pores which are 1.6 x 1.7 mm in size and is approved for anterior vaginal repair. Surgery will be performed under general anaesthesia with the patient in the lithotomy position and with an indwelling 16Ch urinary catheter. The anterior vaginal wall will be incised longitudinally throughout its thickness from the 1.5 cm below the urethral meatus (where the mid-urethra is located) to the cervix. The thickness of the dissection, the location of the vaginal incision, the placement of the mesh and the closure of the incision will vary only minimally, and the length of the incision is intended to be 6–7 cm. All the operations will be performed by two experienced senior surgeons who are subspecialists in urogynaecology. The posterior part of the mesh will be anchored to the anterior side of the cervix using two Prolene® 2-0 sutures (Ethicon, Issy-les-Moulineaux, France).

The mesh will then be spread by securing its anterior parts beneath the mid-urethra using two Vicryl 2-0® absorbable sutures (Ethicon, Issy-les-Moulineaux, France) (Figure 11).

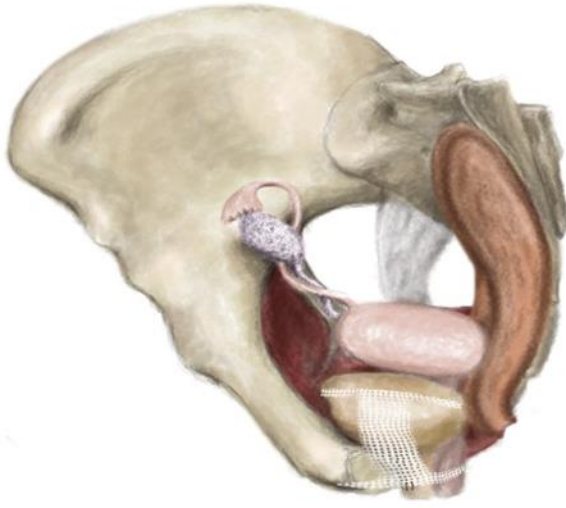


Figure 11. Anchoring stitches stabilize the mesh position under the mid-urethra

We hypothesise that this manoeuvre will promote the proper elevation and closure of the urethra. The mesh will then be adjusted in a tension-free manner beneath the distal part of the urethra and bladder. Lastly, the anterior vaginal will be closed using Monocryl® 3-0 absorbable sutures (Ethicon, Issy-les-

Moulineaux, France), with a slight colectomy. Prophylactic preoperative antibiotics (cefazolin 1g, amoxicillin and clavulanic acid 1.2g or gentamycin 160mg) will be administered intravenously. A urinary catheter will be removed on the morning of the postoperative day. A vaginal gauze pack (gauze soaked in Betadine iodine) will be placed for 12h.

4.4.6. Efficacy criteria

The follow-up period of the study will be 36 months. The primary outcome measures will be a significant improvement in POP repair and objective cure of SUI following surgery. The efficacy of POP repair will be understood as a significant (>3 cm) improvement during follow-up at points Aa, Ba, C and D using the POP-Q system (International Continence Society) [20,38]. Anti-incontinence efficacy is classified as no further SUI, as diagnosed by cough tests and urodynamic examinations. The secondary measurement outcome will comprise the intraoperative findings and postoperative factors. As concerns the long-term postoperative complications of the mesh procedures, we will determine the extrusion rate, the presence of DNUS or UTI, and the need for reoperation.

The subjective cure for prolapse and incontinence will be measured with a significant enhancement of the Pelvic Organ Prolapse/Urinary Incontinence Sexual Questionnaire (PISQ-12) and PFDI-20 scores. The PISQ-12 and PFDI-20 have been validated to assess the impact of SUI symptoms on quality of life and sexuality and relate well to the prolapse symptoms.

4.4.7. Data collection

Baseline (before the intervention phase) and follow-up measurements (of primary, secondary and tertiary outcomes) after six weeks to three years will be performed at the Division of Urogynaecology, Department of Obstetrics and Gynaecology, University of Szeged, Hungary, by experienced gynecologist in urogynaecology, who will be blinded to group allocation of participants and who will not operate on the patients (Table 1).

Table 1. Schedule of assessments/data collection

Assessment	Recruitment before intervention phase	Intervention (Surgery)	Follow-up				
			six- week	six- month	one- year	two- year	three- year
Assessment of eligibility criteria	x						
Written informed consent	x						
Gynaecological examination: incontinence symptoms	x	x	x	x	x	x	x
Gynaecological examination: prolapse	x	x	x	x	x	x	X
Urodynamic examination	x				x		X
Adverse events		x	x	x	x	x	X
Questionnaires: PISQ-12 and PFDI	x		x	x	x	x	X
Introital sonography	x				x		X

Urine culture	x			x	x	x	X
---------------	---	--	--	---	---	---	---

4.4.8. Sample size calculation

As we have newly developed the modification to the prosthesis surgery, an exploratory pilot study was designed to evaluate the feasibility of the modification to the mesh for the treatment of SUI. Twenty patients with SUI and POP have been recruited for an mTVM operation by the same two senior surgeons (F.Z. and R.L.), who are conducting this randomization study. The sample size calculation study was designed based on preliminary data on the twenty patients. The newly developed technique yielded an objective SUI cure rate of 92% as opposed to 72% for the original TVM published by Sergent et al. [23,36]. Sample size calculations were performed with G*Power software [47], using the statistical model for an χ^2 approach. Consequently, sample size was estimated theoretically and an effect size of $= 0.1$, indicating a small effect, will be accepted. The sample size was calculated for the primary outcome of the SUI cure rate with the following assumptions: $\alpha = 0.05$, power ($1-\beta$ error probability) $= 0.8$, number of groups $= 2$. Based on these assumptions, a total sample size of $n=130$ was estimated. In anticipation of dropouts (10%: $n = 16$) or a violation of protocol (10%: $n=16$), a final sample size of $n=162$ (81 participants per group) will result.

4.4.9. Statistical analyses

Analysis of the patients will follow the CONSORT flow diagram (Figure 12) through the phases of the study (enrolment (assessed, excluded, randomized), allocation (control group and experimental group with intervention received or not received), follow-up (lost to follow-up, discontinued intervention) and analysis [48].

All statistical analyses will be conducted using SPSS software version 22 (IBM, Armonk, NY, USA). All tests will be two-sided, and significance will be set at $p<0.05$. Efficacy measurements will be adjusted by intention-to-treat analysis. Missing values will be replaced using the last observation carried forward (LOCF) method. No subgroup analyses are planned. Standard deviations, 95% confidence intervals and median will be used for the descriptive analyses. With regard to the primary and secondary outcome analysis, the Chi-square test or Fisher's exact test will be employed to identify any objective outcome differences among groups.

Generally, continuous data will be checked for normality using the Shapiro–Wilk test. If the normality assumption is violated, then PISQ-12 and PFDI scores as tertiary outcomes will be normalized by log transformation ($\log_{10}(x)$). Univariate-repeated measure analysis of variance (ANOVA) will be used to determine the secondary outcome between and within the two groups (mTVM, TVM group) at six endpoints (before intervention and during follow-up clinical appointments 1–5 following intervention). A mixed design ANOVA will be carried out to determine the effects of the modified operation on subjective cure rate for POP and SUI, and the Bonferroni post hoc test will be used to test the difference between means. All statistical analyses will be completed after the final measurement of the last patient during the last clinical appointment after intervention. The repeated measure design with seven points in time allows us to monitor how patients change over time in both short-term (before/during intervention) and long-term situations (before/after intervention).

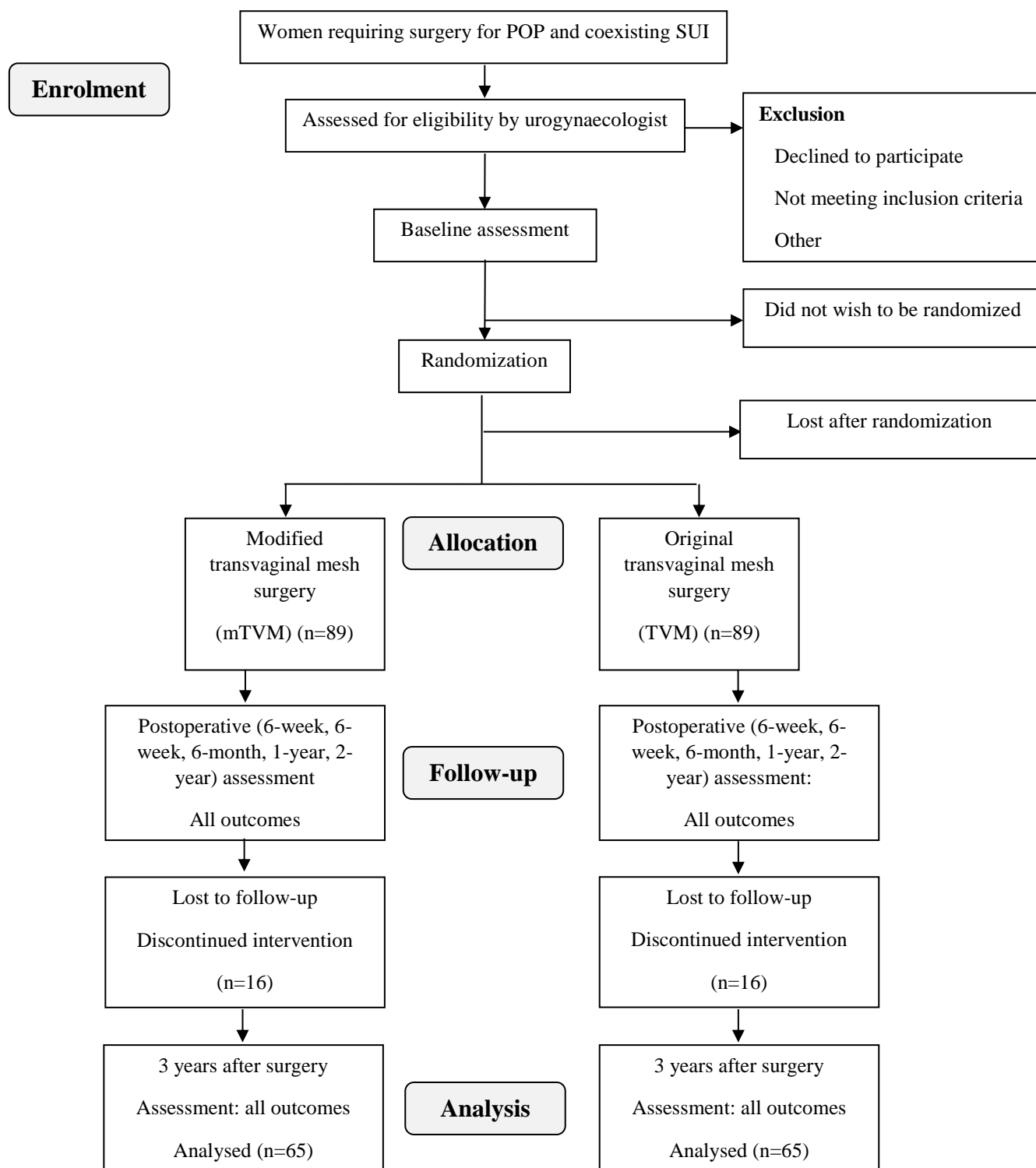


Figure 12. CONSORT study flow diagram

5. RESULTS

5.1. Comparison of the effectiveness of vaginal prosthesis and colporrhaphy operations

We have organized a retrospective study, with the best matched baseline characteristics possible for the evaluation of the effectiveness and feasibility of the mesh operations (Table 2).

	TVM (n=60)	p-value	Colporrhaphy (n=60)
Age (mean±SD)	59.83±9.95	0.47	59.95±9.53
Parity (mean±SD)	2.08±0 .61	0.44	2.1±0 .70
BMI (kg/m ²) (mean±SD)	28.46±2.97	0.17	27.9±3.4
Postmenopausal status n(%)	45(75.00)	0.08	52(86.67)

Table 2. Baseline characteristics of the TVM and colporrhaphy study groups (TVM: transvaginal mesh operation; BMI: body mass index).

The main results of our study were the following. The TVM significantly improved the prolapse status (POP–Q of Aa (p<0.001), Ba (p<0.001) and C (p<0.001)) compared to that of anterior colporrhaphy, while the total vaginal length was significantly shortened (p<0.001) (Table 3).

	TVM (n=60)			p-value	Colporrhaphy (n=60)		
	Preoperative	Postoperative 36 months	Mean change		Preoperative	Postoperative 36 months	Mean change
Aa (mean±SD)	-0.98±0.59	-1.37±0.55	-0.42±0.6	<0.001	-1.03±0.18	-0.7±0.64	0.3±0.59
Ba (mean±SD)	0.4±0.64	-1.72±1.00	-2.08±0.99	<0.001	-0.46±0.72	-0.93±1.4	-0.5±1.11
C (mean±SD)	-6.56±1.09	-6.82±0.87	-0.25±0.77	<0.001	-6.66±0.63	-6.4±0.79	0.27±0.51
TVL (mean±SD)	8.26±0.68	7.9±0.63	-0.35±0.48	<0.001	7.88±0.32	7.88±0.32	0±0

Table 3. Postoperative alterations in the POP-Q system after 36 months (TVM: transvaginal mesh operation; Aa: anterior compartment; Ba: middle compartment; C: apical compartment; TVL: total vaginal length).

The recurrence of anterior compartment POP (36.5%, $p<0.001$) and SUI (45%, $p<0.001$) or reoperation due to recurrence of SUI (8.3%, $p=0.007$) and POP (26.7%, $p<0.001$) during the 36-month follow-up period was typical of the anterior *colporrhaphy* patients. Prolapse repair was achieved in a significantly higher proportion of the patients who underwent TVM compared to their anterior *colporrhaphy* counterparts (91.7% vs 63.3%, $p<0.001$). Urinary tract infection was

not more prevalent after the prosthesis operations than after anterior colporrhaphy. DNUS was found significantly more often in the prosthesis than in the *colporrhaphy* group ($p=0.006$). The extrusion rate was 8.33% in the TVM group (Table 4).

The overall reoperation rate was remarkably lower in the TVM group than in the colporrhaphy group (16.7% vs. 35%).

	TVM (n=60)	p-value	Colporrhaphy (n=60)
Postoperative SUI n (%)	6(10)	<0.001	27(45)
Postoperative POP n (%)	5(8.33)	<0.001	22(36.67)
UTI n (%)	12(20)	0.590	12(20)
<i>de novo</i> urge incontinence n (%)	7(11.86)	0.006	0(0)
Mesh erosion	5(8.33)	n.m.	n.m.
All reoperations n (%)	10(16.67)	0.043	21(35.00)
Reoperation SUI n (%)	1(1.67)	0.103	5(8.33)
Reoperation POP n (%)	5(8.33)	0.007	16(26.67)
Reoperation erosion n (%)	5(8.33)	n.m.	n.m.

Table 4. Postoperative characteristics of the TVM and colporrhaphy study groups after 36 months (TVM: transvaginal mesh operation; SUI: stress urinary incontinence; POP: Pelvic organ prolapse; UTI: urinary tract infection).

Table 5 lists the operative characteristics and complications. The operation took longer in the TVM group as compared with the anterior *colporrhaphy* ($p=0.02$). The estimated blood loss (83.1ml vs 75.3ml) during the operation and the number of early reoperations were approximately the same in both groups ($p=0.71$, $p=0.31$ and $p=0.75$). The occurrence of bladder injury and the need for immediate postoperative blood transfusion were negligible in both the study groups (Table 5).

	TVM (n=60)	p-value	Colporrhaphy (n=60)
Duration of operation (min) (mean±SD)	39.01±5.95	0.002	35.55±6.92
Estimated blood loss (ml) (mean±SD)	83.08±71.72	0.71	75.33±26.0
Need for blood transfusion n (%)	0(0%)	n.m.	0(0%)
Intra-operative complications n (%)	0(0%)	n.m.	0(0%)
Postoperative residual urine above 100ml n (%)	5(8.33)	0.103	1(1.67)
Reoperation bleeding n (%)	3(5.0)	0.309	1(1.67)
Retention after reoperation (%)	1(1.67)	0.752	1(1.67)

Table 5. Operative characteristics and postoperative complications in the TVM and colporrhaphy study groups (TVM: transvaginal mesh operation).

Table 5 demonstrates the postoperative complications within six weeks according to the Clavien–Dindo classification. Total complication rates of 33.3% in the TVM group and 25% in the colporrhaphy group were noted with non-significant differences ($p=0.4$). CD 1 complications

predominantly occurred in the group of women operated on with prostheses, while anterior colporrhaphy operations were followed mostly by CD 2. In four cases vaginal bleeding was observed in the 6 weeks post operative period CD3b and reoperation was performed under analgesia (Table 6).

	TVM (n=60)	p-value	Colporrhaphy (n=60)
CD 0 n(%)	40(66.67)	0.405	45(75)
CD 1 n(%)	11(18.33)		6(10)
CD 2 n(%)	6(10)		8(13.33)
CD 3b n(%)	3(5)		1(1.67)

Table 6. Clavien–Dindo classification for postoperative surgical complications among patients who presented for TVM and colporrhaphy study groups (CD: Clavien–Dindo classification).

5.2. Effectiveness of Lehoczy's island flap method in reconstructing the mesh-related bladder perforation

Among the operated patients at the third week of follow-up, no vesicovaginal fistulas were found by cystoscopy, and bimanual examinations demonstrated that Lehoczy's island flap healed *per primam* in our short-term series involving Lehoczy's island flap.

At the three-month final follow-up, patients self-reported no urine leakage, and all of them were free of fistulas and *dyspareunia*.

5.3. Feasibility of the Self-Retaining Support Implant in the POP–Q Stage 2–4 reconstruction

Twenty women were recruited for the SRS study. Table 7 shows patient demographics. The mean age of the patients enrolled was 61.9 years, and the mean number for previous parity

was four. The participants were slightly overweight (BMI: 28.13), and the vast majority of them had no anamnestic hysterectomy or prolapse surgery.

Variable	Value (N=20)	SD
Mean age years (range)	61.95 (50–75)	6.58
Mean parity (range)	4.0 (1–16)	
Mean BMI (range) (kg/m ²)	28.13 (20.3–35.4)	4.28
Previous prolapse surgery	5 (26%)	
Previous hysterectomy surgery	3 (15%)	

Table 7. Baseline demographic and clinical data of SRS study (SRS: Self-retaining support implant; BMI: body mass index)

Preoperative mean POP–Q measurements were Aa=1.40 (-1 to 3) cm, Ba=2.3 (-1 to 6) cm and C=0.4 (-7 to 6) cm. Nineteen (95%) patients suffered from both an anterior and an apical compartment prolapse, while one (5%) patient only had an anterior prolapse.

Table 8 summarizes the anatomical outcome at the two-year follow-up. Seventeen (84.2%) patients had a Stage 0 prolapse, and three patients (15.8%) had a Stage 1 prolapse. At the 24-month follow-up, significant anatomical changes were found at points Aa (1.4 to -2.9cm), Ba (2.3 to -2.8cm) and C (0.4 to -7cm). No cases of mesh erosion or chronic pelvic pain were documented at follow-up (Table 8).

Variable	Preoperative	Postoperative 24 months	P based on *
POP-Q:	N (%)	N (%)	
Stage 0	0	17 (85%)	
Stage 1	0	3 (15%)	
Stage 2	7 (35%)	0	
Stage 3	5 (25%)	0	
Stage 4	8 (40%)	0	
Mean point Aa (cm)	cm \pm SD (range) 1.4 \pm 1.5 (-1 to 3)	cm \pm SD (range) -2.95 \pm 0.2 (-2 to -3)	0.000
Mean point Ba (cm)	2.3 \pm 2.6 (-1 to 6)	-2.8 \pm 0.3 (-2 to -3)	0.000
Mean point C (cm)	0.4 \pm 3.5 (-7 to 6)	-7 \pm 1.6 (-10 to -5)	0.000
Mean TVL (cm)	7.55 \pm 1.35 (5-11)	7.75 \pm 1.07 (6-10)	0.519
Mean Ap (cm)	-1.40 \pm 1.98 (-3 to 3)	-2.15 \pm 0.93 (-3 to 0)	0.18
Mean Bp (cm)	-1.2 \pm 2.89 (-3 to 6)	-2.0 \pm 1.026 (-3 to 0)	0.569

Values given as mean \pm SD (range) *Non-Parametric Wilcoxon Signed Ranks Test

Table 8. POP-Q measurements at baseline vs 24-month follow-up (POP-Q: Pelvic Organ Prolapse Quantification System. Aa: anterior compartment; Ba: middle compartment; C: apical compartment; TVL: total vaginal length; Ap: outer posterior compartment; Bp: inner posterior compartment.

Surgical time for the SRS implantation averaged 31.2 (21–50) min. Estimated total surgical blood loss averaged 205 (150–500) ml. Estimated blood loss for patients who underwent the implant-only procedure averaged 165 ml. No intra-operative complications were observed.

As for the subjective outcome, summarized in Table 9, PFDI-20 scores showed significant improvement of both prolapse and urinary domains as well as improvement in total scores. No deterioration was noted in the colorectal or the incontinence domains of the questionnaire.

Considering a standard MID of 15 points per domain and 45 points in total PFDI scores, results showed a significant improvement in the prolapse domain, incontinence domain and total PFDI-20 scores. Pelvic Organ Prolapse Distress Inventory 6 (POPDI-6) (POP domain) showed a decrease of 41.94 points ($p<0.0001$) at follow-up from baseline scores. The Colorectal-Anal Distress Inventory 8 (CRADI-8, posterior compartment domain) scores were 14.5 points ($p=0.0016$) lower at follow-up than baseline and demonstrated no deterioration at the posterior pelvic compartment. Urinary Distress Inventory 6 (UDI-6, urinary incontinence domain) showed a decrease of 36.3 points ($p=0.0167$). The total PFDI score was decreased by 92.75 points ($p=0.0001$).

Thirteen patients (65%) were sexually active during the study, and ten patients completed their PISQ-12 questionnaire. Out of these patients, five reported non-significant improvement, four experienced significant improvement, and one noted non-significant deterioration. Three patients that had been inactive became sexually active after surgery. None of these patients reported dyspareunia (Table 9).

Variable	N	Preoperative N=20 (SD)	24 months N=19 (SD)	Difference	p-value
Total PFDI	19*	129.8 (61.59)	37.05 (62.17)	92.75	P=0.0001
POPDI-6	20	53.12 (26.8)	11.18 (19.15)	41.94	P<0.0001
CRADI-8	20	27.83 (23.55)	13.32 (23.98)	14.51	P=0.0258
UDI-6	20	48.88 (25.42)	12.54 (21.42)	36.34	P=0.0167
PISQ-12	9	29 (NA)	34 (NA)	5	NA

One patient was lost to follow-up at 52 weeks.

Table 9. QoL (PFDI-20, PISQ-12) scores at baseline vs follow-up. (PFDI: Pelvic Floor Disability index, POPDI-6: Pelvic Organ Prolapse Distress Inventory 6, CRAD-8: Colorectal-Anal Distress Inventory 8, UDI-6: Urinary Distress Inventory 6, PISQ-12: Pelvic Organ Prolapse/Urinary Incontinence Sexual Questionnaire)

Postoperatively, one patient received one unit of packed cells and no events of urinary retention were recorded. One patient developed *de novo* stress urinary incontinence, which was treated successfully with pelvic floor muscle training. One case (5%) of frame erosion into the anterior vaginal wall was documented eight months following the procedure. The eroded part of the frame was resected under local anaesthesia in an ambulatory setting. The patient's symptoms were relieved immediately after the resection. This was the only case where a large frame was used, which we hypothesise to have caused excessive pressure on the vaginal mucosa, causing the erosion.

6. DISCUSSION

The US Food and Drug Administration (FDA) has received more than 1000 warnings from mesh manufacturers of complications associated with prosthesis use in the repair of SUI and POP since 2005 [5]. The potential complications of using transvaginal mesh are wide-ranging, from mild to seriously life-threatening. The most common complications, as reported in the FDA Public Health Notification, include mesh erosion at the site of vaginal incision, lower urinary tract infection, pelvic pain, dysuria, recurrence of prolapse or incontinence, *de novo* UUI, *de novo* SUI dyspareunia, and perforation of the bowel, bladder, and/or vessels during mesh insertion [5].

Many of these complications require additional intervention, including medical or surgical treatment and hospitalization.

The FDA warnings in 2008 and the update in 2011 concluded that transvaginal surgical repair to correct weakened tissue at the anterior compartment with mesh may provide an anatomical benefit compared to traditional POP repair without prosthesis and that this anatomical benefit may not result in better symptomatic results. They found no evidence that transvaginal repair to support the apical part of the vagina (apical repair) or the back wall of the vagina (posterior repair) with mesh provides any added benefit compared to traditional surgery without mesh. Similarly, they found no evidence that vaginal prosthesis operations have a remarkable anti-incontinence effect. The use of transvaginal mesh for POP repair has increased tremendously in the past few years. Only recently have systematic reviews and clinical practice guidelines been available to guide the physician.

The most striking result of our study is that the transvaginal implantation of the four-arm mesh is highly effective in the repair of an *anterior* prolapse (POP-Q 2–3) and in genuine stress urinary incontinence (SUI). Success rates of 90% and 91.7% were demonstrated for SUI and prolapse, respectively. The surgical procedure for prosthetic placement provided a radically better SUI reconstructive effect than that of the colporrhaphy group (55%) or than that reported in the literature (69–90.3%) [34–36]. With regard to POP repair, TVM (91.7%) proved significantly more effective than anterior colporrhaphy (63.3%), but only minimally more than that demonstrated in the literature (with a rate of 82.3–100%) [21,36,37,49–51].

According to current knowledge, the TVM supports the whole of the anterior and middle compartments but does not elevate the middle part of the *urethra* and, hence, theoretically allows for urethral dorsal rotation, which may lead to residual SUI, especially if the mesh is able to migrate a bit more posteriorly toward the cervix. It is also possible that mesh movements towards the bladder neck could be responsible for the higher rate for DNUS (11.8% in our study) with the traditional TVM method. Our findings confirm that using stabilizing sutures to fix the mesh to the paraurethral tissues at the level of the mid-*urethra*, where the *pubourethral* ligament originally held it, aids in elevating the middle region, this being considered the treatment of SUI that is at least as effective as the TVT-O technique in the literature (92%) [52], and also reduces the rate for DNUS. In the literature, original TVM only has a limited anti-SUI mechanism (83.3%) [37]. A prospective double-blind randomized study was designed to evaluate the anti-SUI and POP reconstructive effect of the original TVM and a newly introduced modified technique with sub-urethral stabilizing sutures. To the best of our knowledge, that ongoing study is the first to investigate a surgical modification to TVM for more effective anti-incontinence. Should this newly developed modification be proved successful in treating SUI, it could be introduced in clinical practice due to its simplicity.

We attribute our lower anatomical recurrence in the apical region (POP-Q point C) of TVM to a wider suspension area of the insertion of a smooth, non-folded mesh with the anchoring of the posterior arms of the mesh to the pericervical ring. The better anatomical results of the prosthesis operations compared to the non-mesh reconstructive methods in the anterior and middle compartments (POP-Q points Aa and Ba) have been documented in the literature [5,53]. The transobturator four-arm meshes are fixed to the ATFP, thus preventing the lateral recurrence of a cystocele. The better tensile strength of the polypropylene meshes compared to the original paravaginal fascia resulted in a better reconstructive effect in midline cystoceles.

However, the perioperative complication rate is diminished after non-mesh surgery (25%) compared to that after implant surgery (33.3%). This is supported by the literature data [49,53].

In a single TVM series using the Perigee technique, the average blood loss was found to be 180 ml [5], which was much higher than in our TVM data series (83 ml), and the mean procedure duration was also shorter in the TVM group (39 min vs. 60.9 min) [54]. In our retrospective study, we found no significant alterations between the prosthesis and natural tissue reconstructive

operations in length of operation and blood loss. We hypothesise that surgeons with greater experience with the relevant operative techniques can implant meshes with the same intra- and perioperative complication rates as those for the non-mesh methods. The extrusion rate for the TVM operation in our study (8.3%) was the same as in the literature (8%) [5]. The overall reoperation rate after TVM, including the erosion of the implanted mesh, was still less than that of the anterior colporrhaphy group. After the resection of the extruded part of the prosthesis, no residual pain or other severe complications were observed.

One of the most frequent long-term complications we observed with synthetic mesh materials in our series was DNUS (11.8%), which is an important indicator of the level of patient satisfaction. Postoperative urodynamic examinations showed detrusor muscle action in all the cases involving DNUS. We believe that one possible reason for this is the fact that the mesh slides backwards and presses the bladder neck, provoking the receptors located there.

In our retrospective study, no bladder perforation was observed. The bladder perforation rate is very low with the retropubic operative technique. Due to the very low bladder perforation rate [28,29], VVF formation is an extremely rare complication of TVT-O methods [55,56]. To our knowledge, there are only three reports in the literature dealing with vesicovaginal fistulas after transobturator sling or mesh operations [55-57]. Most small VVFs can be managed via a transvaginal route [55-57]. For VVFs larger than 2 cm in diameter with severely damaged surrounding tissues, successful repair requires more complex procedures, mainly autologous natural tissue substitution. Lehoczy's island flap may be a good option for fistula closure [32,58].

Fistula development is supposedly caused by the foreign body constantly being contaminated with urine and the consecutive chronic disruption of wound healing processes, local chronic inflammatory reactions and microcirculatory failure of the affected tissue layers. All authors agree with the principle that it is essential to remove the prosthesis completely before the fistula closure in conjunction with a wide extirpation of the scar tissue. The use of the traditional methods of surgical repair leads to considerable complications in the treatment of VVF if there is severe radiation damage to the surrounding tissues or if it is necessary to perform a wide resection of the fistula. Nevertheless, the use of Lehoczy's island flap may be a good option for the repair of large vaginal defects, based on the central principle of reconstructive surgery, which is to use healthy tissue for the repair in a tension-free manner. The main advantages of this technique are

that the affected tissues and the fistula can be radically resected and substituted with a well-vascularized skin flap.

Despite providing good anatomical results compared to traditional native tissue repair, the use of vaginal mesh for the treatment of pelvic organ prolapse has been accompanied by greater long-term complications, such as mesh erosion, mesh contraction and dyspareunia [33,34]. We hypothesised that mesh anchoring techniques are a major risk factor for complications. With current kits on the market, the prostheses are fixed to the ATRP with stitches, anchoring hooks or the simple perforation of the *endopelvic fascia*. A new concept involving an anchorless implant was developed for this purpose. A device was designed with a flexible U-shaped frame, which supports an ultra-light titanized polypropylene mesh.

Mesh erosion is probably the most common complication of surgery with mesh kits available on the market, with a reported incidence of 10.3% in a large meta-analysis [59]. We believe elimination of mesh folding and bunching may reduce exposure through the vaginal incision and may lead to a lower mesh erosion rate. Margulies et al. [34] identified mesh folding in nine out of 13 patients suffering from vaginal mesh exposure. Mesh folding has been suggested as an important contributing factor in mesh exposure, secondary to a local inflammatory reaction and interference with the healing process at the incision site.

Current mesh kits provide a stand-alone mesh that is fixed at four corners in the pelvis. Current securement techniques do not assure that the mesh is placed in a flat, non-folded, tension-free fashion. Even when anchoring the mesh to four corners in a flat, tension-free configuration, there is no guarantee that dynamic pressures and scar accumulation construction forces will not cause mesh contraction and folding over time. The SRS solid frame provides long-term reassurance against mesh contraction and bunching.

In comparison with reports on currently available vaginal mesh kits, the safety profile and clinical outcome of the SRS implant seem significantly better: no mesh erosion, a single, preventable case of frame erosion (5%), no pain complications and no negative impact on lower urinary tract symptoms.

7. LIMITATIONS OF THE METHODS USED

Our studies had some limitations. The main limitation of the study that evaluated the efficacy of the TVM method is its non-randomized manner. We have planned a prospective randomized ongoing study to eliminate the bias caused by the prospective non-randomized method.

The surgeons were more experienced with the operative techniques, a fact which may somehow bias the results. Moreover, it was not an aim of the study to determine the subjective curative rate for SUI or POP; however, the prospectively collected objective curative frequency was noted. Furthermore, different types of complications occur after anterior colporrhaphy compared to mesh operations (i.e. extrusion does not occur after colporrhaphy), and the total complication rate should be interpreted with caution.

As VVF fistulas are extremely rare complications of vaginal prosthesis operations, we have only managed to organize a series of three short cases that scrutinised the value of Lehoczy's island flap. Moreover, it is no longer possible for the patients involved to take part in a further study, as they have reached the desired normal anatomical and functional status.

8. CONCLUSION

1. We found that the TVM operation is a highly effective method for the reconstruction of POP (91.3%) and a significantly higher proportion of the patients who underwent TVM experienced remarkable improvement in the POP-Q system compared to anterior colporrhaphy. Surprisingly, an extremely high success rate for SUI reconstruction (90%) was observed among patients who underwent mesh surgery.
2. The overall reoperation rate, including the extrusion rate, was remarkably lower in the prosthesis group than in the colporrhaphy group (16.7% vs 35%).
3. An ongoing prospective randomized double-blind study was designed to better evaluate the anti-incontinence effect of the original TVM method. We believe that the modification of the original TVM method with two suburethral anchoring sutures will lead to further improvement in the anti-SUI effect of mesh operations, a fact which is also examined in our prospective study.
4. The rate for bladder perforation rate and consecutive vesicovaginal fistulas after mesh surgery is low, but the successful reconstruction of VVFs poses challenges for surgeons. The use of Lehoczy's island flap may be a good option for the repair of large vaginal defects caused by implants.
5. The most common serious complication of prosthesis operations is mesh extrusion at a rate of 10.3%. Current operative techniques do not assure that the mesh is placed in a flat, non-folded, tension-free fashion, thus potentially leading to the extrusion of the implant. The SRS solid frame precludes mesh contraction and bunching and seems to have significantly better postoperative results with no mesh erosion, dyspareunia or UTI.

9. REFERENCES

1. Olsen A, Smith V, Bergstrom J, Colling J, Clark A. Epidemiology of surgically managed pelvic organ prolapse and urinary incontinence. *Obstet Gynecol* 1997;89:501–6.
2. Molander U., Milsom I., Ekelund P., Mellström D. An epidemiological study of urinary incontinence and related urogenital symptoms in elderly women. *Maturitas*, (1990); 12: 51-60
3. Rudnicki M, Laurikainen E, Pogosean R, Kinne I, Jakobsson U, Telemann P. (2016) A 3-year follow-up after anterior colporrhaphy compared with collagen-coated transvaginal mesh for anterior vaginal wall prolapse: a randomised controlled trial. *BJOG*. 123(1):136-42.
4. Sohbati S, Salari Z, Eftekhari N. (2015) Comparison between the transobturator tape procedure and anterior colporrhaphy with the Kelly's plication in the treatment of stress urinary incontinence: a randomized clinical trial *Nephro Urol Mon*. 7(5): e32046.
5. Maher C, Feiner B, Baessler K, Christmann-Schmid C, Haya N, Marjoribanks J. Transvaginal mesh or grafts compared with native tissue repair for vaginal prolapse. *Cochrane Database of Systematic Reviews* 2016, Issue 2. Art. No.: CD012079. DOI: 10.1002/14651858.CD012079.
6. US Food and Drug Administration. UPDATE on Serious Complications Associated with Transvaginal Placement of Surgical Mesh for Pelvic Organ Prolapse: FDA Safety Communication. July 13, 2011
<https://www.fda.gov/medicaldevices/safety/alertsandnotices/ucm262435.htm>

7. Abrams P, Cardozo L, Fall M, et al. The standardisation of terminology of lower urinary tract function: report from the Standardisation Sub-committee of the International Continence Society. *Neurourology and Urodynamics* (2002); 21(2):167–178.
8. Hannestad YS, Rortveit G, Sandvik H, Hunskaar S. A community-based epidemiological survey of female urinary incontinence: the Norwegian EPINCONT *Journal of Clinical Epidemiology* (2000) ;53(11):1150–1157.
9. DeLancey JO. Anatomy of the female bladder and urethra. (1991) In Ostergrad Dr, Bent AE, eds. *Urogynecology and Urodynamics*, 3rd ed. Williams & Wilkins, Baltimore.
10. DeLancey JO. Structural support of the urethra as it relates to stress urinary incontinence: the hammock hypothesis. *Am J Obstet Gynecol* (1994); 170:1713
11. Bergman A, Elia G. Three surgical procedures for genuine stress incontinence: five-year follow-up of a prospective randomized study. *Am J Obstet Gynecol.* (1995); 173(1):66-71.
12. Aldridge AH. Transplantation of fascia relief of urinary stress incontinence. *Am. J. Obstet Gynecol* (1942); 44:398.
13. Richardson D. A. Preliminary report: Modification of the needle urethropexy in the management of stress incontinence. *Int Urogynecol J* (1991) 2: 123.
14. Ulmsten U, Petros P. Intravaginal slingplasty (IVS): An ambulatory surgical procedure for the treatment of female urinary incontinence. *Scand J Urol Nephrol* (1995); 29:75–82.
15. Delorme E, Droupy S, de Tayrac R, Delmas V. Transobturator tape (Uratape): a new minimally invasive procedure to treat female urinary incontinence. *Eur Urol* 2004;45:203–207
16. Boyles SH, Weber AM, Meyn L. Procedures for pelvic organ prolapse in the United States, 1979-1997 *Am. J of Obstetrics and Gynecology* (2003);188: 108–115.
17. DeLancey JO. Standing anatomy of the pelvic floor. *J Pelvic Surg.* (1996); 2:260.

18. Bump RC, Mattiasson A, Bø K, et al. The standardization of terminology of female pelvic organ prolapse and pelvic floor dysfunction. *Am J Obstet Gynecol.* 1996;175:10-7.
19. Baden WF, Walker T, Lindsay JH. The vaginal profile. *Tex med* 1968;64:56.
20. Persu C, Chapple CR, Cauni V, Gutue S, Geavlete P. Pelvic Organ Prolapse Quantification System (POP-Q) – a new era in pelvic prolapse staging. *J Med Life.* 2011;4(1):75–81
21. Letouzey V, Deffieux X, Gervaise A, Mercier G, Fernandez H, de Tayrac R. Trans-vaginal cystocele repair using a tension-free polypropylene mesh: more than 5 years of follow-up. *Eur J Obstet Gynecol Reprod Biol.* 2010;151(1):101–5.
22. Hiltunen R, Nieminen K, Takala T, Heiskanen E, Merikari M, Niemi K, Heinonen PK. Low-weight polypropylene mesh for anterior vaginal wall prolapse: a randomized controlled trial. *Obstet Gynecol.* 2007; 110(2):455–62.
23. Sergent F, Resch B, Diguët A, Verspyck E, Marpeau L. Vaginal prolapse and stress urinary incontinence: combined treatment by a single prosthesis. *Prog Urol.* 2006;16 (5):361–7.
24. Hannestad YS, Rortveit G, Sandvik H, Hunskaar S. A community-based epidemiological survey of female urinary incontinence: The Norwegian EPINCONT. *J Clin Epid.* 2000;53(11):1150–7.
25. Abbott S, Unger CA, Evans JM, Jallad K, Mishra K, Karram MM, Iglesia CB, Rardin CR, Barber MD. Evaluation and management of complications from synthetic mesh after pelvic reconstructive surgery: a multicenter study. *Am J Obstet Gynecol.* 2014;210 (2):163.e1–8.
26. Yonguc T, Bozkurt IH, Sen V, Aydogdu O, Yonguc GN, Gunlusoy B. Double-sling procedure for the surgical management of stress urinary incontinence with concomitant anterior vaginal wall prolapse. *Int Urol Nephrol.* 2015;47(10):1611–7.
27. van der Ploeg JM, Oude Rengerink K, van der Steen A, van Leeuwen JH, Stekelenburg J, Bongers MY, Weemhoff M, Mol BW, van der Vaart CH, Roovers JP. Transvaginal

- prolapse repair with or without the addition of a midurethral sling in women with genital prolapse and stress urinary incontinence: a randomised trial. *BJOG*. 2015;122(7):1022–30.
28. Minaglia S, Ozel B, Klutke C, Ballard C, Klutke J. Bladder injury during transobturator sling. *Urology* 2004; 64:376–7.
29. Smith PP, Appell RA. Transobturator tape, bladder perforation, and paravaginal defect: a case report. *Int Urogynecol J Pelvic Floor Dysfunct* 2007; 18:99–101.
30. Jasaits Y, Sergent F, Tanneau Y, Marpeau L. Vesicovaginal fistula after transobturator tape. *Prog Urol* 2007; 17:253–5.
31. Yamada BS, Govier FE, Stefanovic KB, Kobashi KC. Vesicovaginal fistula and mesh erosion after Perigee (transobturator polypropylene mesh anterior repair). *Urology* 2006; 68:1121.e5–1121.e7.
32. Lehoczy G. Neue Fisteloperation. *Wiss Z Humboldt-Univ Berl* 1963;12: 171–2.
33. Feiner B, Maher C. Vaginal mesh contraction: definition, clinical presentation, and management. *Obstet Gynecol*. 2010;115(2 Pt 1):325–30.
34. Margulies RU, Lewicky-Gaupp C, Fenner DE, McGuire EJ, Clemens JQ, Delancey JO. Complications requiring reoperation following vaginal mesh kit procedures for prolapse. *Am J Obstet Gynecol*. 2008;199(6): 678.e1–4.
35. Serati M, Sorice P, Bogani G, Braga A, Cantaluppi S, Uccella S, Caccia G, Salvatore S, Ghezzi F. TVT for the treatment of urodynamic stress incontinence: efficacy and adverse effects at 13-year follow-up. *Neurourol Urodyn*. 2015;36:192–7.
36. Nauth MA, Fünfgeld C. Correction of cystocele and stress incontinence with anterior trans obturator mesh. *Eur J Obstet Gynecol Reprod Biol*. 2007;136:249–53.

37. Sergent F, Sentilhes L, Resch B, Verspyck E, Medeiros R, Descamps P, Marpeau L. Treatment of concomitant prolapse and stress urinary incontinence via a transobturator subvesical mesh without independent suburethral tape. *Acta Obstet Gynecol Scand.* 2010;89:223–9.
38. Reid F. Assessment of pelvic organ prolapse: a practical guide to the pelvic organ prolapse quantification. *Obstet Gynaecol Reprod Med.* 2014;24(6):170–6.
39. Dindo D, Demartines N, Clavien PA. Classification of surgical complications: a new proposal with evaluation in a cohort of 6336 patients and results of a survey. *Ann Surg.* 2004;240(2):205–13.
40. Matthew D. Barber, MD, MHS, Linda Brubaker, MD, MS, Ingrid Nygaard, MD, Thomas L. Wheeler, II, MD, MSPH, Joseph Schaffer, MD, Zhen Chen, MS, and Cathie Spino, DSc, for the Pelvic Floor Disorders Network. Defining Success After Surgery for Pelvic Organ Prolapse *Obstet Gynecol.* 2009;114(3): 600–609.
41. Takahashi S, Obinata D, Sakuma T, Matsui T, Takenobu Y, Igarashi T, Yoshizawa T, Sato K, Mochida J, Sugimoto S. Transvaginal mesh (TVM) reconstruction with TVT/TOT sling for vaginal prolapse concurrent with stress urinary incontinence. *Aktuelle Urol.* 2010;41 Suppl 1:S20-3.
42. Urinary Incontinence EBU Guideline 2016 November.
<http://uroweb.org/guideline/urinary-incontinence/>
43. Urinary incontinence in women: management 2015 NICE guidelines [CG171]
<https://www.nice.org.uk/guidance/cg171>
44. Ingelman-Sundberg A. Urinary incontinence in women, excluding fistulas. *Acta Obstet Gynecol Scand.* 1952;31:266-91.

45. Majoros A, Hamvas A, Keszthelyi A, Romics I. Value of testing the abdominal leak point pressure in the differential diagnosis of urinary stress incontinence. *Orv. Hetilap* 2003;144:2321–5 [Article in Hungarian].
46. Tunn R, Petri E. Introital and transvaginal ultrasound as the main tool in the assessment of urogenital and pelvic floor dysfunction: an imaging panel and practical approach, *Ultrasound Obstet Gynecol.* 2003;22:205–13.
47. Faul F, Erdfelder E, Lang AG, Buchner A. G*Power 3: A flexible statistical power analysis program for the social, behavioral, and biomedical sciences. *Behav Res Methods.* 2007;39:175–91.
48. Moher D, Hopewell S, Schulz KF, Montori V, Gotzsche PC, Devereaux PJ, et al. CONSORT 2010 explanation and elaboration: updated guidelines for reporting parallel group randomised trials. *BMJ* 2010;340:c869.
49. Altman D, Väyrynen T, Engh ME, Axelsen S, Falconer C. Nordic Transvaginal Mesh Group. Anterior colporrhaphy versus transvaginal mesh for pelvic-organ prolapse. *N Engl J Med.* 2011;364(19):1826–36.
50. Cervigni M, Natale F, La Penna C, Panei M, Mako A. Transvaginal cystocele repair with polypropylene mesh using a tension-free technique. *Int Urogynecol J Pelvic Floor Dysfunct.* 2008;19(4):489–96.
51. Dwyer PL, O'Reilly BA. Transvaginal repair of anterior and posterior compartment prolapse with Atrium polypropylene mesh. *BJOG.* 2004; 111(8):831–6.
52. Giberti C, Gallo F, Cortese P, Schenone M. Transobturator tape for treatment of female stress urinary incontinence: objective and subjective results after a mean follow-up of two years. *Urology* 2007; 69(4):703–7.
53. Maher C. Anterior vaginal compartment surgery. *Int Urogynecol. J* 2013; 24:1791–1802.

54. Kapur K, Dalal V. Mesh repair of vaginal wall prolapse. *Med J Armed Forces India*. 2014;70(2):105–110.
55. Jasaits Y, Sergent F, Tanneau Y, Marpeau L. Vesicovaginal fistula after transobturator tape. *Prog Urol* 2007; 17:253–5.
56. Yamada BS, Govier FE, Stefanovic KB, Kobashi KC. Vesicovaginal fistula and mesh erosion after Perigee (transobturator polypropylene mesh anterior repair). *Urology* 2006; 68:1121.e5–1121.e7.
57. Starkman JS, Meints L, Scarpero HM, Dmochowski RR. Vesicovaginal fistula following a transobturator midurethral sling procedure. *Int Urogynecol J Pelvic Floor Dysfunct* 2007; 18:113–5.
58. Kelemen Z, Lehoczký G. Repair of fistulas in the vesicovaginal area by forming a urinary reservoir. *Eur Urol* 1986; 12:398–9.
59. Abed H, Rahn DD, Lowenstein L, Balk EM, Clemons JL, Rogers RG, et al. Incidence and management of graft erosion, wound granulation, and dyspareunia following vaginal prolapse repair with graft materials: a systemic review. *Int Urogynecol J* 2011;22(July 7);789-98.

10. ACKNOWLEDGEMENTS

I would like to thank all my colleagues at the Departments of Urology or Obstetrics and Gynaecology for their participation in the survey and for thus supporting me in my work and assisting me in obtaining results of better quality. I am also grateful to Andrea Surányi M.D., Ph.D., and Zoltán Kozinszky M.D., Ph.D., for their patience and support in overcoming numerous obstacles I have been facing through my research.

I would like to thank my former master and professor László Pajor, M.D., Ph.D., for his kind feedback and cooperation and for leading me into the mysteries of urogynaecology. In addition, I would like to express my gratitude to Attila Pal, M.D., Ph.D., who supported me in my urological studies.

Nevertheless, I am also grateful to Professors Gil Levy, M.D., György Bártfai, M.D., D.Sc., for involving me in their valuable international study. Working together was a great pleasure for me.

I wish to express my appreciation to Zoltan Bajory, M.D., D.Sc., and Gábor Németh, M.D., Ph.D., for sharing their pearls of wisdom with me in the process of writing this thesis and for their comments on earlier versions of the manuscript.

Last but not least, I would like to thank my family – my parents, my sister, my wife and my four children – for supporting me spiritually throughout the writing of this thesis and my life in general.

11. APPENDIX

ÖSSZEFOGLALÁS

A kismedencei süllyedés tünetcsoport (POP) a nők jelentős százalékánál előforduló kórkép, mely miatt az életük során a nőbetegek 20%-a esik át egy vagy több rekonstrukciós műtéten [1]. A POP-al együttesen fennálló stressz inkontinencia (SUI) előfordulási aránya 63-80% közé tehető [2]. A klasszikus mellső hüvelyfali plasztika descensus relapszus rátája igen magas (26-58%), továbbá a stressz inkontinencia csökkentő hatása is elhanyagolható, csupán (42%–62%) [3,4]. Ugyanakkor ismert, hogy az igen hatékony hüvelyi hálóműtétek posztoperatív komplikációs aránya igen magas. A nem felszívódó hüvelyi hálók esetében emelkedett, *de novo* Stressz inkontinencia (1,39-es relatív kockázat) hólyagperforáció (3,92 relatív kockázat) és posztoperatív dyspareunia aránnyal kell számolni [5].

A szintetikus transzvaginális hálókat a magas sikerességi arányuk miatt az utóbbi időben a POP különféle formáiban egyre nagyobb népszerűséggel alkalmazták. Az Amerikai Élelmezési és Gyógyszer Hivatal (FDA) 2008 és 2011-ben megjelent figyelmeztetését követően az urogynecológusok mind inkább rákényszerültek, hogy a kevésbé hatékony, de biztonságos ún. „non mesh” technikák és a jó hatásfokú viszont sok posztoperatív szövődményt adó hálóműtétek közötti egyensúlyt megtalálják [6]. A fentiek miatt egy retrospektív tanulmányt végeztünk a hüvelyi hálóműtét (TVM) és a klasszikus mellső hüvelyplasztika POP és SUI csökkentő hatásának összehasonlítására, továbbá a korai (6 hét) és késői (36 hónap) komplikációs arányok a felmérésére. Tanulmányunk során azt találtuk, hogy a TVM műtét szignifikánsan jobban oldotta meg a POP-ot (91,3% vs. 66,3%; $p < 0,001$) és a SUI-t (90% vs. 55%, $p < 0,001$) 3 éves után követés során. Ugyanakkor *de novo* urge inkontinencia (DNUS) a TVM csoportban gyakrabban volt megfigyelhető (11,86% vs. 0%). A háló kilökődési arányt 8,3%-nak találtuk tanulmányunk során.

Korábbi tanulmányok a hüvelyi hálóműtétek alacsonyabb SUI csökkentő hatását írták le. Tanulmányunk során a TVM mellső szárát két öltéssel a peri-urethrális szövetekhez rögzítettük, melytől az anti-inkontinens hatás növekedését vártuk. Egy randomizált prospektív tanulmányt terveztünk a fenti rögzítési technika anti-SUI hatásának a tisztázása céljából.

A beültetett hüvelyi hálók összeugrása, felgyűrődése az idegek kompressziója, továbbá a rögzítő karokra kifejtett fokozott húzó hatáson keresztül keresztül lehetnek felelősek a háló beültetést követően jelentkező kismencedei fájdalomért. Ismert és jól dokumentált, hogy a hálók felgyűrődése, összeugrása a kismencedei fájdalom, dyspareunia és a háló kilökődésnek az oka. A fentiek miatt egy teljesen új elképzelésnek megfelelően fixáció nélküli implantátum került kialakításra a mesh műtétek szövödmény rátájának a csökkentése céljából. Az elképzelésünk az volt, hogy egy *neo-pubovascularis fastia* jól tudja utánózni a kismencedei szervek fiziológiás rögzítését, így egy flexibilis karokkal ellátott hálót terveztünk.

Multicentrikus tanulmányunkban résztvevő húsz betegből tizenhétnek (84,2%) a POP-Q rendszer szerinti 0 stádiumú, míg három betegnek (15,8) 1. stádiumú süllyedése volt kétéves után követést követően. Háló kilökődését, vagy krónikus kismencedei fájdalmat nem találtunk.

A korszerű infrapubicus műtéttechnikák elterjedésével a hólyagperforációk és a következményes vesico-vaginális fisztulák (VVF) előfordulási aránya jelentősen javult, ugyanakkor a kórkép megfelelő ellátása mind a mai napig nehézséget okoz. Egy régi, de jól bevált műtéttechnikát a Lehoczky lebenyplasztikát vezettük be újra a hálók okozta VVF ellátására. A három hónapos után követés során a három résztvevő egyikénél sem találtunk maradvány fisztulát.

Hüvelyi hálóműtétek gyakorlata az amerikai korlátozó figyelmeztetés után

Merjem, vagy ne merjem?

Fekete Zoltán dr. ■ Körösi Szilvia dr. ■ Németh Gábor dr.

Szegedi Tudományegyetem, Általános Orvostudományi Kar, Szent-
Györgyi Albert Klinikai Központ, Szülészeti és Nőgyógyászati
Klinika

Bevezetés: A kismedencei szervek süllyedésének (POP) előfordulási aránya az életkor előrehaladtával növekszik, és az idősödő nőpopuláció jelentős többségét érinti. Az elmúlt évtizedben széles körben elterjedtek a POP rekonstrukció-ja céljából alkalmazott szintetikus transvaginalis háló (TVM)-műtétek. Az Amerikai Egyesült Államok Élelmiszer- biztonsági és Gyógyszerészeti Hivatala (FDA) által 2008-ban, majd 2011-ben kiadott figyelmeztetést követően a hálóműtétek számában drasztikus csökkenés volt megfigyelhető, ugyanakkor mind a mai napig nem érhető el megfelelő hatékonyságú műtét.

Célkitűzés: A tanulmány célja a klasszikus, háló nélküli és háló felhasználásával történő kismedencei helyreállító mű- tétek hatékonyságának összehasonlítása volt POP-csökkentő és antiincontinens (anti-SUI-) hatás, valamint intra-, peri- és késői (36 hónap) posztoperatív komplikációs ráta alapján.

Módszer: 2013. január és 2014. január között összesen 120, II-III. stádiumú, mellső-középső kompartment-süllye- désben és genuin stresszincontinenciában szenvedő, műtéti ellátásra került beteg adatait elemeztük. TVM-műtéten 60 nőbeteg, Kelly-Stoeckel-vaginoplasticán további 60 nőbeteg esett át. A műtéti komplikációkat Clavien-Dindo (CD)-rendszer segítségével határoztuk meg.

Eredmények: A mellső hüvelyfali süllyedés megszüntetésével (91,6% vs. 63,3%; $p < 0,001$), továbbá anti-SUI tekinte- tében (90% vs. 55%, $p < 0,001$) a TVM-műtéttel szignifikánsan jobb eredményt lehetett elérni, mint a Kelly-Stoeckel plasztikai műtéttel, ugyanakkor hálókilökődés a vizsgált 36 hónapos utánkövetés alatt 8,33%-ban fordult elő. A Cla- vien-Dindo-beosztás szerinti perioperatív szövődmény tekintetében a két csoport között szignifikáns eltérés nem igazolódott ($p = 0,405$).

Következtetés: A hüvelyi hálóműtétek jó eredménnyel és elfogadható rövid és hosszú

távú szövődmenyprofillal alkal- mazhatók mind POP-rekonstrukció, mind a POP-ot kísérő genuin SUI megszüntetése céljából. A helyes indikációs kör betartása, a tökéletes műtéttechnika elsajátítása ugyanakkor megkerülhetetlen a tökéletes operatív eredmény el- éréséhez.

Orv Hetil. 2018; 159(10): 397–404.

Kulcsszavak: transvaginalis hálóműtét, mellső hüvelyplastica, komplikációk, SUI és POP-QII-III, Clavien-Dindo- klasszifikáció

Vaginal mesh operations in the urogynecological practice after the FDA warnings

Use or not to use mesh?

Introduction: The prevalence of pelvic organ prolapse (POP) with aging is escalating alarmingly, and now becoming a growing epidemic among the elderly. Synthetic transvaginal mesh (TVM) has been employed with increasing po- pularity in the treatment of POP until the end of the last decade. After the U.S. Drug and Food Administration (FDA) warnings in the years 2008 and 2011, the number of vaginal mesh operations has decreased dramatically.

Aim: The aim of the study was to evaluate and compare the anti-POP effectivity, the anti-stress incontinence (anti-SUI) efficacy, and the late (36 months) post-operative complications of the anterior vaginoplasty and the TVM operations.

Method: We analysed the clinical data from 120 patients with stage II–III anterior prolapse and concomitant SUI who had undergone surgery at a tertiary referral centre in Hungary between January 2013 and January 2014. Sixty patients underwent Kelly–Stoeckel vaginoplasty and the other 60 cases had TVM operation. The surgical complications were classified using the Clavien–Dindo (CD) classification system.

Results: The anti-POP (91.6% vs. 63.3%; $p < 0.001$) and the anti-SUI efficacy (90% vs. 55%, $p < 0.001$) were significantly higher in the TVM group than in the vaginoplasty group, while the overall extrusion rate was found 8.3% after a 3-year follow-up. The Clavien–Dindo score (CD) proved that the early post-operative complication profile was similar among the TVM patients as compared to the vaginoplasty group ($p = 0.405$).

Conclusion: Vaginal mesh surgery represents an effective procedure for prolapse and concomitant SUI with a decreased risk of short- and long-term complications.

Keywords: transvaginal mesh, anterior vaginoplasty, complications, SUI with POP–Q II–III, Clavien–Dindo classification

Fekete Z, Körösi Sz, Németh G. [Vaginal mesh operations in the urogynecological practice after the FDA warnings. Use or not to use mesh?]. *Orv Hetil.* 2018; 159(10): 397–404.

(Beérkezett: 2017. október 12.; elfogadva: 2017. november 23.)

Rövidítések

BMI = (body-mass index) testtömegindex; CD = Clavien–Dindo-klasszifikáció; DNUS = (*de novo* urge symptoms) *de novo* urge tünetek; FDA = (U.S. Food and Drug Administration) az USA Élelmiszer-biztonsági és Gyógyszerészeti Hivatala; POP = (pelvic organ prolapse) kismencedei süllyedés; POP–Q = (Pelvic Organ Prolapse Quantification) a kismencedei süllyedést értékelő pontrendszer; RCT = (randomized controlled trial) randomizált kontrollált vizsgálat; RR = (regression rate) kiújulási arány; SUI = (stress urinary incontinence) stressz-incontinencia; SZTE = Szegedi Tudományegyetem; TVM = (transvaginal mesh) hüvelyi hálóműtét; ÚTI = alsó húgyúti infekció

A kismencedei szervek süllyedése (POP – pelvic organ prolapse) a 60 év feletti nők mintegy 65%-át érintő elváltozás, mely magában foglalja a hüvely mellső és hátsó falának, illetve a méhnek az anatómiai pozícióból történő kimozdulását [1]. A probléma olyan gyakori, hogy egy amerikai tanulmány szerint 11,1%-ra tehető annak a valószínűsége, hogy egy leánygyermek az élete során POP vagy/és vizeletincontinencia miatt műtéten esik át [2].

A POP kialakulásában – az integrált kismencedei anatómiának megfelelően – a tartószalag és az izomrendszerek sérülésének, a medencefenék-izomzat innervációs károsodásának van szerepe [3]. A kismencedei süllyedés pontos helyének és mértékének meghatározására nemzetközi társaságok (International Continence Society, International Urogynecological Association) standardizált rendszere, a „Pelvic Organ Prolapse Quantification” (POP–Q) használható, melynek segítségével a kismencedei status változása pontosan követhető [4].

Az állapot időben történő felismerését nehezíti, hogy a süllyedés által okozott széklet-, vizeletürítési zavar, valamint a kismencedei fájdalom mértéke nem arányos pontosan a süllyedés mértékével, így a betegek sokszor már előrehaladott stádiumban kerülnek az ellátórendszerbe. További problémát jelent, hogy a POP az esetek mintegy 60–80%-ában szövődik vizelettartási zavarral (UI) [5], és jelen ismereteink szerint nem létezik olyan, jó határfokú műtéti eljárás, mely mindkét kórképet egyszerre és tartósan képes javítani. Ugyancsak nehezíti és drágítja az ellátást, hogy a POP miatt operált betegek mintegy 29%-a vagy descensus, vagy vizelettartási zavar miatt 4 éven belül ismételt műtetre kerül [6].

A POP hatékony ellátása

A POP hatékony és tartós megoldása már régóta célja az orvosi ellátórendszereknek, a hálóműtétek megjelenéséig azonban a descensus-tünetcsoport tartós megszüntetése csupán álom maradt. A korábban alkalmazott rekonstrukciós műtéti eljárások, így a Kelly–Stoeckel-hüvelyplastica, a manchesteri plastica egyéves utánkötés során is csupán 34,5%-os hatékonysággal oldotta meg a kismencedei szervek süllyedését [7]. Más szerzők is igen magas, közel 40%-os kiújulási arányt említenek az egyéb cystokeleműtéteknél [8]. A hasfali sérv rekonstrukciós elveinek követésével, már igen korán próbálkoztak laterális típusú cystokele polipropilénhálózattal történő rögzítésével [9], mely jó hatékonysága mellett nem elhanyagolható szövődményrátaival hívta fel magára a figyelmet, továbbá akkor még a háló kismencedei izomzatba történő megfelelő rögzítése sem volt megoldva.

Az alkalmazott hüvelyi hálók jobb rögzítésére a *De-lorme* által 2001-ben megvalósított subpubicus transob-

turator műtéttechnika adott lehetőséget. Ennek előnye az alacsonyabb szövődményráta, a könnyebb kivitelezhetőség és az anatómiai húgycső helyzetéhez jobban idomuló rugalmas rögzítés volt [10]. A műtét továbbgondolásával és a kismencedei kötőszöveti rendszerek ismeretével a 2000-es évek során számos hüvelyi transvaginalis műtéttechnikat dolgoztak ki (Gynecare Total Prolift System, Gynecare Gynemesh, AMS Perigee Anterior System, AMS Elevate Anterior System, A.M.I. BSC Mesh) [7, 8, 11–13]. Ezen műtéttechnikák között a behelyezett hálók rögzítési pontjaiban, irányjaiban, a felhasznált anyagokban, a segédeszközökben, a fixációs pontok számában és az öltések tekintetében volt jelentős különbség. Az alkalmazott technikák 3 és 5 éves sikereségi rátája 95,6–98% között alakult [8, 14], ami a tradicionális rekonstrukciós műtétekkel szemben jelentős javulás volt. A hüvelyi hálóműtétek bevezetését követően, kellő tapasztalatok birtokában, az izolált apicalis POP „arany standard” műtéti ellátása a laparotomiás és laparoscopiás behatolásból, műanyag hálóval végzett sacrocolpohysteropexia, vagy közkezdveltebb nevén a promontofixatio lett.

A műtéttechnikák fejlődésével együtt az alkalmazott hálók minősége is jelentősen javult, 2011 óta a piacon maradó cégek már csak ún. „lightweight”, vékony szálvastagságú monofilament hálókat gyártottak.

A hálóműtétek szövődményei

A hüvelyi hálóműtétek száma 2005 és 2008 között hihetetlen mértékben, a 16,5-szeresére – 2%-ról 35%-ra – emelkedett. Ezzel párhuzamosan egyre több tapasztalat gyűlt össze ezek szövődményeiről [15]. A hálóműtétek relatíve alacsony kiújulás mellett (2–4,8%) [8, 14] viszonylag magas szövődményrátaival bírtak. Így a háló eróziója, mint a leggyakoribb és a betegek számára a legtöbb szenvedést okozó eltérés, 3,8–43,6% között [8, 14, 16–19], visszatérő húgyúti infekciók az esetek 2,9%-ában [20], *de novo* urge incontinencia (DNUS) 8,7–17%-ban [8, 20] fordult elő. Dyspareunia hüvelyi hálóműtétet követően az esetek 28,6%-ában lépett fel, ugyanakkor érdekes tény, hogy a hüvelyi és a has felől behelyezett hálók között szignifikáns eltérést ezen nem volt megfigyelhető [21, 22].

Az amerikai korlátozó figyelmeztetések

Az FDA 2008-ra több mint ezer különféle súlyos – akár életet veszélyeztető – és enyhébb mellékhatásról és szövődményről kapott jelentést hüvelyi háló- és szalagműtétekkel kapcsolatban. A 2001 és 2008 között, majd 2001 és 2011 között fellelhető irodalom áttekintésével szisztematikus elemzést végeztek, és a kapott eredményeket 2008 októberében, majd annak frissítését 2011 júliusában adták ki [23]. A két figyelmeztetés az alábbi öt fő megállapítást tartalmazta: 1) A hálóműtétek szövődményei nem fordulnak elő tradicionális rekonstrukciós mű-

téteknél – a hasi, azaz infraperitonealis rekonstrukciós műtétek alacsonyabb szövődményrátaival járnak, mint a hüvelyi műtétek. 2) A tradicionális műtétekhez képest a hüvelyi hálóműtétek az apicalis és a hátsó kompartment rekonstrukciójában nem adnak pluszelőnyt. 3) A tradicionális technikákhoz képest a mellő kompartment rekonstrukciója során szignifikánsan jobb eredmények érhetők el. 4) A betegek szubjektív megelégedettségében nem tudtak kimutatni eltérést a két műtéti alaptípus között. 5) A szövődményráta tekintetében az alkalmazott hálók minőségében és a gyártók között lényegi különbség nem mutatkozott.

A fenti megállapítások miatt az FDA azt javasolta, hogy az egészségügyi szolgáltatók az alábbi szükséges lépéseket tegyék meg:

Speciális képzőprogramok indítása szükséges, hogy az operatórok nagyobb sikerességgel tudják elvégezni a műtéteket.

Az egészségügyi szolgáltatóknak fel kell készülniük a szövődmények időbeli ellátására, ehhez a betegek szoros utánkövetése szükséges.

A hüvelyi műtéteknél a hálóbehelyezések során a nyársakkal okozott mellésérülések – hólyagsérülés, bélsérülés – elkerülése érdekében fokozott körültekintéssel kell eljárni.

A betegeket fel kell világosítani, hogy a behelyezett hálók tartósan a szervezetben maradnak, további szövődményeket okozhatnak, így szükség lehet további műtétek elvégzésére.

A betegeket fel kell világosítani arról, hogy súlyos szövődmények – dyspareunia, hegeseések, hüvelyszűkületek – kialakulhatnak, melyek rontják a betegek életminőségét.

A gyártók által kiadott felvilágosító nyomtatványokkal minden beteget el kell látni.

Az ellátó orvosoknak mérlegelniük kell a hálóműtétek előnyeit és hátrányait a többi, nonmesh és konzervatív kezelési eljárással szemben. A hálóműtéteket csak megfelelő indikáció mellett javasolt használni.

A hasi behatolásból történő infraperitonealis hálóműtétek szövődményráta alacsonyabb, mint a hüvelyi műtéteké.

Prospektív, randomizált, kontrollált tanulmányok tapasztalatai

Az FDA-felvilágosítások legfőbb hiányossága abban rejlett, hogy esettanulmányok, nem pedig randomizált, kontrollált prospektív (RCT) közlemények, továbbá főként az Egyesült Államokból származó irodalmi adatok alapján tette megállapításait. Ismert, hogy Európában és a Távol-Keleten a központosítottabb ellátórendszer és a nagy specializált centrumok meglete miatt jóval alacsonyabb szövődményrátaikat közöltek a szerzők, hiszen a műtéteket tapasztaltabb, speciális szakképesítésű orvosok végezték. További nehézséget ad a hüvelyi hálómű-

tét-technikák sokszínűsége, valamint az alkalmazott hálók eltérő minősége, szálvastagsága és szövésmintázata.

Maier és mtsai éppen ezen RCT-tanulmányok hiányára hívják fel a figyelmet, és 37 RCT adatainak összegyűjtésével próbálnak a kialakult bizonytalanságban némi támpontot nyújtani az ellátóknak [24]. Ugyancsak a fenti kérdést vizsgálták *Schimpf és szerzői* 66 közlemény metaanalízisével [19]. Vizsgálták a természetes rekonstrukciós műtétek és a bentmaradó, nem felszívódó hüvelyi és hasi hálók rekonstrukatív potenciálját, összehasonlították a szövődmenyrátákat és a mellékhatásprofilokat. Ugyancsak görcső alá helyezték a felszívódó, nem permanensen bentmaradó hüvelyi hálók és a nonabszorbens műanyag hálók és a biológiai graftok közötti eltéréseket is.

A metaanalízis során azt a nem meglepő eredményt kapták, hogy a hüvelyi nonabszorbens hálók használatával a tradicionális műtétechnikával szemben a POP kisebb valószínűséggel újul ki (RR: 0,66). A fentiekből következik, hogy az ismételt műtét ritkább a POP-kiújulás miatt hálóműtéten átesett betegek körében (RR: 0,53), mint a saját szöveti rekonstrukciós műtétek esetében. A reoperációra hálóműtét után *de novo* stresszincontinentia (SUI) és mesh okozta hüvelyfali erózió miatt kényszerülünk. Intraoperatív hólyagsérülés (RR: 3,92) és *de novo* SUI jóval gyakrabban figyelhető meg hálóműtétet követően, mint természetes szöveti rekonstrukciók után (RR: 1,39), ugyanakkor – meglepő módon, a korábbi nem randomizált tanulmányokkal szemben – implantátumműtétet követően nem találtak az RCT-tanulmányok szignifikánsan magasabb *de novo* dyspareuniát (RR: 0,92). A vizsgálatok – a számos meglévő (PQOL, PFDI-20, PGI-1, PFIQ-7, PFDI-SF) és egymásnak nem megfeleltethető életminőségeszketnek betudhatóan – nem tudtak megbízható kinyilatkoztatást tenni az életminőség tekintetében.

A közlemények egyértelműen bebizonyították, hogy a felszívódó hálók 1–2 éves utánkövetés során semmilyen rekonstrukatív előnnyel nem bírnak a természetes fixációs műtétekkel szemben (RR: 1,05); sajnos az életminőségről, dyspareuniáról nem tudtak érdemben nyilatkozni. Ugyancsak nem tudták adatokkal igazolni a biológiai graftok létjogosultságát. Ezen műtétek sikerességi rátájában, mellékhatásprofiljában és reoperációs frekvenciájában a saját szöveti rekonstrukcióval szemben nem mutatkozott lényegi eltérés.

Saját vizsgálatok

Az ellentmondások miatt klinikánk saját anyag feldolgozásával kívánta vizsgálni a hüvelyi hálóműtétek megbízhatóságát, mellékhatásprofilját, továbbá mind a POP-ra, mind a SUI-ra kifejtett hatását, valamint a tradicionális Kelly–Stoeckel-féle mellső hüvelyfali plasticával szembeni terápiás előnyét. A tanulmányba csak olyan betegeket vontunk be, akiknek csak izolált mellső és középső kom-

partment-, POP-Q szerinti II–III-as stádiumú descensusuk volt, továbbá megelőző urodinamiás vizsgálattal igazolni lehetett kísérő genuin SUI meglétét.

Anyag és módszer

A retrospektív tanulmányba bevont minden beteg (60–60 eset) POP-Q szerinti II–III-as stádiumú mellső-középső kompartmentdescensusban, illetve Bonney- és PAD-tesztel igazolt genuin SUI-ban szenvedett. A betegek 2013. január és 2014. január között az SZTE Szülészeti és Nőgyógyászati Klinikáján estek át *Letouzey* szerinti mellső hüvelyfali hálóműtéten [8], valamint az ugyanebben az időszakban Kelly–Stoeckel-féle mellső hüvelyfali plasticán átesett csoportból 60 beteget válogattunk be tanulmányunkba. A csoportokat – amennyire lehetséges volt – mind életkor, mind paritás és BMI tekintetében homogenizáltuk. A bevonási kritérium a POP mellett fennálló genuin stresszincontinentia és a megfelelő utánkövethetőség volt. A korábban bármilyen hüvelyi vagy hasi rekonstrukciós műtéten átesett betegeket kivettük a vizsgálatból. Ugyancsak kizárási kritérium volt a kombinált antidepresszáns gyógyszeres kezelés, valamint a korábban kezelt kismencedei daganatos megbetegedés.

Elsődleges végpontként a kismencedei süllyedést helyreállító, míg másodlagos végpontként az együttesen fennálló SUI-t korrigáló hatást vizsgáltuk mind a TVM-műtéten, mind a Kelly–Stoeckel-plasticán átesett betegcsoportnál. A tanulmány során sikeres anti-POP-hatás-ként ítéltük meg, ha a POP-Q-rendszernek megfelelően az Aa és a Ba pontnak megfelelően több mint 1 cm-es csökkenést detektáltunk a 36. posztoperatív hónapban. Ugyancsak vizsgáltuk az apexre (C pont) és a teljes hüvelyhosszra (TVL) kifejtett hatásokat. Sikeres anti-SUI-hatásként a negatívvá váló Bonney- és PAD-tesztet határoztuk meg.

Harmadlagos végpontként a *Clavien–Dindo* [25] szerinti perioperatív szövődmenyekben, továbbá a hosszú távú posztoperatív szövődmenyekben tapasztalt eltéréseket vizsgáltuk a két csoportban.

A TVM-műtét során a *Letouzey* által leírt hüvelyi hálóműtétet végeztük, melyhez 100% polipropilén monofilament, nem felszívódó Aspide® SURGIMESH® PROLAPSE hálót használtunk (Aspide Médical, La Talaudière, Franciaország). Az alkalmazott háló pórusnagysága 1,6 × 1,7 mm volt. A hüvelyfalat az alkalmazott háló felett csomós Vicryl® 2/0-ás felszívódó fonállal egyesítettük (Ethicon, Issy-les-Moulineaux, Franciaország). A műtét során 16 Ch-s Foley-katéter került felhelyezésre, melyet a műtétet követő első 12 órában eltávolítottunk. A beavatkozás során ugyancsak 12 órára hüvelyi gézcsík került felhelyezésre.

Kelly–Stoeckel-plastica során a cervicovaginalis fastia egyesítése két nem felszívódó Prolene® 2/0-s öltéssel történt (Ethicon, Issy-les-Moulineaux, Franciaország);

a hüvelyfalat – csakúgy, mint a TVM-műtételnél – csomós Vicryl® 2/0-s felszívódó fonállal egyesítettük. A műtét során, a TVM-műtéttel megegyezően, 12 óra megfigyelési időszakra 16 Ch-s Foley-katéter és gézcsík került felhelyezésre. A vizsgálati csoportokban rögzítettük a bemetszéstől az utolsó varrat behelyezéséig eltelt tiszta műtési időt, valamint a becsült vérvesztésüket. A vérzés mennyiségét az operatőr, az asszisztens orvos és a műtősnő egymástól függetlenül becsülte, majd a három érték átlaga került rögzítésre a műtétet követően.

Mindkét műtéttípuson átesett betegek a hólyagkatéter és a hüvelyi tampon eltávolítása és a residuais vizelet-mennyiség ultrahanggal történő meghatározása után az első posztoperatív napon otthonukba távoztak.

A TVM-műtéten és a hüvelyplasticán átesett betegeket a 6. heti korai vizsgálatot követően a klinikai rutin-nak megfelelően félévente rendeltük vissza ellenőrző vizitekre. Az első kontrollvizsgálat során mindkét csoportban rögzítésre kerültek a Clavien–Dindo (CD)-beosztásnak megfelelően a korai perioperatív szövődmények [25].

Az első, majd az azt követő megjelenések mindegyikén POP–Q-stádium-meghatározás, Bonney-teszt, a postmictiós residuais vizelet mennyiségének meghatározása és rutin-vizeletvizsgálat, valamint a hüvelyfali heg ellenőrzése történt.

Statisztikai analízis

Az adatok elemzésére az SPSS 17.0 programcsomagot használtuk. A kategorikus és a folyamatos változó értékeket kétmintás t-próbával, χ^2 -próbával és a Kruskal–Wallis-tesztel hasonlítottuk össze. A szignifikanciaszintet a p-érték <0,05 szintjén határoztuk meg.

Eredmények

Eredményeinket a mellékelt táblázatokban foglaljuk össze. A TVM-műtéten és a mellső hüvelyfali plasticán át-esett csoportok között sem az életkor ($p = 0,47$), sem a paritás ($p = 0,44$), sem a BMI-érték ($p = 0,17$), sem pedig a menopausalis status ($p = 0,08$) tekintetében nem detektáltunk szignifikáns eltérést (1. táblázat). Az átlagos műtési idő tekintetében ugyan a hálóműtét szignifikánsan hosszabb ($39,01 \pm 5,95$ min vs. $35,55 \pm 6,92$ min; $p = 0,002$) volt, a műtési vérvesztés ($83,08 \pm 71,72$ ml vs. $75,33 \pm 26,0$ ml; $p = 0,71$), az intraoperatív melléksérülés és a transfúziós igény tekintetében nem találtunk jelentős eltérést. A TVM-csoportban gyakrabban fordult elő 100 ml feletti postmictiós residuum, ez azonban nem bizonyult szignifikánsnak. Vérzés és vizeletretenció miatt végzett korai – első hat héten belüli – reoperációk tekintetében a vizsgált csoportok között nem találtunk eltérést (2. táblázat).

A két csoportot a 36. posztoperatív hónapban a POP- és a SUI-helyreállító képesség vonatkozásában vizsgálva, a TVM-műtét POP- ($91,6\%$ vs. $66,3\%$; $p < 0,001$) és

1. táblázat | A TVM- és a colporrhaphiacsoport alapjellegzetességei

	TVM (n = 60)	p-érték	Colporrhaphia (n = 60)
Életkor (év) (átlag \pm SD)	59,83 \pm 9,95	0,47	59,95 \pm 9,53
Szülés (átlag \pm SD)	2,08 \pm 0,61	0,44	2,1 \pm 0,70
BMI (kg/m ²) (átlag \pm SD)	28,46 \pm 2,97	0,17	27,9 \pm 3,4
Postmenopausalis állapot, n (%)	45 (75,00)	0,08	52 (86,67)

2. táblázat | A TVM- és a colporrhaphiacsoport operatív és korai (6 hét) posztoperatív jellegzetességei

	TVM (n = 60)	p-érték	Colporrhaphia (n = 60)
Műtési idő (min) (átlag \pm SD)	39,01 \pm 5,95	0,002	35,55 \pm 6,92
A vérzés becsült mennyisége (ml) (átlag \pm SD)	83,08 \pm 71,72	0,71	75,33 \pm 26,0
Transzfúzióigény, n (%)	0 (0)	n. m.	0 (0)
Intraoperatív melléksérülés, n (%)	0 (0)	n. m.	0 (0)
100 ml feletti posztoperatív vizeletresiduum, n (%)	5 (8,33)	0,103	1 (1,67)
Reoperáció vérzés miatt, n (%)	3 (5,0)	0,309	1 (1,67)
Reoperáció teljes retenció miatt, n (%)	1 (1,67)	0,752	1 (1,67)

3. táblázat | A TVM- és a colporrhaphiacsoport vizsgált paraméterei a 36. posztoperatív hónapban

	TVM (n = 60)	p-érték	Colporrhaphia (n = 60)
Posztoperatív SUI, n (%)	6 (10)	<0,001	27 (45)
Posztoperatív POP, n (%)	5 (8,33)	<0,001	22 (36,67)
Visszatérő alsó húgyúti infekció, n (%)	12 (20)	0,590	12 (20)
de novo Urge incontinentia, n (%)	7 (11,86)	0,006	0 (0)
Hálóerózió, n (%)	5 (8,33)	n. m.	n. m.
Összes reoperáció, n (%)	10 (16,67)	0,043	21 (35,00)
Reoperáció (SUI), n (%)	1 (1,67)	0,103	5 (8,33)
Reoperáció (POP), n (%)	5 (8,33)	0,007	16 (26,67)
Reoperáció (erózió), n (%)	5 (5,88)	n. m.	n. m.

4. táblázat | A POP-Q-rendszer változása 36 hónapos megfigyelési időszakot követően a vizsgált kompartmentekben

	TVM (n = 60)			p-érték	Colporrhaphia (n = 60)		
	Preoperatív	Posztoperatív 36 hó	Átlagos változás		Preoperatív	Posztoperatív 36 hó	Átlagos eltérés
Aa (átlag ± SD)	-0,98 ± 0,59	-1,37 ± 0,55	-0,42 ± 0,6	<0,001	-1,03 ± 0,18	-0,7 ± 0,64	0,3 ± 0,59
Ba (átlag ± SD)	0,4 ± 0,64	-1,72 ± 1,00	-2,08 ± 0,99	<0,001	-0,46 ± 0,72	-0,93 ± 1,4	-0,5 ± 1,11
C (átlag ± SD)	-6,56 ± 1,09	-6,82 ± 0,87	-0,25 ± 0,77	<0,001	-6,66 ± 0,63	-6,4 ± 0,79	0,27 ± 0,51
TVL (átlag ± SD)	8,26 ± 0,68	7,9 ± 0,63	-0,35 ± 0,48	<0,001	7,88 ± 0,32	7,88 ± 0,32	0 ± 0

stresszincontinentia-csökkentő képessége (90% vs. 55%, $p < 0,001$) szignifikánsan jobbnak bizonyult (3. táblázat). A POP-Q-rendszer Aa ($p < 0,001$), Ba ($p < 0,001$), C ($p < 0,001$) pontjait vizsgálva a 36. hónapban szignifikánsan jobb eredményeket találtunk a hálócsoportban, mint a hüvelyplasticán átesett betegcsoportban, viszont a TVM-műtét a plasticához viszonyítva szignifikánsan rövidítette a teljes hüvelyhosszt (4. táblázat).

Hálóeróziót 8,3%-ban detektáltunk az első 36 hónapban a TVM-műtéten átesett betegek körében. DNUS tekintetében szignifikánsan több esettel találkozunk, mint a nonmesh csoportban (11,86% vs. 0%). Reoperáció mind residualis incontinentia (1,6% vs. 8,3%; $p = 0,107$), mind POP-kiújulás (8,3% vs. 26,7%; $p = 0,007$) miatt gyakrabban fordult elő a tradicionális hüvelyplastica csoportjában (3. táblázat). A CD-beosztás szerinti korai perioperatív szövődmények tekintetében nem találtunk szignifikáns különbséget a két vizsgált csoport között (5. táblázat).

5. táblázat | A Clavien–Dindo szerinti perioperatív szövődményráta a TVM- és a colporrhaphiacsoportban a műtétet követő első 6 hétben

	TVM (n = 60)	p-érték	Colporrhaphia (n = 60)
CD 0, n (%)	40 (66,67)	0,405	45 (75)
CD 1, n (%)	11 (18,33)		6 (10)
CD 2, n (%)	6 (10)		8 (13,33)
CD 3b, n (%)	3 (5)		1 (1,67)

Megbeszélés

Tanulmányunk a nemzetközi irodalomban fellelhető adatokkal harmonizálva, a hálóműtétek magasabb POP-javító képességét igazolta a tradicionális mellső hüvelyfali plastikával szemben (81,0–60,3% vs. 65,6–34,5%) [7, 26, 27]. Eredményeink a korábbi tanulmányok sikerességi arányánál is jobb eredményt adtak (91,3% vs. 81,0–60,3%), aminek a háttérében műtéttechnikai eltérés állhat. Behelyezett hálóinkat az obturatorárokban történő rögzítés mellett mind a húgycsőhöz, mind posterior irányban a paracervicalis gyűrűhöz rögzítjük, ott az eszköz kifeszítetten, felszíne folyamatosan simán marad, to-

vább a rögzítések megelőzik a háló mögötti és előtti hüvelyszakaszok herniálódását.

Jelenismeretünk szerint nem létezik olyan műtéti eljárás, mely a POP-ot és a concomitans SUI-t egy ülésben jó hatékonysággal rekonstruálni tudja. Vizsgálatunk során, mint másodlagos végpont, tanulmányoztuk a két descensuscsökkentő műtét stresszincontinentiára kifejtett hatását is. Eredményként azt kaptuk, hogy egy időben fennálló genuin stresszincontinentia esetén a TVM-műtét 90%-ban, míg a hüvelyfali plastica szignifikánsan kevésbé hatékonyan, csupán 55%-ban oldotta meg a stresszincontinentiát. A nemzetközi irodalmi adatokkal összevetve hálóműtétünk más meshműtéténél (83,3%) jobb [14], míg az „arany standard” sling műtétekhez közel hasonló mértékű rekonstrukciós hatással bírt (87–92%) [28, 29]. A tapasztalt magas sikerességi arány véleményünk szerint annak köszönhető, hogy műteteink során a behelyezett háló mellső szarát két fixáló öltéssel a későbbi hálóelcsúszás megelőzése céljából, a húgycső középső harmadához rögzítjük, melytől megfeszítve a húgycső középső harmadát emeli meg, biztosítva ezzel a jó antiincontinentia-effektust.

A tanulmányunk során tapasztalt hálókilökődést 8,3%-ban találtunk, ami jól korrelál a nemzetközi irodalmi adatokkal (3,9–16%) [6, 7, 8, 24]. Klinikai gyakorlatunknak megfelelően minden alkalommal, amikor a háló a hüvelyfalon keresztül megjelent, azt függetlenül a hüvelyfali dehiscencia méretétől extruszióknak tekintettük, és a háló teljes egészében eltávolításra került.

Perioperatív, korai szövődmények tekintetében a TVM-csoportban minimálisan gyakrabban tapasztaltunk mellékhatásokat, mint a nem hálóműtéten átesett csoportban, ugyanakkor a szövődmények jóval enyhébb fokúak voltak, a leggyakrabban fájdalomcsillapító-igénnyel és átmeneti húgyúti fertőzéssel találkoztunk.

A műtét elvégzéséhez szükséges idő érthető módon szignifikánsan hosszabbnak mutatkozott a TVM-csoportban, mint a háló nélküli csoportban (39,01 ± 5,95 min vs. 35,55 ± 6,92 min), viszont az általunk mért műtét idő a TVM-csoportban a nemzetközi irodalomban szereplőnél jobb volt (60,9 min) [30]. A becsült vérvesztés tekintetében a két csoport között nem találtunk jelentős eltérést, és az általunk becsült vérzés az

irodalmi adatoknál jóval csekélyebb mértékű volt (83,1 ml vs. 180 ml) [24].

A hálóműtési csoportban az egyik leggyakoribb hosszú távú szövődmény a visszatérő húgyúti infekció volt, melynek előfordulási gyakoriságában a tradicionális hüvelyplasticával összehasonlítva eltérést nem találtunk (20-20%). A fentiek miatt azt feltételezzük, hogy a húgyúti infekció kialakulásában inkább a hormonstatus változása, mintsem a hálóimplantátum megléte játszik szerepet. A 11,8%-ban előforduló DNUS szignifikánsan gyakrabban figyelhető meg a hálóműtött csoportban, aminek a hátterében a háló mellső szárának a húgycsőhöz történő rögzítése állhat. Antikolinerg kezeléssel minden egyes esetben orvosolni tudtuk a meglévő panaszokat, így a hálórögzítés okozta mellékhatások hosszú távon nem befolyásolták negatívan betegeink életminőségét.

Következtetések

A POP rekonstrukciójának igen hatékony módja a hüvelyi vagy a hasi infraperitonealis műanyag hálóval történő implantátumműtét. A műtétek kezdeti, válogatás nélküli, széles körű, sokszor helytelen indikációs alkalmazása miatt az utóbbi időben a műtétek mellékhatásai és szövődményei kerültek előtérbe. Az FDA-figyelmeztetések következtében, főleg az Egyesült Államokban, az implantátumműtétek számát csökkentették, noha a jelen ismereteink szerint nincs olyan, háló nélküli műtési eljárás, mely akár csak megközelítő sikerrátával is bírna, mint az implantátumműtétek.

A nemzetközi tanulmányokkal megegyezően saját vizsgálatunk során is azt az eredményt kaptuk, hogy az alkalmazott hálóműtét rekonstruktív képességben mind a sülyyedést helyreállító, mind a genuin stresszincontinenciára kifejtett hatás tekintetében szignifikánsan jobb, mint a háló nélküli Kelly–Stoeckel-plastica. Korai intra- és perioperatív szövődmények tekintetében a két műtét-technika között jelentős eltérés nem igazolódott. A hosszú távú utánkötés eredményei azt mutatják, hogy a hálóműtéten átesettek körében nagyobb arányban (11,9%) alakul ki DNUS. Ebben a csoportban a leg súlyosabb szövődményt, a háló kilökődését a betegek 8,3%-ánál tapasztaltuk. Az általunk észlelt kilökődés (8,3%) és DNUS-előfordulás (11,9%) a nemzetközi irodalommal (3,8–43,6% és 8,7–17%) teljesen megegyezik [8, 14, 16–18, 20].

Ismert, hogy egy-egy új műtét-technika a kezdeti lelkesedést követően – a mellékhatások felszínre kerülésével – háttérbe szorul, majd a megfelelő tapasztalat birtokában elfoglalja megfelelő helyét a terápiás palettán, így várhatóan megszűnik a hálóműtétek teljes elutasítása. Az FDA-ajánlásokat szem előtt tartva, a megfelelő indikációs kör alkalmazásával, a betegek széles körű felvilágosításával, a hüvelyi és a hasi hálóműtétek az erre szakosodott ellátócentrumokban elvégezhetők.

A várható eredményekről és szövődményekről a betegeket kellőképpen tájékoztatni kell. Véleményünk szerint hatékony utánkötési rendszer kialakításával a műtési szövődmény magasabb aránya jelentősen csökkenthető, így a hüvelyi hálóműtétek napjainkban tapasztalható trónfosztása megszüntethető.

Anyagi támogatás: A közlemény megírása anyagi támogatásban nem részesült.

Szerzői munkamegosztás: F. Z.: A kézirat elkészítése, a hipotézis felállítása, a vizsgálat lefolytatása. K. Sz.: Adatgyűjtés, az adatok feldolgozása. N. G.: A kézirat megszövegezése. A szerzők a cikk végleges változatát elolvasták és jóváhagyták.

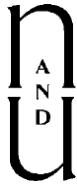Érdekltségek: A szerzőknek nincsenek érdekltségeik.

Irodalom

- [1] Digesu GA, Chaliha C, Salvatore S, et al. The relationship of vaginal prolapse severity to symptoms and quality of life. *BJOG* 2005; 112: 971–976.
- [2] Olsen AL, Smith VJ, Bergstrom JO, et al. Epidemiology of surgically managed pelvic organ prolapse and urinary incontinence. *Obstet Gynecol.* 1997; 89: 501–506.
- [3] Fritsch H, Lienemann A, Brenner E, et al. Clinical anatomy of the pelvic floor. *Adv Anat Embryol Cell Biol.* 2004; 175(III–IX): 1–64.
- [4] Persu C, Chapple CR, Cauni V, et al. Pelvic Organ Prolapse Quantification System (POP-Q) – a new era in pelvic prolapse staging. *J Med Life* 2011; 4: 75–81.
- [5] Molander U, Milsom I, Ekelund P, et al. An epidemiological study of urinary incontinence and related urogenital symptoms in elderly women. *Maturitas* 1990; 12: 51–60.
- [6] Milani R, Salvatore S, Soligo M, et al. Functional and anatomical outcome of anterior and posterior vaginal prolapse repair with prolene mesh. *BJOG* 2005; 112: 107–111.
- [7] Altman D, Väyrynen T, Engh ME, et al., for the Nordic Transvaginal Mesh Group. Anterior colporrhaphy versus transvaginal mesh for pelvic-organ prolapse. *N Engl J Med.* 2011; 364: 1826–1836.
- [8] Letouzey V, Deffieux X, Gervaise A, et al. Trans-vaginal cystocele repair using a tension-free polypropylene mesh: more than 5 years of follow-up. *Eur J Obstet Gynecol Reprod Biol.* 2010; 151: 101–105.
- [9] Julian TM. The efficacy of Marlex mesh in the repair of severe, recurrent vaginal prolapse of the anterior midvaginal wall. *Am J Obstet Gynecol.* 1996; 175: 1472–1475.
- [10] Delorme E. Transobturator urethral suspension: mini-invasive procedure in the treatment of stress urinary incontinence in women. *Prog Urol.* 2001; 11: 1306–1313. [Article in French]
- [11] Cervigni M, Natale F, La Penna C, et al. Transvaginal cystocele repair with polypropylene mesh using a tension-free technique. *Int Urogynecol J Pelvic Floor Dysfunct.* 2008; 19: 489–496.
- [12] Rane A, Kannan K, Barry C, et al. Prospective study of the Perigee system for the management of cystoceles – Medium-term follow up. *Aust NZ J Obstet Gynaecol.* 2008; 48: 427–432.
- [13] Hiltunen R, Nieminen K, Takala T, et al. Low-weight polypropylene mesh for anterior vaginal wall prolapse: a randomized controlled trial. *Obstet Gynecol.* 2007; 110: 455–462.
- [14] Sergent F, Resch B, Diguët A, et al. Vaginal prolapse and stress urinary incontinence: combined treatment by a single prosthesis. *Prog Urol.* 2006; 16: 361–367. [Article in French]

- [15] Wang LC, Al Hussein Al Awamih B, Hu JC, et al. Trends in mesh use for pelvic organ prolapse repair from the Medicare database. *Urology* 2015; 86: 885–891.
- [16] Chen YS, Cao Q, Ding JX, et al. Midterm prospective comparison of vaginal repair with mesh vs Prolift system devices for prolapse. *Eur J Obstet Gynecol Reprod Biol.* 2012; 164: 221–226.
- [17] Lo TS, Tan YL, Cortes EF, et al. Influence of anterior vaginal mesh with concomitant mid-urethral sling surgery on stress urinary incontinence: clinical and sonographic outcome. *Aust NZ J Obstet Gynaecol.* 2015; 55: 593–600.
- [18] Long CY, Hsu CS, Wu CH, et al. Three-year outcome of transvaginal mesh repair for the treatment of pelvic organ prolapse. *Eur J Obstet Gynecol Reprod Biol.* 2012; 161: 105–108.
- [19] Schimpf, MO, Abed H, Sanses T, et al. Graft and mesh use in transvaginal prolapse repair: A systematic review. *Obstet Gynecol.* 2016; 128: 81–91.
- [20] Yetimalar H, Eraslan T, Burcu K, et al. Comparison of Burch colposuspension and colporrhaphy anterior-Kelly plication operations for effectiveness and influence on life quality. *Akush Ginekolo (Sofia).* 2011; 50: 42–48.
- [21] Khandwala S, Jayachandran C. Transvaginal mesh surgery for pelvic organ prolapse—Prolift+M: a prospective clinical trial. *Int Urogynecol J.* 2011; 22: 1405–1411.
- [22] Gupta P, Payne J, Killinger KA, et al. Analysis of changes in sexual function in women undergoing pelvic organ prolapse repair with abdominal or vaginal approaches. *Int Urogynecol J.* 2016; 27: 1919–1924.
- [23] US Food and Drug Administration. UPDATE on Serious Complications Associated with Transvaginal Placement of Surgical Mesh for Pelvic Organ Prolapse: FDA Safety Communication. Available from: <https://www.fda.gov/medicaldevices/safety/alertsandnotices/ucm262435.htm> [accessed: July 13, 2011].
- [24] Maher C, Feiner B, Baessler K, et al. Transvaginal mesh or grafts compared with native tissue repair for vaginal prolapse. *Cochrane Database Syst Rev.* 2016; 2: CD012079.
- [25] Dindo D, Demartines N, Clavien PA. Classification of surgical complications: a new proposal with evaluation in a cohort of 6336 patients and results of a survey. *Ann Surg.* 2004; 240: 205–213.
- [26] De Tayrac R, Cornille A, Eglin G, et al. Comparison between transobturator trans-vaginal mesh and traditional anterior colporrhaphy in the treatment of anterior vaginal wall prolapse: results of a French RCT. *Int Urogynecol J.* 2013; 24: 1651–1661.
- [27] Carey M, Higgs P, Goh J, et al. Vaginal repair with mesh versus colporrhaphy for prolapse: a randomised controlled trial. *BJOG* 2009; 116: 1380–1386.
- [28] Giberti C, Gallo F, Cortese P, et al. Transobturator tape for treatment of female stress urinary incontinence: objective and subjective results after a mean follow-up of two years. *Urology* 2007; 69: 703–707.
- [29] Csorba R, Lampé R, Simó D, et al. Our experiences with transobturator tape surgery performing 150 cases. [A transobturator tape műtéttel szerzett tapasztalataink másfél száz eset kapcsán.] *Orv Hetil.* 2007; 148: 1649–1655. [Hungarian]
- [30] Kapur K, Dalal V. Mesh repair of vaginal wall prolapse. *Med J Armed Forces India* 2014; 70: 105–110.

(Fekete Zoltán dr.,
Szeged, Semmelweis u. 1., 6725
e-mail: feketezoltan@med.u-szeged.hu)



Consecutive Vesicovaginal Fistula for Transobturator Sling Perforations and Successful Repairs With Skin Flap

Zoltan Bajory,* Zoltan Fekete, Istvan Kiraly, Istvan Szalay, and
Laszlo Pajor

Department of Urology, University of Szeged, Szeged, Hungary

Aim: To report a reconstructive technique of large vesicovaginal fistula repairs, which is a rare complication of the most modern anti-incontinence procedures (tension-free tapes) using the “oldie but goodie” Lehoczky’s island flap. **Methods:** Women with large vesicovaginal fistulas caused by mid-urethral transobturator tape were operated in our department. The transobturator tape was removed and the large fistula was closed using the skin island flap. The flap was created from the regional skin and subcutaneous tissue and pulled with intact vascular supply through a paravaginal tunnel to the site of the vaginal defect. **Results:** No complications occurred after the reconstructions. The patients have become permanently continent and free from fistulas. **Conclusions:** Mid-urethral transobturator sling is a successful procedure evidenced worldwide with a very low rate of fistula formation. Lehoczky’s island flap can be a reasonable and safe surgical option in the repair of large defects of the vaginal wall. *Neurourol. Urodynam.* 30:1530– 1532, 2011. © 2011 Wiley Periodicals, Inc.

Key words: incontinence; lehoczky’s island flap; perforation; TOT; vesicovaginal fistula

INTRODUCTION

The mid-urethral tension-free vaginal tape procedures¹ have revolutionized the treatment of female stress urinary incontinence.² The urinary bladder perforation, a typical complication (4.5–10%) of this procedure, was minimized successfully by using the transobturator route of the tape placement (TOT).^{3–6} Due to the very low rate of bladder perforation,^{7,8} the vesicovaginal fistula formation is an extremely rare complication.^{9–11}

In general, the repair of vesicovaginal fistulas—wider than 2 cm—is a challenge for the surgeon. The technique of the repair depends mainly on the characteristics of the fistula and the personal experience of the surgeon. Most of the simple and small vesicovaginal fistulas can be managed by a transvaginal access.^{9–11} If the fistula is larger than 2 cm and there is severe damage in the surrounding tissue, the repair requires more complex procedures, mainly tissue substitution. The Lehoczy's island flap can be a good option for fistula closure.^{12,13}

To our knowledge, herein we refer the first few cases using Lehoczy's island flap to repair vesicovaginal fistulas after TOT procedures.

MATERIALS AND METHODS

Women (mean age 62.4, n 3) with clear stress urinary incontinence underwent TOT procedure using monofilament polypropylene tapes (Surgimesh sling 45 1 VS112-KY, Aspide Medical, France) at different hospitals. The transobturator approach was performed as described by Delorme³ using a helical tunneler from the outside entrance point to adjust the tape from the vagina to the skin without any tension. The patients neither had anterior compartment prolapse, serious genitourinary infection, previous transvaginal surgery nor any other aggravating circumstances. Reviewing the operative reports and patients' histories, there were no intra-operative complications therefore, intra-operative cystoscopies were not performed.

After the TOT operations, the patients became continent, but as a novelty, in all cases urgency and frequency developed. The urine analysis showed pyuria and microscopic hematuria. Antibiotics were introduced several times, which temporally decreased the patients' complains.

In one case, 4 months after the surgery, the patient was presented with a severe inflammation of the skin, where the trocar had been introduced previously during TOT procedure. A subcutaneous abscess was diagnosed and an operation was performed at our department, and the abscess and the distal part of the tape were excised. The wound-healing was complete with no more complains of this area.

Four to seven months after the original operations, all of the patients reported a few drops of urine on their pads. This mild incontinence became a severe urine loss within a few days. The patients could distinguish this kind of leakage clearly from their original stress incontinence, because this was continuous and did not depend on any movements or body positions.

Ultrasonographies showed normal bladder structures. Cystoscopies revealed serious inflammations in the bladders and fistulas where a 2–3 cm-long parts of the polypropylene tapes were visible, which eroded the trigonal mucosa close to the right ureteral orifice in two cases and on the left side in one case. Vaginal examinations revealed that the fistulas are located in the upper right (in two cases) and left (in one case) quadrant vaginal wall (with a diameter of more than 1.5 cm), and surrounded by wide, inflamed scar. Urine leakage was clearly visible in the vagina in all cases.

After premedication with iv. antibiotics (2 × 750 mg cefuroxime/day) and sc. low molecular weight heparine (1 × 0.2 ml

Conflict of interest: none. Dirk

De Ridder led the review process.

*Correspondence to: Zoltan Bajory, MD, PhD, Department of Urology, University of Szeged, 6725 Szeged Kalvaria sgt. 57., Hungary. E-mail: bajory@freemail.hu Received 24 January 2011; Accepted 1 March 2011

Published online 29 June 2011 in Wiley Online Library

(wileyonlinelibrary.com).

DOI 10.1002/nau.21114

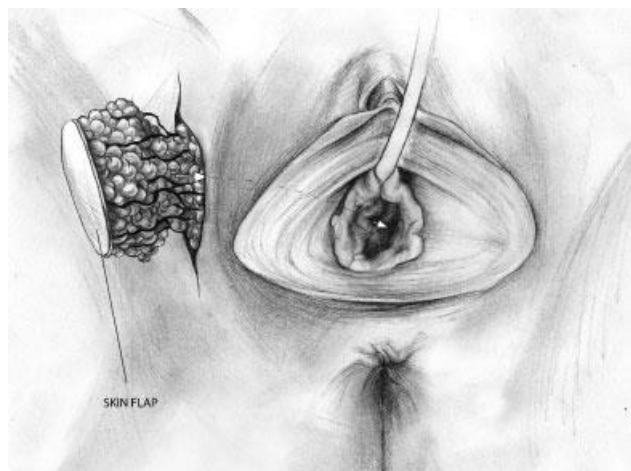


Fig. 1. The island flap of the skin and the underlying adipose tissue were widely mobilized with intact blood and nerve supply, and it was pulled into the vagina through a tunnel.

enoxaparine sodium/day), the patients were underwent for surgical vesicovaginal fistula repairs. The method of operations was very similar in all cases. The patients were positioned in lithotomy positions on the operating table. The vagina was exposed by a deep episiotomy. The vaginal part of the fistula and the wide inflamed area were excised. The sling was excised totally from the vaginal and bladder wall. Six French ureteral catheters were introduced into the right or the left ureter to protect it during the operation. The opening of the fistula in the bladder was closed by absorbable interrupted sutures. The bladder wall was closed and a drain was fixed. The vaginal wall defects were too large for simple closures, so Lehoczy's skin flaps were dissected from the area of the genitofemoral sulcus in all cases. This island flap is an oval-shaped skin flap (with a diameter of 3–4 cm), lateral to the labium major on the same side as the fistula is. The skin and the underlying voluminous adipose tissue were mobilized down to the fascia of the muscles with intact blood and nerve

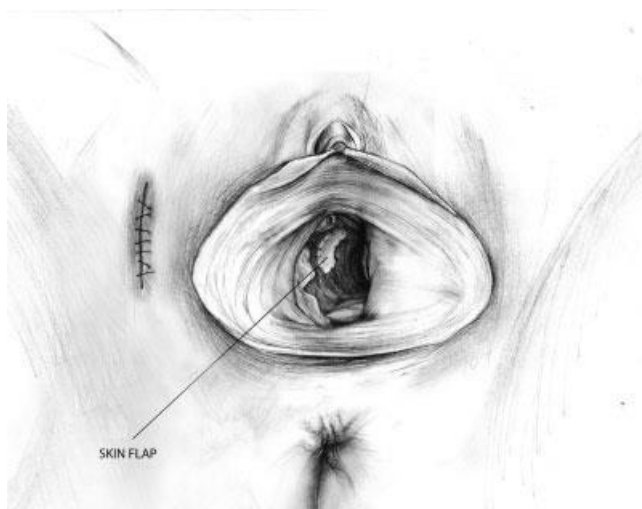

Fig. 3. The skin covered the vaginal defect as a patch and its edges were sutured to the wall of the vagina. The donor site of the flap was closed by interrupted sutures.

supply. It was achieved by isolating a fatty pedicle, which contained the terminal branches of internal pudendal artery and pudendal nerve. The island flap was pulled into the vagina through a tunnel under the bulbocavernosus muscle (Fig. 1). The fatty part of the flap was situated between the vagina and the bladder wall (Fig. 2) and protected against retraction in the paracolpium with deep sutures, while the skin covered the vaginal defect as a patch and its edges were sutured to the wall of the vagina. The donor site of the flap was closed by interrupted sutures. (Fig. 3). A urethral catheter was fixed for 10 days.

RESULTS

No intra- or post-operative complications occurred. After the removal of the catheter the patients passed urine freely and became continent.

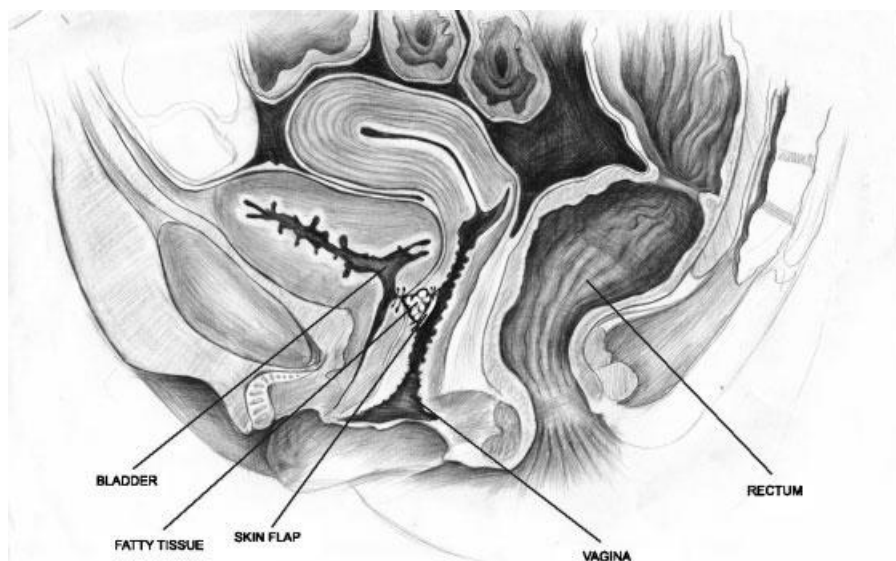


Fig. 2. The fatty part of the flap was interposed between the vagina and the bladder.

Neurourology and Urodynamics DOI 10.1002/nau

Three weeks later, cystoscopies showed only the scar tissue of the operated area without any fistula. Vaginal examinations revealed that the Lehoczky's island flap healed per primam.

At the final follow-up (3 months), the patients were continent, free of fistula, and reported sexual activity without any complains.

DISCUSSION

TOT is widely accepted, minimally invasive procedure in the treatment of female stress urinary incontinence with high success and low complication rates.³ The rate of bladder perforation, a typical complication of the suprapubic tension-free vaginal tapes, is decreased dramatically with this technique.^{7,8} To our knowledge, there are only three reports in the literature dealing with vesicovaginal fistulas after transobturator sling or mesh operations.⁹⁻¹¹ The fistula development is supposed to be caused by the foreign body (TOT tape) contaminated with urine permanently and the consecutive chronic disturbances of the wound healing processes, the local chronic inflammatory reactions and the microcirculatory failure of the affected tissue layers. All of the authors agree with the principle that the complete removal of the tape is essential before the fistula closure together with a wide extirpation of the scar.

These procedures and the fistula repairs are challenging and difficult operations even in the hand of well-trained surgeons. The use of the traditional methods of surgical repairs leads to considerable complications in the treatment of vesicovaginal fistulas if there is severe radiation

damage of the surrounding tissues or wide resection of the fistula is necessary. Nevertheless,

the use of Lehoczky's island flap can be a good option of the repair of large vaginal defects, based on the main principle of reconstructive surgery, which is to use healthy tissue for the repair in a tension-free manner. The main advantages of this technique are that the affected tissues and the fistula can be radically resected and substituted with a well-vascularized skin flap.

The flap is large enough and mobile to reach easily the site of the defect and the tension free suture line can be performed. A large defect of the vaginal wall can be supplied with proper size of skin to prevent vaginal shrinkage. The

fatty part of the flap ensures a sufficient interposed tissue between the bladder and the vaginal wall.

We reported unique vesicovaginal fistula repairs after failed TOT procedures. A complete removal of the tape and a radical fistula resection were necessary, due to the serious damages of the surrounding tissues. Lehoczky's island skin flaps were used to repair the large defects. The operations were successful without any complications.

CONCLUSIONS

An intra-operative cystoscopy is mandatory in suspicion of a bladder perforation during TOT operation.

Perforation increases the risk of fistula formation.

In case of a fistula formation a complete tape removal and radical resection of the damaged tissues

are necessary.

Lehoczky's island flap can be a reasonable surgical option of the repair of large defects of the vaginal wall.

REFERENCES

6. Ulmsten U, Petros P. Intravaginal slingplasty (IVS): an ambulatory surgical procedure for treatment of female urinary incontinence. *Scand J Urol Nephrol* 1995;29:75–82.
7. Smiths ARB, Dmochowski R, Hilton P, Rovner E, Nilsson CG, Reid FM, Chang D, Abrams P, Cardozo L, Khoury S, Wein A. Surgery for urinary incontinence in woman. Incontinence (4th International Consultation on Incontinence) Health publication Ltd 4th edn.; 2009. p. 1193–272.
8. Delorme E. Transobturator urethral suspension: mini-invasive procedure in the treatment of stress urinary incontinence in women. *Prog Urol* 2001;11: 1306–13.
9. de Leval J. Novel surgical technique for the treatment of female stress urinary incontinence: transobturator vaginal tape inside-out. *Eur Urol* 2003;44:724–30.
10. Hung MJ, Liu FS, Shen PS, Chen GD, Lin LY, Ho ES. Analysis of two sling procedures using polypropylene mesh for treatment of stress urinary incontinence. *Int J Gynaecol Obstet* 2004;84:133–141.
11. Fischer A, Fink T, Zachmann S, Eickenbusch U. Comparison of retropubic and outside in transobturator sling systems for the cure of female genuine stress urinary incontinence. *Eur Urol* 2005;48:799–804.
12. Minaglia S, Ozel B, Klutke C, Ballard C, Klutke J. Bladder injury during trans-obturator sling. *Urology* 2004;64:376–7.
13. Smith PP, Appell RA. Transobturator tape, bladder perforation, and paravaginal defect: a case report. *Int Urogynecol J Pelvic Floor Dysfunct* 2007;18:99–101.
14. Jasaitis Y, Sergeant F, Tanneau Y, Marpeau L. Vesicovaginal fistula after trans-obturator tape. *Prog Urol* 2007;17:253–5.
15. Yamada BS, Govier FE, Stefanovic KB, Kobashi KC. Vesicovaginal fistula and mesh erosion after Perigee (transobturator polypropylene mesh anterior repair). *Urology* 2006;68:1121.e5–1121.e7.
16. Starkman JS, Meints L, Scarpero HM, Dmochowski RR. Vesicovaginal fistula following a transobturator midurethral sling procedure. *Int Urogynecol J Pelvic Floor Dysfunct* 2007;18:113–5.
17. Lehoczky G. Neue Fisteloperation. *Wiss Z Humboldt-Univ Berl* 1963;12: 171–2.
18. Kelemen Z, Lehoczky G. Repair of fistulas in the vesicovaginal area by forming a urinary reservoir. *Eur Urol* 1986;12:398–9.

Self-retaining support implant: an anchorless system for the treatment of pelvic organ prolapse—2-year follow-up

Gil Levy¹  & Anna Padoa² & Zoltan Fekete³ & George Bartfai³ & Laszlo Pajor³ & Mauro Cervigni⁴

Received: 14 March 2017 / Accepted: 26 June 2017

The International Urogynecological Association 2017

Abstract

Introduction and hypothesis The search for an improved vaginal mesh prompted the development of a new anchorless implant. The objective was to report on outcome after 2 years of a technique using a self-retaining support (SRS) implant. **Methods** Patients with anterior vaginal wall prolapse, with/without apical prolapse, were recruited. Participants underwent surgical repair using the SRS device.

Demographic data, pre-surgical Pelvic Organ Prolapse Quantification (POP-Q) scoring, quality of life (QoL) questionnaires (Pelvic Floor Distress Inventory Short Form 20 [PFDI-20], Pelvic Organ Prolapse/Urinary Incontinence Sexual Questionnaire 12 [PISQ-12]), and surgical data were collected. Patients were followed at 2 weeks, 2, 6, 12, and 24 months after surgery. Objective anatomical success was defined using the NIH criteria.

Results Twenty women were recruited for the study with an average age of 62.1 years and an average parity of 4.0 deliveries. Average BMI was 28. Pre-operative mean POP-Q measurements were Aa =1.40 (–1 to 3) cm, Ba = 2.3 (–1 to 6) cm

The surgical technique was presented as a video presentation at the 2015 IUGA meeting, Nice, France (<https://www.youtube.com/watch?v=WT0V-WCeYkU>). The abstract including preliminary data was presented as an e-poster at the 2016 IUGA meeting, Cape Town, South Africa

* Gil Levy
2gillevy@gmail.com

- 1 Maynei Hayeshua Medical Center, 17 Povarski Street, Bnei Brak, Israel
- 2 Asaf HaRofeh Medical Center, Tel Aviv, Israel
- 3 Szeged University Hospital, Szeged, Hungary
- 4 Catholic University, Rome, Italy

Published online: 14 July 2017

and C = 0.4 (–7 to 6) cm. Surgical time averaged 31.2 min. Estimated blood loss averaged 165 ml. No intra-operative complications were observed. One case (5%) of frame erosion was documented 8 months after surgery. At 2 years' followup, mean POP-Q measurements were: Aa = –2.95 (–3 to –2) cm, Ba = –2.85 (–3 to –2) cm, and C point –6.90 (–10 to –3) cm. Seventeen (85%) patients had stage 0 and 3 patients (15%) had stage 1. No mesh erosions or chronic pelvic pain were documented at follow-up. The total PFDI score at follow-up was decreased by 92.8 points ($p < 0.0001$).

Conclusions At 2 years' follow-up, the SRS implant was found to be safe, showing no intra-operative or immediate post-operative complications. All women presented with POP-Q measurements of the anterior and apical compartment at normal value ($Ba \leq -2$ cm) and statistically significant subjective improvement.

Keywords Pelvic organ prolapse . Vaginalmesh .

Self-retaining support implant

Introduction

Despite providing good anatomical results compared with traditional native tissue repair, the use of vaginal mesh for the treatment of pelvic organ prolapse has been accompanied by more severe intra- and post-operative complications, such as organ perforation, bleeding, mesh erosion, mesh contraction, and pain [1, 2].

This rather high complication rate has led the FDA to publish public alerts in 2008 and 2011 (<https://www.fda.gov/>

[Safety/MedWatch/SafetyInformation/SafetyAlertsforHumanMedicalProducts/ucm079028.htm](https://www.fda.gov/MedWatch/SafetyInformation/SafetyAlertsforHumanMedicalProducts/ucm079028.htm), <https://www.fda.gov/MedicalDevices/Safety/>

[AlertsandNotices/ucm262435.htm](#)). Clinical studies support the conclusion that mesh-anchoring techniques are a major risk factor for complications with the current commercial mesh kits [3].

The search for the optimal solution for POP treatment is based on the need to imitate the natural physiology of the pubo-cervical fascia, providing the anatomical benefits of mesh implants, while eliminating the complications of current techniques. A review of the literature provides solid evidence that the anchoring techniques that accompany the placement of vaginal implants are a major factor in the occurrence of complications: organ perforation during the anchoring technique, unbalanced scar formation at the anchoring points, tension, folding, and contraction that can cause pain, dyspareunia, and failure leading to re-operation [3, 4].

For this purpose, a new concept involving an anchorless implant was developed. The assumption was that an anchorless neo pubo-cervical fascia would accurately mimic the physiological supporting system, therefore providing adequate level II support. Furthermore, extending the neo-fascia to the level of the sacrospinous ligaments would achieve additional level I support. The device was named after its fundamental concept, SRS, which stands for self-retaining support.

The purpose of this report is to describe the results of the Bfirst in human^ series of patients who underwent surgery using the SRS implant. The study was carried out after meticulous evaluation in animal and cadaver models [5].

Materials and methods

This is a prospective, multicenter, international study for the evaluation of feasibility, safety, and cure rate of POP surgery using the SRS implant. Approval was obtained from the relevant health ministries and local ethics committees in Israel and Hungary, before recruitment.

Patients with at least second-degree anterior compartment prolapse were recruited from the gynecology clinics in each participating hospital. All participants signed an informed consent, translated to the local language, after a detailed explanation of the risks involved in vaginal implants was provided. Exclusion criteria included: previous POP repair with mesh, age > 75 years old, Pelvic Organ Prolapse

Quantification (POP-Q) scoring less than stage 2, or asymptomatic POP.

The device is composed of an ultra-light titanized polypropylene mesh (16 g/m²) stretched and retained in place by a Ushaped flexible frame made of a biocompatible implantable polymer (Fig. 1). The SRS lateral arms have been designed to mimic the shape of the arcus tendinous fascia pelvis (ATFP). The arms are connected ventrally by a bridge designed to allow the passage of the urethra. The frame is composed of a solid, but flexible material. The frame functions as a mesh-



Fig. 1 The self-retaining support (SRS) implant

retaining system by holding the mesh stretched under preload tension. Such tension prevents the mesh from bunching or contracting during the healing process. The shape of the device, which accurately imitates the anterior vaginal wall hammock, prevents mobilization and therefore no anchoring or fixation is required.

The surgical technique involves carrying out an anterior colpotomy and performing central dissection of the bladder from the vagina (Fig. 2). Dissection is then extended to the para-vesical space for direct bilateral palpation of the ischial spines. The surgeon can choose one of three implant sizes: small, medium and large. The difference among the sizes is the length of the lateral arms. The implant is positioned in place with no tension, with the arms not flexed and the mesh fully stretched. Should any tension be applied on the implant, the surgeon should remove the implant, extend the dissection area and re-insert or change the size of the implant. The device is inserted between the bladder and the vaginal mucosa with the lateral arms following the anatomy of the ATRP. The connecting bridge is positioned under the pubic symphysis. Appropriate location is confirmed by visualization of a symmetrically positioned device and a fully stretched mesh under the bladder. In the case of uterine preservation, the cervix is sutured to the proximal edge of the mesh. No other anchoring

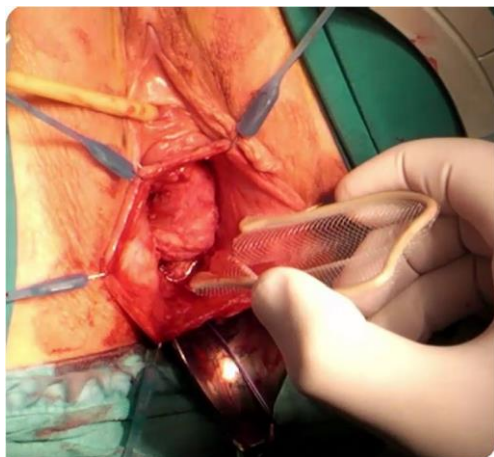


Fig. 2 Surgical insertion of the SRS

techniques are used. The vaginal incision is closed with no tension and vaginal packing is used for 24 h.

Demographic and background morbidity data, pre-surgical POP-Q scoring, and QoL questionnaires (validated Pelvic Floor Distress Inventory 20 [PFDI-20] and Pelvic Organ Prolapse/Urinary Incontinence

Sexual Questionnaire 12 [PISQ-12]) were collected [6]. Objective anatomical success was defined as POP-Q stage 0 and 1 prolapse using the NIH criteria [7]. The PFDI-20 is divided to three domains: Pelvic Organ Prolapse Distress Inventory 6 (POPDI-6), Colorectal– Anal Distress Inventory (CRADI-8), and Urinary Distress Inventory (UDI-8). Each domain is calculated in a 100-point scale and all are added to a total score ranging from 0 to 300. Subjective success was defined as subjects having an improvement in POPDI/PFDI score that achieved the minimally important difference (MID). Total PFDI-20 was evaluated using an MID of ≥15 points per domain or a total score of 45 points. PISQ-12 score ranged from 0 to 48 and MID = 6. Surgical data included intra- and post-operative complications, time of surgery, and estimated blood loss.

Postoperativedata included vital signs,laboratory results, pain level, and length of hospital stay. Patients were followed at 2 weeks, 2, 6, 12, and 24 months after surgery. Objective and subjective primary end points were defined at 24 months.

Statistical analysis used the analysis of variance (ANOVA) test, where the null hypothesis is that all subgroup means are equal. Results of the two-way ANOVA on change of points Aa, Ba, and C by subject and visit were analyzed, looking at P values of the term visit in the model to evaluate statistical significance. Pre- and post-surgery POP-Q measurements were calculated using a nonparametric Wilcoxon signed rank test.

Results

Twenty women were recruited for the study. The first patient was enrolled in September 2014. The last patient completed her 24-month follow-up visit in February 2017. None of the patients withdrew from the study and none was lost to followup at 12 months. One patient did not consent to the extension of the follow up period (originally 12 months) and did not participate in the last follow-up visit (at 24 months). Table 1 describes patients’ demographics. Eight patients were hypertensive and 2 were smokers. Pre-operative mean POP-Q measurements were Aa =1.40 (–1 to 3) cm, Ba =2.3 (–1 to 6) cm, and C = 0.4 (–7 to 6) cm. Nineteen (95%) patients suffered from both anterior and apical compartment prolapse, whereas one (5%) patient had only anterior prolapse.

All patients underwent transvaginal repair of anterior and apical compartment prolapse using the SRS. Five patients underwent concomitant vaginal hysterectomy for uterine abnormality and 5 had repair of the posterior compartment as

Table 1 Baseline demographic and clinical data

Variable	Value (N = 20)	SD
Mean age years (range)	61.95 (50–75)	6.58
Mean parity (range)	4.0 (1–16)	
Mean BMI (range) (kg/m²)	28.13 (20.3–35.4)	4.28
Previous prolapse surgery	5 (26%)	
Previous hysterectomy surgery	3 (15%)	

well. Surgical time for the SRS implantation averaged 31.2 (21–50) min. Estimated total surgical blood loss averaged 205 (150–500) ml. Estimated blood loss for patients who underwent an implant-only procedure averaged 165 ml. No intra-operative complications were observed.

Nineteen patients completed their 24-month follow-up visits. The overall mean follow-up period was 26.5 (range 24.7–29.6) months. Table 2 summarizes the anatomical outcome at 2 years' follow-up. Seventeen patients (84.2%) had stage 0 prolapse and 3 patients (15.8%) had stage 1 prolapse. At 24 months' follow-up, significant anatomical changes were found in the points Aa (1.4 to –2.9 cm), Ba (2.3 to –2.8 cm), and C (0.4 to –7 cm). No cases of mesh erosion or chronic pelvic pain were documented at follow-up.

As for the subjective outcome, summarized in Table 3, PFDI scores showed significant improvement in both prolapse and urinary domains in addition to improvement in total scores. No deterioration was noted in the colorectal or the incontinence domains of the questionnaire.

Considering a standard MID of 15 points per domain and 45 points in total PFDI scores, results showed a significant improvement in the prolapse domain, incontinence domain, and total PFDI-20 scores. POPDI-6 (POP domain) showed a decrease of 41.94 points ($p < 0.0001$) at follow-up from baseline scores. The CRADI-8 (posterior compartment domain) scores were 14.5 points ($p = 0.0016$) lower at follow-up than at baseline and demonstrate no deterioration at the posterior pelvic compartment. The UDI-6 (urinary incontinence domain) showed a decrease of 36.3 points ($p = 0.0167$). The total PFDI score was decreased by 92.75 points ($p = 0.0001$).

Thirteen patients (65%) were sexually active during the study and 10 patients filled in the PISQ-12 questionnaire. Of these patients, 5 reported a nonsignificant improvement, 4 had a significant improvement, and 1 had a nonsignificant deterioration. Three patients who were inactive became sexually active after surgery. None of these patients reported dyspareunia. Two intra-operative cystoscopies were performed for minimal hematuria, with no bladder injury documented. Post-operatively, one patient received one unit of packed cells and no events of urinary retention were recorded. One patient developed de novo stress urinary incontinence, which was treated successfully with pelvic floor muscle training.

Table 2 POP-Q measurements at baseline vs 24 months' follow-up

Variable	Pre-operatively n (%)/cm ± SD (range)	24 months post-operatively n (%)/cm ± SD (range)	P value*
POP-Q			
Stage 0	0	17 (85%)	
Stage 1	0	3 (15%)	
Stage 2	7 (35%)	0	
Stage 3	5 (25%)	0	
Stage 4	8 (40%)	0	
Mean			
Point Aa (cm)	1.4 ± 1.5 (–1 to 3)	–2.95 ± 0.2 (–2 to –3)	0.000
Point Ba (cm)	2.3 ± 2.6 (–1 to 6)	–2.8 ± 0.3 (–2 to –3)	0.000
Point C (cm)	0.4 ± 3.5 (–7 to 6)	–7 ± 1.6 (–10 to –5)	0.000
TVL (cm)	7.55 ± 1.35 (5–11)	7.75 ± 1.07 (6–10)	0.519
Ap (cm)	–1.40 ± 1.98 (–3 to 3)	–2.15 ± 0.93 (–3 to 0)	0.18
Bp (cm)	–1.2 ± 2.89 (–3 to 6)	–2.0 ± 1.026 (–3 to 0)	0.569

Values given as mean ± SD (range)
*Nonparametric Wilcoxon signed rank test

One case (5%) of frame erosion into the anterior vaginal wall was documented 8 months following the procedure. The eroded part of the frame was resected under local anesthesia in an ambulatory setting. The patient's symptoms were relieved immediately after the resection. This was the only case where a large frame was used, which we hypothesize to have caused excessive pressure on the vaginal mucosa, causing the erosion.

Discussion

Our results suggest that the clinical use of the SRS implant for the treatment of anterior and apical vaginal wall prolapse might be safe and effective, with no intra- or immediate

Table 3 QoL (Pelvic Floor Distress Inventory Short Form 20 [PFDI20], Pelvic Organ Prolapse/Urinary Incontinence Sexual Questionnaire 12 [PISQ-12]) scores at baseline vs follow-up

Variable	n	Pre-operatively n = 20 (SD)	24 months n = 19 (SD)	ifference	P value
Total PFDI 19 ^a		129.8 (61.59)	37.05 (62.17)	92.75	0.0001
POPDI-6	20	53.12 (26.8)	11.18 (19.15)	41.94	< 0.0001
CRADI-8	20	27.83 (23.55)	13.32 (23.98)	14.51	0.0258
UDI-6	20	48.88 (25.42)	12.54 (21.42)	36.34	0.0167
PISQ-12	9	29 (NA)	34 (NA)	5	NA

POPDI-6 Pelvic Organ Prolapse Distress Inventory 6, CRADI-8 Colorectal–Anal Distress Inventory 8, UDI-6 Urinary Distress Inventory 6

^a One patient lost to follow-up at 52 weeks

post-operative complications and optimal anatomical and subjective cure at 2 years.

According to data published by the FDA, most mesh complications are documented during the first 6 months following surgery and include organ perforation, bleeding, and mesh-related adverse events such as mesh erosion, mesh contraction, and pain. Twenty-four months' follow-up of the SRS was a sufficient basis for comparison with other mesh kits.

In comparison with reports on current available vaginal mesh kits, the safety profile and clinical outcome of the SRS implant seem significantly better: no mesh erosion, a single, preventable case of frame erosion (5%), no pain complications, and no negative impact on lower urinary tract symptoms. Intraoperative cystoscopy was performed in 2 patients for safety reasons. Routine cystoscopy should be considered, especially in concurrent prolapse surgery.

Furthermore, participating surgeons rated the implantation procedure as easy.[^] Although the present study was the first in-human clinical trial and represents the learning curve for the procedure, the operative time averaged only 30 min.

A recent publication by Huggele et al. [8] reported on the 2-year follow-up of 270 patients treated by transvaginal mesh for anterior and/or apical prolapse. The cohort included 95.2% pre-operative stage 3–4 anterior compartment prolapse. Reported outcome was of a 75.9% objective success rate for the anterior compartment at 1 year. Similar results reported by Azais et al. [9]. Data on complications included 7.5% rate of pain during pelvic examination at 1 year, 1.5% bladder injury,

11.1% buttock pain, 3% need for analgesic infiltration, and 7.8% post-operative voiding dysfunction. In our cohort of patients, there were no cases of pain or voiding dysfunction. None of our patients was re-operated for recurrent prolapse or stress urinary incontinence by the end of the first and second years.

Mesh contraction and bunching can cause nerve entrapment and excessive tension on the fixated mesh arms, which both lead to pain. It is documented that mesh folding and contraction is one of the reasons for chronic pelvic pain and dyspareunia. Partial removal of the mesh at the fixation points and reducing the tension on implanted mesh has been shown to resolve pain symptoms in 90% of patients [3]. It was shown that graft augmented colporrhaphy (mesh reinforced native tissue repair) and other non-fixation mesh techniques, cause less pelvic pain [10].

Current mesh kits provide a stand-alone mesh that is fixated at four corners in the pelvis. Although this is stressed by all manufacturer's instructions and training programs, current securement techniques do not ensure that the mesh is placed in a tension-free, flat, nonfolded fashion. Even when anchoring the mesh to four corners in a flat and tension-free configuration, there is no guarantee that dynamic pressures and scar accumulation construction forces will not cause mesh contraction and folding over time.

The SRS solid frame provides a long-term reassurance from mesh contraction and bunching.

Mesh erosion is probably the most common complication of surgery with the current mesh kits, with a reported incidence of 10.3% in a large meta-analysis [11] and of 12.2% in the latest Cochrane review on POP surgery [12]. We believe that elimination of mesh folding and bunching may reduce exposure through the vaginal incision and may lead to a lower mesh erosion rate.

Margulies et al. [4] identified mesh folding in 9 out of 13 patients suffering from vaginal mesh exposure. Mesh folding has been suggested as an important contributing factor in mesh exposure, secondary to local inflammatory reaction and interference with the healing process at the incision site.

The high exposure rate reported with past commercial kits has possibly been decreasing due to the current use of lightweight polypropylene mesh, which seems to reduce inflammatory reaction and mesh shrinkage [13]. Beyond containing ultralight polypropylene (16 g/m²), the SRS mesh contains titanium ions, which may have contributed to the low mesh erosion rate seen in our cohort [14].

Anchoring the mesh to four corners in a flat and tensionfree configuration does not prevent mesh contraction and folding over time. The SRS solid frame precludes mesh contraction and bunching.

In this clinical trial, there were no mesh erosions and only one case of frame erosion, which occurred secondary to application of a large device, and it was treated with good results. We believe that this adverse event could easily be prevented by the use of a smaller frame size and adequate dissection. Regarding dyspareunia, patients who were sexually active and completed the PISQ-12 questionnaire did not report dyspareunia, but we were unable to reach any conclusion owing to the small cohort.

A weakness of this study is that the physicians involved were not blinded to the anatomical results and the surgeons did perform post-operative POPQ measurements follow-ups on their own patients, potentially biasing the results. However, the main limitation of this study is the limited sample size of patients included so far. We are now carrying out a 3-year follow-up study on the efficacy and safety of the SRS device in a larger patient population.

In conclusion, POP repair using the SRS anchorless implant seems a very promising alternative surgical solution for advanced anterior and apical compartment prolapse. A larger sample size and longer follow-up is required to strengthen and confirm our conclusions.

Compliance with ethical standards

Conflicts of interest Gil Levy MD is the inventor of the device and a shareholder in Lyra Medical Ltd. None of the other authors has any financial disclaimer or conflicts of interest.

Funding The research was funded by Lyra Medical Ltd., Makura Farm, Israel.

References

1. Altman D, Vayrynen T, Engh ME, Axelsen S, Falconer C, Nordic Transvaginal Mesh Group. Anterior colporrhaphy versus transvaginal mesh for pelvic-organ prolapse. *N Engl J Med*. 2011;364:1826–36.
2. Maher C, Feiner B, Baessler K, Schmid C. Surgical management of pelvic organ prolapse in women (review). *Cochrane Database Syst Rev*. 2013;4:CD004014.
3. Feiner B, Maher C. Vaginal mesh contraction: definition, clinical presentation, and management. *Obstet Gynecol*. 2010;115(2 Pt 1): 325–30.
4. Margulies RU, Lewicky-Gaupp C, Fenner DE, McGuire EJ, Clemens JQ, Delancey JO. Complications requiring reoperation following vaginal mesh kit procedures for prolapse. *Am J Obstet Gynecol*. 2008;199(6):678.e1–4.
5. Cervigni M, Ercoli A, Levy G. Cadaver study of anchorless implant for the treatment of anterior and apical vaginal wall prolapse. *Eur J Obstet Gynecol Reprod Biol*. 2016;210:173–6.

6. Lowenstein L, Levy G, Chen KO, Ginath S, Condrea A, Padoa A. Validation of Hebrew versions of the Pelvic Floor Distress Inventory, Pelvic Organ Prolapse/Urinary Incontinence Sexual Function Questionnaire, and the Urgency, Severity and Impact Questionnaire. *Female Pelvic Med Reconstr Surg*. 2012;18(6): 329–31.
7. Barber MD, Brubaker L, Nygaard I, Wheeler TL II, Schaffer J, Chen Z, et al. Defining success after surgery for pelvic organ prolapse. *Obstet Gynecol*. 2009;114(3):600–9.
8. Huggele F, Panel L, Farache C, Kashef A, Cornille A, Courtieu C. Two years follow up of 270 patients treated by transvaginal mesh for anterior and/or apical prolapse. *Eur J Obstet Gynecol Reprod Biol*. 2017;208:16–22.
9. Azais H, Charls CJ, Delporte P, Debodinance P. Prolapse repair using the elevate kit: prospective study on 70 patients. *Int Urogynecol J*. 2012;23(10):1421–8.
10. Sayer T, Lim J, Gauld JM, Hinoul P, Jones P, Franco N, et al. Medium-term clinical outcomes following surgical repair for vaginal prolapse with tension-free mesh and vaginal support device. *Int Urogynecol J*. 2012;23(4):487–93.
11. Abed H, Rahn DD, Lowenstein L, Balk EM, Clemons JL, Rogers RG, et al. Incidence and management of graft erosion, wound granulation, and dyspareunia following vaginal prolapse repair with graft materials: a systemic review. *Int Urogynecol J*. 2011;22: 789–98.
12. Maher C, Feiner B, Baessler K, Christmann-Schmid C, Haya N, Marjoribanks J. Transvaginal mesh or grafts compared with native tissue repair for vaginal prolapse. *Cochrane Database Syst Rev*. 2016;2:CD012079.
13. De Tayrac R, Brouziyne M, Priou G, Devoldere G, Marie G, Renaudie J. Transvaginal repair of stage 3-4 cystocele using a lightweight mesh: safety and 36-month outcome. *Int Urogynecol J*. 2015;26(8):1147–54.
14. Milani AL, Heidema WM, van der Vloedt WS, Kluivers KB, Withagen MI, Vierhout ME. Vaginal prolapse repair surgery augmented by ultra-lightweight titanium coated polypropylene mesh. *Eur J Obstet Gynecol Reprod Biol*. 2008;138(2):232–8. doi:[10.1016/j.ejogrb.2007.12.014](https://doi.org/10.1016/j.ejogrb.2007.12.014).
15. Barber MD, Kuchibhatla MN, PieperCF BRC. Psychometric evaluation of 2 comprehensive condition-specific quality of life instruments for women with pelvic floor disorders. *Am J Obstet Gynecol*. 2001;185(6):1388–95.

STUDY PROTOCOL

Open Access



Efficacy of anchoring the four-arm transvaginal mesh to the mid-urethra vs original surgery as a surgical correction for stress urine incontinence in coexisting anterior vaginal prolapse grades II and III: study protocol for a randomized controlled trial

Zoltán Fekete^{1*}  Andrea Surányi¹, Lórand Rénes¹, Gábor Németh^{1†} and Zoltan Kozinszky^{2†}

Abstract

Background: The prevalence of obesity with aging is escalating alarmingly; and pelvic organ prolapse (POP) and stress urinary incontinence (SUI) are now becoming a growing epidemic among the elderly. Synthetic transvaginal mesh has been employed with increasing popularity in the treatment of POP and is usually highly effective in controlling the principal symptoms of prolapse. However, studies have reported that mesh operations provide fairly unfavorable SUI cure rates. Therefore, additional anti-incontinence surgical strategies are increasingly being scrutinized to achieve better postoperative continence without any significant side-effects for patients with both POP and SUI. We hypothesize that the modification with the fixing of the mesh to the mid-urethra is superior to the original transvaginal mesh operation (TVM) with regard to anti-incontinence.

Methods: One hundred and thirty patients diagnosed with POP–Q II–III and concomitant SUI requiring surgical treatment will be included in this prospective, randomized, double-blind, controlled clinical trial. Patients will be randomly allocated to receive either original TVM (TVM group, n = 65) or modified TVM surgery (mTVM group, n = 65). As the primary outcome parameter, we will evaluate the objective SUI and POP cure rates. Secondary endpoints include postoperative morbidity as assessed with the International Urogynaecological Association classification and subjective prolapse and incontinence cure rates reported by questionnaires.

Discussion: Recognizing the importance of an additional surgical procedure for anti-incontinence management, we aim to investigate whether a stabilizing suturing of the mesh to the mid-urethra delivers superior SUI correction compared to the original prosthesis surgery.

Trial registration: ClinicalTrials.gov, NCT02935803. Registered on 20 May 2016.

Keywords: Modified transvaginal mesh, Complications, SUI with POP–Q II–III, IUGA classification

* Correspondence: feket.e.zoltan@med.u-szeged.hu

[†]Equal contributors

¹Division of Urogynaecology, Department of Obstetrics and Gynaecology,
University of Szeged, Semmelweis u. 1., 6725 Szeged, Hungary
Full list of author information is available at the end of the article



© The Author(s). 2017 Open Access This article is distributed under the terms of the Creative Commons Attribution 4.0 International License (<http://creativecommons.org/licenses/by/4.0/>), which permits unrestricted use, distribution, and reproduction in any medium, provided you give appropriate credit to the original author(s) and the source, provide a link to the Creative Commons license, and indicate if changes were made. The Creative Commons Public Domain Dedication waiver (<http://creativecommons.org/publicdomain/zero/1.0/>) applies to the data made available in this article, unless otherwise stated.

Background

Demand for pelvic organ prolapse (POP) and stress urinary incontinence (SUI) surgery is expected to increase due to an expanding rate of obesity among elderly women. POP is defined as the protrusion of the pelvic organs from the normal anatomical location toward or through the vaginal opening; the current prevalence of symptomatic POP is in the range of 3–8% [1, 2]. SUI, classified as involuntary loss of urine during physical activities and a resultant increase in intra-abdominal pressure, is also highly prevalent, reaching as high as 24.8% [3].

Also of note, one-fifth of women in the United States receives surgery either for SUI or for POP [4], where the cumulative risk for SUI surgery is 13.6% and that for POP surgery is 12.6% [4]. Both pathologic conditions develop in > 50% of the women affected [5]. Synthetic transvaginal mesh (TVM) has been increasingly employed in the treatment of POP and tension-free slings are useful in the management of incontinence. Synthetic mesh during repair has principally been used due to higher efficacy compared to that of native tissue repair and resorbable mesh; however, complications appear to be more prevalent [6–9]. Common complications include mesh extrusion, chronic pelvic pain, dyspareunia, and infection [7–10]. The anti-SUI efficacy of the prosthetic placement is barely 72–83% [11–13]; however, it is assumed that a combination of a synthetic mesh with the sling operation [5, 14–16] will substantially increase the cure rate for concomitant SUI.

Despite the increased consideration of the combined surgery for both genitourinary pathologies in one session, there is a lack of consensus on the optimal treatment. It is supposed that a combined operation with mesh and sling is highly effective for the treatment of POP and SUI; however, the complication rate is elevated [5, 14–16].

Therefore, the research group developed a modification to the transobturator four-arm TVM [13, 17] to increase its anti-incontinence effect. While the sling is located beneath the mid-urethra, the TVM elevates the distal part of the anterior vaginal wall [13, 17]. In the original TVM, the posterior part of the mesh is anchored to the anterior aspect of the cervix and the anterior arms are spread under the bladder neck with stabilizing sutures. We hypothesize that the original TVM operation can be followed by residual SUI since the strengthening of the back arms may result in a backward dislocation of the entire mesh. The posterior movement of the mesh allows the dorsal rotation of the urethra since the mid-urethra is not suspended. The proposed modification to the original surgical procedure includes the suture of the anterior part of the mesh to the mid-urethra to prevent the mesh sliding. We think that the appropriate elevation of the mid-urethra would thus occur with the anterior arms and that would achieve a more effective anti-incontinence. The pubourethral ligament is usually loose in SUI, but the anchored mesh would theoretically normalize its function and stabilize the urethra. Intra- and postoperative complication rates would be expected to be similar to those with the original four-arm TVM, but the modified TVM with the anchoring suture would be slightly superior with respect to POP repair and

remarkably more effective in SUI correction. In our preliminary study, the anterior fixing of the TVM to the mid-urethra demonstrates as high an efficacy of anti-incontinence as 96.8% and an enormously reduced recurrence prolapse rate of 3.2% in (unpublished data). The mesh extrusion rate is particularly low and this may be due to the fact that the stabilizing sutures exert a lack of “folding/wrinkling” of the edge of the mesh, preventing a lifting up of the mesh which does not compress the mucosa and derange the periprosthetic vasculature.

A further modification to the TVM surgery is that the positioning of the mesh will occur 1.5 cm below the urethral meatus, leading to an elevation of the entire anterior vaginal wall including the anterior and middle compartments as well. By contrast, the original TVM surgery does not prevent anterior compartment prolapse [13, 17].

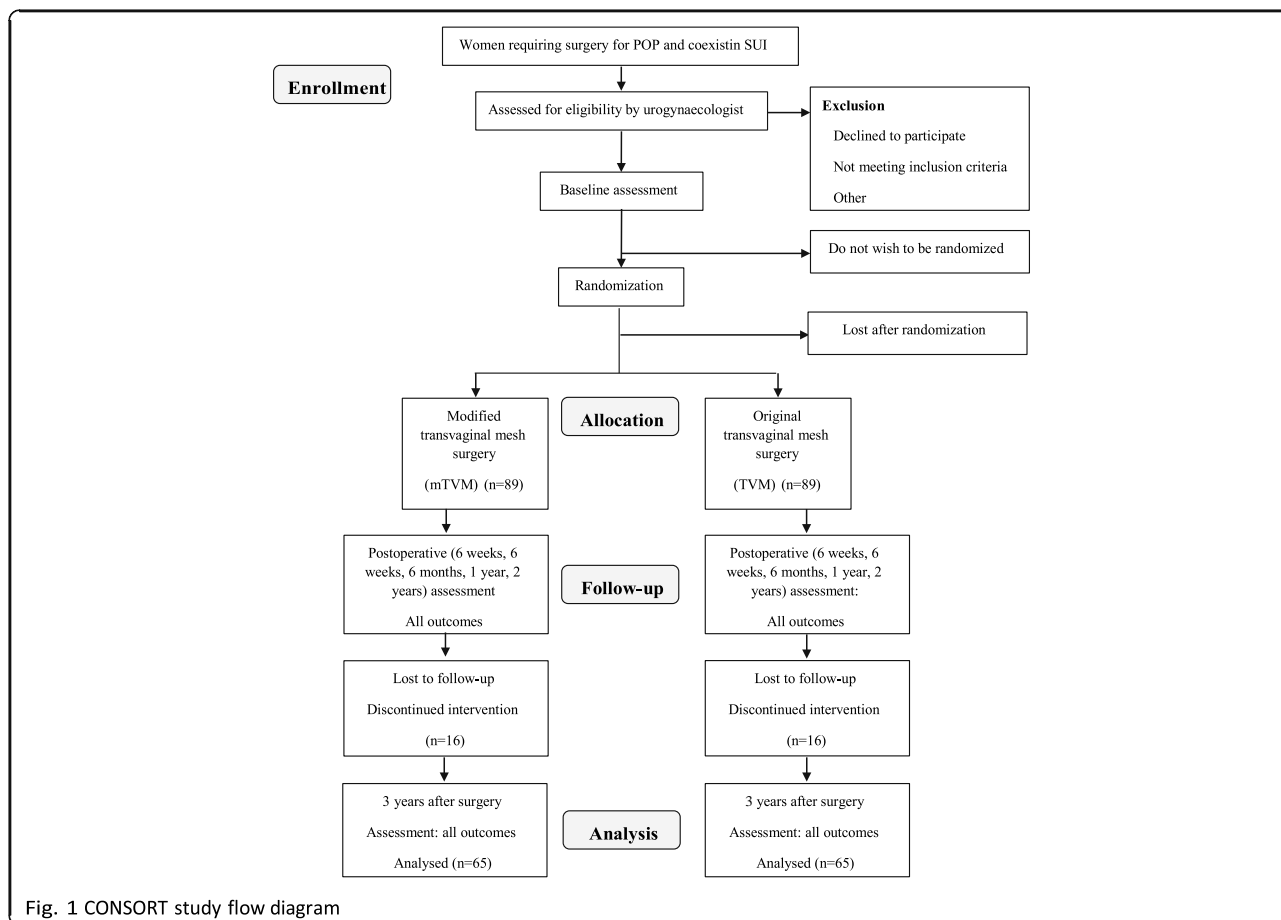
Methods/design

Study design

The present study is a single-center, prospective, doubleblind (participant, investigator/surgeon, outcome assessor), randomized, controlled trial. The study will be conducted in accordance with the Declaration of Helsinki and has been approved by the local medical ethics committee at the University of Szeged under reference number 55/2016. The trial is registered under NCT 02935803, and patient recruitment started on 22 August 2016. The trial flow diagram is presented in Fig. 1 (CONSORT study flow diagram). The protocol follows the Standard Protocol Items: Recommendations for Interventional Trials (SPIRIT) checklist (see Additional file 1).

Patient recruitment and consent procedure

Patients will be recruited from the urogynecology consultation at the Division of Urogynaecology, Department of Obstetrics and Gynaecology, University of Szeged, Hungary. All study participants will be provided an information sheet and a consent form describing the study in brief so they can decide whether to participate in the study. Each participant will be explicitly informed that participation in the study is voluntary, that she may withdraw from the study at any time and that withdrawal of consent will not affect her subsequent medical assistance and treatment.



Consent to publish Written informed consent was obtained from the patients for publication of their individual details and accompanying images in this manuscript. The consent form is held by the authors in the patients' clinical notes and is available for review by the Editor-in-Chief.

Participants considered for trial

This will be a prospective longitudinal study involving all patients successively scheduled for operation for symptomatic prolapse POP–Q grade II or III and coexisting SUI, who will be included in the study after informed consent has been obtained. Patients will be recruited in the Department of Obstetrics and Gynaecology at the University of Szeged. The study will be conducted for an estimated maximum of 18 months (between August 2016 and December 2017). Table 1 provides an overview of the patient recruitment and evaluation plan.

The symptomatic POP–Q Stage II–III (determined by the gynecological examination using the International Continence Society quantification system) [18] anterior vaginal wall prolapse is defined as the maximum extent of the prolapsed anterior and middle compartments being within 1 cm above and 6 cm below the hymen [19, 20]. According to the international POP guidelines (the EBU and NICE guidelines) [21, 22], if the condition disrupts the patient's life and non-surgical treatment options have not helped, it should be treated surgically.

In all cases, SUI will be visualized after a complete physical examination is performed (verified by pad test/ Bonney test/two-dimensional [2D] introital sonography and urodynamic examination). The severity

of SUI was assessed using the Ingelman–Sundberg classification [23]. Urodynamic examinations comprising uroflowmetry, cystometrography, the pressure-flow study, and the abdominal leak point pressure test will be performed before surgery to objectively determine the coexisting symptomatic SUI based on the international guidelines (the EBU and NICE guidelines) [21, 22]. The abdominal leak point pressure test will be used as a standardized examination method for the evaluation of SUI with urine leakage as a sign. If the intra-abdominal pressure recorded at the point of urine leakage was < 40 cmH₂O, the origin of the SUI was set as intrinsic sphincter deficiency (ISD) [24]. In the case of ISD, preoperative pelvic floor training (PFMT) will be recommended. If the patient is unwilling to participate in PFMT or if the

Table 1 Schedule of assessments/data collection

Assessment	Recruitment before intervention phase	Intervention (surgery)	Follow-up				
			6 weeks	6 months	1 years	2 years	3 years
Assessment of eligibility criteria	x						
Written informed consent	x						
Gynecological examination: incontinence symptoms	x	x	x	x	x	x	x
Gynecological examination: prolapse	x	x	x	x	x	x	x
Urodynamic examination	x				x		x
Adverse events		x	x	x	x	x	x
Questionnaires: PISQ-12 and PFDI	x		x	x	x	x	x
Introital sonography	x				x		x
Urine culture	x			x	x	x	x

training was unsuccessful, we will recommend mesh surgery. This will also be the case for suspected urethral hypermobility, i.e. if the intra-abdominal pressure at the point of urine leakage was > 60 cmH₂O.

Introital ultrasound findings

In all cases, introital ultrasound (GE Voluson 730) will be performed with a standardized bladder-filling volume of 300 mL. The vaginal probe (5–9 MHz) will be placed in the area of the vaginal introitus at the level of the external urethral orifice, with the patient in a semi-sitting position. Ultrasound assessment of the bladder and urethra starts in the mid-sagittal plane.

During the sonography, we measure the longitudinal (L) distance between the bladder neck and the line through the lower edge of the pubic symphysis and the horizontal (H) distance between the bladder neck and the upper edge of the symphysis. The two distances are measured at rest (L1, H1), during contraction (L2, H2), on pressing or while coughing (L3, H3). Changes in these parameters during contraction of the levator muscle and on pressing serve to evaluate the reactivity of the pelvic floor

muscles and the adequacy of the supportive structures of the urogenital organs [25]. The funneling of the proximal urethra during coughing as a typical stress urinary sign also will be examined [25].

Inclusion and exclusion criteria

Inclusion criteria

Female adults aged > 40 years with coexisting pelvic floor defects will be recruited, at least one year following delivery, irrespective of parity and pre- or postmenopausal state, medically and physically fit for the measurement and therapeutic surgeries, and, in the case of systemic or local estrogen treatment, stable for the past three months before inclusion.

Exclusion criteria

Exclusion criteria are: urge, mixed incontinence or occult SUI; prolapse < grade II or > grade III POP–Q ([21, 22], <https://uroweb.org/guideline/urinary-incontinence>), apical or posterior compartment prolapse, dysuria (bladder tumor, neurogenic urinary bladder damage), a history of mesh use or anti-incontinence pelvic procedures; pregnancy (urine test to accomplish); lactation period not yet finished; current urinary tract or vaginal infection, menstruation on the day of examination; contraindications for measurements or interventions, for example, acute inflammatory or infectious disease, tumor or fracture; *de novo* systemic or local estrogen treatment (< 3 months); *de novo* drug treatment with anticholinergics or other bladder active substances (tricyclic antidepressants and selective serotonin reuptake inhibitors) and cancer of the pelvic organs.

Concealment of group allocation from participants After the screening phase, patients will be randomly assigned to one of the two therapy groups (the TVM group or modified TVM (mTVM) group). The allocation sequence will be generated by the independent urogynecology secretariat using online randomization software (<http://randomization.com>); allocation ratio = 1:1 (TVM group:mTVM group). The allocation will be concealed in sealed, opaque, sequentially numbered envelopes, which will be stored at the operating theatre. All the women recruited will be numbered consecutively corresponding to the numbered envelopes. The envelope will not be opened until the general narcosis of the study participant has been established. To increase the validity of the trial, the assigned procedure will be blinded for the study participants throughout the follow-up period. The participants will be informed of allocated treatment after completing the study forms 12 months after the procedures. If major complications occur, the study participants and the outcome assessor will be also informed of the allocated treatment at the time of any suspected complication(s).

Randomization

The patients will be randomized to one of the study groups using a computer-generated list. Allocation concealment will be ensured by enclosing assignments in sealed, opaque, sequentially numbered envelopes, which will only be opened when the general narcosis of the study patient has been established [26].

Postoperative outcomes and sequelae will be assessed by an outcome assessor who is a gynecologist in a subspecialization program in urogynecology and also well trained in the transvaginal mesh operation. The outcome assessor will remain blinded to the type of intervention throughout the study.

Blinding

Participants will be blinded against the type of TVM surgery received (original TVM vs mTVM). The participant information document will not provide any information on the differences in surgical protocols such that the women could ascertain their group allocation. All investigators involved in data acquisition, data analyses, and statistics will also be blinded against group allocation. The surgeons in charge of the therapy cannot be blinded against group allocation and therefore will not be involved in data acquisition, data reduction, data analyses, or statistics.

Measurement outcomes

Baseline (before intervention phase) and follow-up measurements (of primary, secondary, and tertiary outcomes) after six weeks to three years will be performed at the Division of Urogynaecology, Department of Obstetrics and Gynaecology, University of Szeged, Hungary, by an experienced urogynecologist who will be blinded to group allocation of participants and who will not operate on the patients (Table 1).

Primary endpoints

The primary outcome measures will be a significant improvement in POP repair and objective cure of SUI after the surgery. The efficacy of POP repair will be understood as a significant (> 3 cm) improvement during follow-up at points Aa, Ba, C, and D using the POP-Q system (International Continence Society) [19, 20]. Antiincontinence efficacy is classified as no further SUI, as diagnosed by cough tests and urodynamic examinations. Besides the gynecological and urodynamic examinations, sonographic findings from introital ultrasound examinations will be analyzed in terms of anatomical success both before and following surgery and during follow-up.

Secondary and tertiary endpoints

The secondary measurement outcome will comprise the intraoperative findings and postoperative factors. As concerns the long-term postoperative complications of the mesh procedures, we will determine the extrusion rate, the presence of *de novo* urge symptoms (DNUS) or urinary tract infection (UTI), and the need for reoperation. The diagnosis of DNUS will be set if detrusor pressure changes are detected in cystometrographic pressures after the surgeries. The postoperative complications that will lead to reoperation will be infection, recurrent descent or incontinence, implant extrusion, chronic pelvic pain, and total retention. Operative and perioperative complications (six weeks after the procedures) described after TVM vs mTVM will be collected; overall frequency within all the cases will be calculated and severity will be graded using the IUGA classification comprising all the follow-up periods [27].

The subjective cure for prolapse and incontinence will be measured with a significant enhancement of the Pelvic Organ Prolapse/Urinary Incontinence Sexual Questionnaire (PISQ-12) and Pelvic Floor Distress Inventory (PFDI) scores. The PISQ-12 and PFDI are validated to assess the impact of SUI symptoms on quality of life and sexuality and relate well to the prolapse symptoms. Previous research has demonstrated that the questionnaires correspond well with grade of prolapse and urodynamic findings [5, 13, 17]. Our research group has assessed the validity of the questionnaires in screening for subjective genitourinary symptoms (unpublished data). To guarantee blinding of the tertiary outcome, the participant will complete the questionnaire without the outcome assessor present and seal it in an envelope, which will be given to research staff. The subjective outcome assessment is largely performed by participant-completed questionnaire, thus avoiding interviewer bias.

Trial interventions

Participants will receive the allocated intervention, either the original TVM operation or mTVM surgery. The surgical interventions will be delivered by two surgeons with expertise in the specific intervention and subspecialized in urogynecology. They will not assess the measurement outcomes. Further details on the interventions are provided below.

Original transobturator four-arm transvaginal mesh Original transvaginal subvesical mesh operations will be performed as described earlier by Sergent et al. [13, 17]. The operative technique is described in detail in another study [28]. The routine surgical technique will consist of a longitudinal incision of the anterior vaginal wall throughout its thickness from 3 cm below the urethral meatus to the cervix. The posterior part of the mesh will be anchored to the anterior side of the cervix using two non-absorbable Prolene® 2-0 sutures (Ethicon, Issy-lesMoulineaux, France), while the mesh will then be spread by securing its anterior parts beneath the bladder neck using two or three Monocryl® 2-0 absorbable sutures (Ethicon, Issy-les-Moulineaux, France). Conventional instruments will be employed for the original TVM procedure.

Modified intervention surgery

In the modified surgical technique, the prosthesis is placed between 1.5 cm below the urethral meatus and the cervix and the anterior part of the mesh is anchored with a stabilizing suture to the periurethral tissue at the level of the mid-urethra to elevate the middle part of the urethra, leading to potentially more effective antiincontinence. An additional document file presents the intervention (detailed description of the mTVM) in detail (see Additional file 2).

Assessment of safety: postoperative complications/ reoperations

In the current study, there are no anticipated risks or inconveniences, as the examinations and intervention employed are well-known and widely used in pelvic floor defect surgery. The modification to the TVM surgery does not carry a higher risk for patients than that of the original TVM in the setting of a fully equipped operation theatre. This makes the immediate detection and treatment of adverse events possible. Also, after leaving the operation room, all patients will be closely monitored for the occurrence of potential (severe) adverse events (short-term postoperative complications) on the postoperative intensive ward. Moreover, the inclusion of each individual patient in the study is indicated in the electronic hospital information system and, hence, is visible to all physicians and nurses involved in the care of the patient. This facilitates the reporting of (severe) adverse events to the principal investigator. The principal investigator will report suspected unexpected serious adverse reactions to the Institutional Review Board.

Statistical methods

Hypothesis

Alternative hypothesis for primary outcome: it is hypothesized that the group undergoing the modified transvaginal mesh operation will have a statistically higher improvement of continence measured by gynecological and urodynamic examination, and from the questionnaire administered before and after the intervention phase.

Sample size calculation

As we have newly developed the modification to the prosthesis surgery, an exploratory pilot study was designed to evaluate the feasibility of the modification to the mesh for the treatment of SUI. Twenty patients with SUI and POP were recruited for a mTVM operation by the same two senior surgeons who are conducting this randomization study. The sample size calculation study was designed based on preliminary data on the 20 patients. The newly developed technique yielded an objective SUI cure rate of 92% as opposed to 72% for the original TVM published by Sergent et al. [13, 17]. Sample size calculations were performed with G*Power software [29], using the statistical model for an χ^2 approach. Consequently, sample size was estimated theoretically and an effect size of $= 0.1$, indicating a small effect, will be accepted. The sample size was calculated for the primary outcome of the SUI cure rate with the following assumptions: $\alpha = 0.05$, power ($1 - \beta$ error probability) $= 0.8$, number of groups $= 2$. Based on these assumptions, a total sample size of $N = 130$ was estimated. In anticipation of dropouts (10%: $n = 16$) or a violation of protocol (10%: $n = 16$), a final sample size of $N = 162$ (81 participants per group) results.

Statistical analyses

Analysis of the patients will follow the CONSORT flow diagram (Fig. 1) through the phases of the study (enrollment [assessed, excluded, randomized], allocation [control group and experimental group with intervention received or not received], follow-up [lost to follow-up, discontinued intervention] and analysis) [30].

All statistical analyses will be conducted using SPSS software version 22 (IBM, Armonk, NY, USA). All tests will be two-sided and significance will be set at $P < 0.05$. Efficacy measurements were adjusted by intention-to-treat analysis. Missing values will be replaced using the last observation carried forward (LOCF) method. No subgroup analyses are planned. Standard deviations, 95% confidence intervals, and median will be used for the descriptive analyses. Primary and secondary outcome analysis: the Chi-square test or Fisher's exact test will be employed to identify any objective outcome differences among groups.

Generally, continuous data will be checked for normality using the Shapiro–Wilk test. If the normality assumption is violated, then PISQ-12 and PFDI scores as tertiary outcomes will be normalized by log transformation ($\log_{10}(x)$). Univariate-repeated measure analysis of variance (ANOVA) will be used to determine the secondary outcome between and within the two groups (mTVM, TVM group) at six endpoints (before intervention and during follow-up clinical appointments 1–5 following intervention). Mixed design ANOVA will be carried out to determine the effects of the modified operation on subjective cure rate for POP and SUI, and the Bonferroni post hoc test will be used to test the difference between means. All statistical analyses will be completed after the final measurement of the last patient during the last clinical appointment after intervention. The repeated measure design with seven points in time allows us to monitor how patients change over time in both short-term (before/during intervention) and longterm situations (before/after intervention).

Discussion

Coexisting POP and SUI are increasingly recognized as a major health and financial concern affecting 63–80% of postmenopausal women [31]. TVM is the standard surgical method for the anatomical restoration of middle compartment Stage II–III prolapse; however, it should be supplemented with a mid-urethral sling to achieve better SUI treatment. Moreover, the combined mesh and sling operations yield

unfavorably more frequent complication rates and may provoke voiding dysfunction and recurrent UTI. Furthermore, following the original TVM, some residual SUI can develop because of the backward dislocation of the mesh.

To the best of our knowledge, the present study is the first to investigate a surgical modification to TVM for more effective anti-incontinence. Should this newly developed modification be proved successful in treating SUI, it could be introduced in clinical practice due to its simplicity.

Additional files

Additional file 1: SPIRIT 2013 checklist: recommended items to address in a clinical trial protocol and related documents. (DOC 127 kb)

Additional file 2: Intervention surgery. (DOC 30 kb)

Abbreviations

ANOVA: Analysis of variance; LOCF: Last observation carried forward; mTVM: Modified transvaginal mesh operation; PFDI: Pelvic Floor Distress Inventory; PFMT: Pelvic floor training; PISQ-12: Pelvic Organ Prolapse/Urinary Incontinence Sexual Questionnaire; POP: Pelvic organ prolapse; POP-Q: Pelvic organ prolapse quantification system; SUI: Stress urinary incontinence; TVM: Transvaginal mesh operation; UTI: Urinary tract infection

Acknowledgements

None

Funding

No funding was received.

Authors' contributions

ZF and AS are responsible for this study. ZF and ZK conceived and developed the study design and drafted and revised the protocol. GN contributed to the study, especially with regard to the development of the therapy protocols, and is responsible for the physiotherapy interventions. AS and ZK are responsible for data acquisition and analyses. ZF and RR hold responsibility for patient recruitment. ZF prepared the manuscript and is the corresponding author. All the authors read and approved the final manuscript.

Competing interests

The authors declare that they have no competing interests.

Publisher's Note

Springer Nature remains neutral with regard to jurisdictional claims in published maps and institutional affiliations.

Author details

¹Division of Urogynaecology, Department of Obstetrics and Gynaecology, University of Szeged, Semmelweis u. 1., 6725 Szeged, Hungary. ²Department of Obstetrics and Gynaecology, Blekinge Hospital, Karlskrona, Sweden.

Received: 16 April 2017 Accepted: 31 October 2017

Published online: 28 December 2017

References

1. Nygaard I, Barber MD, Burgio KL, Kenton K, Meikle S, Schaffer J, et al. Prevalence of symptomatic pelvic floor disorders in US women. *JAMA*. 2008;300:1311–6.
2. Dieter AA, Wilkins MF, Wu JM. Epidemiological trends and future care needs for pelvic floor disorders. *Curr Opin Obstet Gynecol*. 2015;27:380–4.
3. Markland AD, Richter HE, Fwu CW, Eggers P, Kusek JW. Prevalence and trends of urinary incontinence in adults in the United States, 2001 to 2008. *J Urol*. 2011;186:589–93.
4. Wu JM, Matthews CA, Conover MM, Pate V, Jonsson FM. Lifetime risk of stress urinary incontinence or pelvic organ prolapse surgery. *Obstet Gynecol*. 2014;123:1201–6.
5. Takahashi S, Obinata D, Sakuma T, Matsui T, Takenobu Y, Igarashi T, et al. Transvaginal mesh (TVM) reconstruction with TVT/TOT sling for vaginal prolapse concurrent with stressurinary incontinence. *Aktuelle Urol*. 2010;41 Suppl 1:S20–3.
6. Baessler K, Maher CF. Mesh augmentation during pelvic-floor reconstructive surgery: risks and benefits. *Curr Opin Obstet Gynecol*. 2006;18:560–6.
7. Hiltunen R, Nieminen K, Takala T, Heiskanen E, Merikari M, Niemi K, et al. Low-weight polypropylene mesh for anterior vaginal wall prolapse: a randomized controlled trial. *Obstet Gynecol*. 2007;110:455–62.
8. Nguyen JN, Burchette RJ. Outcome after anterior vaginal prolapse repair: a randomized controlled trial. *Obstet Gynecol*. 2008;111:891–8.
9. US Food and Drug Administration. FDA safety communication: update on serious complications associated with transvaginal placement of surgical mesh for pelvic organ prolapse. <http://www.fda.gov/downloads/medicaldevices/safety/alertsandnotices/ucm262760.pdf>. Accessed 13 July 2011.

10. Tunitsky E, Abbott S, Barber MD. Interrater reliability of the International Continence Society and International Urogynecological Association (ICS/IUGA) classification system for mesh-related complications. *Am J Obstet Gynecol*. 2012;206(442):e1–6.
11. Serati M, Sorice P, Bogani G, Braga A, Cantaluppi S, Uccella S, et al. TVT for the treatment of urodynamic stress incontinence: efficacy and adverse effects at 13-year follow-up. *Neurourol Urodyn*. 2015;36:192–7.
12. Nauth MA, Fünfgeld C. Correction of cystocele and stress incontinence with anterior trans obturator mesh. *Eur J Obstet Gynecol Reprod Biol*. 2007;136:249–53.
13. Sergeant F, Sentilhes L, Resch B, Verspyck E, Medeiros R, Descamps P, et al. Treatment of concomitant prolapse and stress urinary incontinence via a transobturator subvesical mesh without independent suburethral tape. *Acta Obstet Gynecol Scand*. 2010;89:223–9.
14. Yonguc T, Bozkurt IH, Sen V, Aydogdu O, Yonguc GN, Gunlusoy B. Double-sling procedure for the surgical management of stress urinary incontinence with concomitant anterior vaginal wall prolapse. *Int Urol Nephrol*. 2015;47:1611–7.
15. van der Ploeg JM, Oude Rengerink K, van der Steen A, van Leeuwen JH, Stekelenburg J, Bongers MY, et al. Transvaginal prolapse repair with or without the addition of a midurethral sling in women with genital prolapse and stress urinary incontinence: a randomised trial. *BJOG*. 2015;122:1022–30.
16. Abbott S, Unger CA, Evans JM, Jallad K, Mishra K, Karram MM, et al. Evaluation and management of complications from synthetic mesh after pelvic reconstructive surgery: a multicenter study. *Am J Obstet Gynecol*. 2014;210:163. e1–8.
17. Sergeant F, Gay-Crosier G, Bisson V, Resch B, Verspyck E, Marpeau L. Ineffectiveness of associating a suburethral tape to a transobturator mesh for cystocele correction on concomitant stress urinary incontinence. *Urology*. 2009;74:765–70.
18. Bump RC, Mattiasson A, Bø K, Brubaker LP, DeLancey JO, Klarskov P, et al. The standardization of terminology of female pelvic organ prolapse and pelvic floor dysfunction. *Am J Obstet Gynecol*. 1996;175:10–7.
19. Persu C, Chapple CR, Cauni V, Gutue S, Geavlete P. Pelvic Organ Prolapse Quantification System (POP-Q) – a new era in pelvic prolapse staging. *J Med Life*. 2011;4:75–81.
20. Reid F. Assessment of pelvic organ prolapse: a practical guide to the pelvic organ prolapse quantification. *Obstet Gynaecol Reprod Med*. 2014;24:170–6.
21. Burkhard FC, Bosch JLHR, Cruz F, Lemack GE, et al. EBU Guideline Urinary incontinence; 2016. <http://uroweb.org/guideline/urinary-incontinence/>.
22. National Institute for Health and Care Excellence. Urinary incontinence in women: management 2015 NICE guidelines [CG171]. London: NICE; 2015. <https://www.nice.org.uk/guidance/cg171>.
23. Ingelman-Sundberg A. Urinary incontinence in women, excluding fistulas. *Acta Obstet Gynecol Scand*. 1952;31:266–91.
24. Majoros A, Hamvas A, Keszthelyi A, Romics I. Value of testing the abdominal leak point pressure in the differential diagnosis of urinary stress incontinence. *Orv Hetilap*. 2003;144:2321–5. Article in Hungarian.
25. Tunn R, Petri E. Introital and transvaginal ultrasound as the main tool in the assessment of urogenital and pelvic floor dysfunction: an imaging panel and practical approach. *Ultrasound Obstet Gynecol*. 2003;22:205–13.
26. Viera AJ, Bangdiwala SI. Eliminating bias in randomized controlled trials: importance of allocation concealment and masking. *Fam Med*. 2007;39:132–7.
27. Haylen BT, Freeman RM, Swift SE, Cosson M, Davila GW, Deprest J, et al. Joint IUGA/ICS Working Group on Complications Terminology. An International Urogynecological Association (IUGA)/International Continence Society (ICS) joint terminology and classification of the complications related directly to the insertion of prostheses (meshes, implants, tapes) and grafts in female pelvic floor surgery. *Neurourol Urodyn*. 2011;30:2–12.
28. de Tayrac R, Brouziyne M, Priou G, Devoldère G, Marie G, Renaudie J. Transvaginal repair of stage III-IV cystocele using a lightweight mesh: safety and 36-month outcome. *Int Urogynecol J*. 2015;26:1147–54.
29. Faul F, Erdfelder E, Lang AG, Buchner A. G*Power 3: A flexible statistical power analysis program for the social, behavioral, and biomedical sciences. *Behav Res Methods*. 2007;39:175–91.
30. Moher D, Hopewell S, Schulz KF, Montori V, Gotzsche PC, Devereaux PJ, et al. i CONSORT 2010 explanation and elaboration: updated guidelines for reporting parallel group randomised trials. *BMJ*. 2010;340:c869.
31. Molander U, Milsom I, Ekelund P, Mellström D. An epidemiological study of urinary incontinence and related urogenital symptoms in elderly women. *Maturitas*. 1990;12:51–60.

Co-author certification

I- **Professor Gil Levy** as corresponding author - hereby certificate that,

Zoltan Fekete was the co-author in our scientific work titled:

"Self-retaining support implant: an anchorless system far the treatment of pelvic organ prolapse-2-year follow-up ".

I also certify that no one utilized or willing to utilize this scientific work in another PhD thesis.

18 April 2018

.....

Date

A handwritten signature in black ink, appearing to read 'Gil Levy', is written over a horizontal dotted line.

Prof. Gil Levy

Corresponding author