NEW APPROACHES IN THE TREATMENT OF PRIMARY CENTRAL NERVOUS SYSTEM TUMORS

Ph.D. Thesis

Petra Mózes, M.D.

Supervisor

Katalin Hideghéty, M.D., Ph.D., habil.

Department of Oncotherapy

Faculty of Medicine, University of Szeged

Doctoral School of Clinical Medicine

Szeged, Hungary

2018

List of full papers that served as the basis of the Ph.D. thesis

I. **Mozes P**, Dittmar JO, Habermehl D, Tonndorf-Martini E, Hideghety K, Dittmar A, Debus J, Combs SE.
Volumetric response of intracranial meningioma after photon or particle irradiation.
Acta Oncol. 2017 Mar;56(3):431-437.
Impact factor: 3,473

II. Daróczi B, Szántó E, Tóth J, Barzó P, Bognár L, Bakó G, Szántó J, **Mózes P**, Hideghéty K.
Post-operative management of primary glioblastoma multiforme in patients over 60 years of age.
Ideggyogy Sz. 2013 Nov 30;66(11-12):391-8.
Impact factor: 0,343

III. **Mozes P**, Hauser P, Hortobágyi T, Benyó G, Peták I, Garami M, Cserháti A, Bartyik K, Bognár L, Nagy Z, Turányi E, Hideghéty K.
Evaluation of the good tumor response of embryonal tumor with abundant neuropil and true rosettes (ETANTR).
J Neurooncol. 2016 Jan;126(1):99-105.
Impact factor: 2,98

IV. **Mozes P**, Szanto E, Tiszlavicz L, Barzo P, Cserhati A, Fodor E, Hideghety K.
Clinical course of central neurocytoma with malignant transformation-an indication for craniospinal irradiation.
Pathol Oncol Res. 2014 Apr;20(2):319-25.
Impact factor: 1,855

List of publications related to the subject of the thesis

I. Duma MN, Oechsner M, Ertl C, **Mozes P**, Reitz S, Borm KJ, Combs SE.
A Prospective study on the need of gated (GAT) radiotherapy in left sided breast cancer patients treated at the Technical University Munich (TUM) The GATTUM Trial: Study Protocol. (under review)
JMIR Preprints. 13/08/2018:11894

II. Rusz O, Pál M, Szilágyi É, Róvó L, Varga Z, Tomisa B, Fábián G, Kovács L, Nagy O, **Mozes P,** Reisz Z, Tiszlavicz L, Deák P, Kahán Zs.
The expression of checkpoint and DNA repair Genes in head and neck cancer as possible predictive factors.
Pathol Oncol Res. 2017 Apr;23(2):253-264.
Impact factor: 1,935

III. Kralj Juric M, Shevtsov M, **Mozes P**, Ogonek J, Crossland RE, Dickinson AM, Greinix H, Mischak-Weissinger E, Holler E, Multhoff G.
B-cell-based and soluble biomarkers in body liquids for predicting acute/chronic graft-versus-host disease after allogeneic hematopoietic stem cell transplantation.
Front Immunol. 2017 Jan 16;7:660.
Impact factor: 5,511

IV. Gunther S, Ostheimer C, Stangl S, Specht HM, **Mozes P**, Jesinghaus H, Vordermark D, Combs SE, Jung MP, Multhoff G.
Correlation of Hsp70 serum levels with gross tumor volume and composition of lymphocyte subpopulations in patients with squamos cell and adeno non-small sell lung cancer.
Front Immunol. 2015 Nov 2;6:556.
Impact factor: 4,165

V. Hideghéty K, Cserháti A, Besenyi Z, Zag L, Gaál S, Együd Z, **Mózes P**, Szántó E, Csenki M, Rusz O, Varga Z, Dobi Á, Maráz A, Pávics L, Lengyel Z.

Role of 18FDG-PET/CT in the management and gross tumor volume definition for radiotherapy of head and neck cancer; single institution experiences based on long-term follow-up.
Magyar Onkol. 2015 Jun;59(2):103-10.
Impact factor: 0,00

VI. Hidehety K, Dobi Á, **Mozes P**, Cserháti A.
Emergency radiotherapy in oncology.
Klinikai Onkológia. 2014 Dec 1. Évf. 4. Szám.
Impact factor: 0,000

VII. Hideghety K, Plangár I, Mán I, Fekete G, Nagy Z, Volford G, Tökés T, Szabó E, Szabó Z, Brinyiczki K, **Mozes P**, Németh I.
Development of a small-animal focal brain irradiation model to study radiation injury and radiation injurry modifiers.
Int J Radiat Biol. 2013 Aug;89(8):645-55.
Impact factor: 1,837

Table of contents

List of abbreviations

BCNU	1,3-bis(2- chloroethyl)-1-nitrosourea
ChT	chemotherapy
CNS	central nervous system
CSF	cerebrospinal fluid
CSI	craniospinal irradiation
CT	computed tomography
CTV	clinical target volume
EBRT	external beam radiotherapy
ETANTR	embryonal tumor with abundant neuropils and true rosettes
ETMR	embryonal tumor with multilayered rosettes
FSRT	fractionated stereotactic radiotherapy
GBM	glioblastoma multiforme
GTR	gross total resection
GTV	gross tumor volume
HIT	Heidelberg Ion Beam Therapy Center
IMRT	intensity modulated radiotherapy
KPS	Karnofsky performance status
MGMT	O^6-methylguanine-DNA-methyltransferase
MIB-1 LI	MIB-1 labeling index
MRI	magnetic resonance imaging
NC	neurocytoma
OAR	organs at risk
OS	overall survival
PFS	progression-free survival
PNET	primitive neuroectodermal tumor
PTV	planning target volume
RBE	relative biological effectiveness
RChT	radiochemotherapy
RT	radiotherapy
SCT	stem cell transplantation
SOBP	spread-out Bragg peak
STR	subtotal resection

TC	tumor control
TMZ	temozolomide
TV	tumor volume
WHO	world health organization

1. Introduction

Primary brain tumors are a diverse group of neoplasms arising from different cell types of the central nervous system (CNS). The annual global age-standardized incidence of primary malignant brain tumors is ~3.7 per 100,000 for males and 2.6 per 100,000 for females. They are the most prevalent solid neoplasms with an incidence of 3.1 in 100,000 children between 0 and 4 years, and the second leading cancer-related cause of death in children younger than 15 years of age. The incidence decreases to 1.8 in 100,000 between 15 and 24 years but it is still the third leading cancer-related cause of death in adolescents and adults between the ages of 15 and 34 years. In adults the incidence rises continuously and reaches a plateau ~17.9 to 18.7 in 100,000 between 65 and 79 years of age [1].

The most common primary brain tumors are (anaplastic) astrocytomas, glioblastomas, meningiomas and other mesenchymal tumors [2].

The diagnosis of intracranial tumor requires radiographic and histopathologic confirmation. A huge variety of diagnostic scans of the complete craniospinal axis can be used e.g. computed tomography (CT), magnetic resonance imaging (MRI), single photon emission CT, positron emission tomography-CT or positron emission tomography-MRI [3].

The treatment of primary brain tumors requires an interdisciplinary team-work. Complete or near-complete tumor resection without serious sequelae could be provided in many cases via craniotomy with sophisticated techniques e.g. neuronavigation. In cases of intrinsic tumors of the deep midline (e.g., pontine or corpus callosum gliomas), of deep tumors of the dominant hemisphere, or of diffuse nonfocal tumors, surgical resection is not achievable and only a stereotactic biopsy could be performed [2].

External beam radiation therapy (EBRT) plays a central role in the primary or adjuvant treatment of primary brain tumors independently from histology [1,4,5]. It has shown its effect in increasing the local tumor control (TC) and in overall survival (OS) [6]. Developments in radiation oncology allow precise treatment of the target volume, steep dose gradients to surrounding healthy tissues, and sparing of organs at risk (OAR). Different techniques aim to provide the best available selectivity in dose delivery e.g. 3D-conformal radiotherapy (RT), intensity-modulated radiotherapy (IMRT), fractionated stereotactic radiotherapy (FSRT) or radiosurgery. Special challenge for radiation oncology is the homogeneous irradiation of the entire craniospinal axis (CSI) in the management of brain tumors with high capability of spreading via the craniospinal fluid (CSF) e.g.

medulloblastoma, primitive neuroectodermal tumor (PNET) of the CNS, embryonal tumor with multilayered rosettes (ETMR) or atypical neurocytoma (NC) [7].

Charged particle therapy with protons or carbon ions shows benefits over the best photon techniques due to its unique physical and biological properties. A very low dose deposition takes place in the entry channel of the particle beam, and as particles slow down with depth, dose deposition with its maximum occurs at the end of the track in the so-called Bragg peak. The range of the peaks is shifted to generate an appropriately sized treatment field, the so called spread-out Bragg peak (SOBP). The normal tissue thereafter can be spared with its steep dose fall-off behind the target volume. Technological developments allow even higher accuracy in dose delivery, such as raster scanning technique or intensity modulated proton therapy. Particles with high linear energy transfer provide a higher relative biological effectiveness (RBE) because they cause a dense ionization in the target volume [8]. The RBE value of proton beam therapy is 1.1 relative to high-energy photons, used in the clinic. However, recent studies have shown that the RBE values of protons can be different at different positions of the SOBP, differing from 1.46 to 2.3, increasing with the depht [9]. RBE value of carbon ions is even higher, approximately 2-5.

Further optimization additionally to the development of different ionizing radiation qualities and more precise dose delivery techniques with the addition of radiosensitizing agents to RT can lead to enhanced tumor cell damage. Chemotherapy (ChT) can be combined with RT (simultaneously or adjuvant) aiming to increase local control and OS rates. However, it is a challenging approach for brain tumors because only a few agents can enter the blood-brain barrier and achieve an effective concentration in the tumor tissue in the CNS [10]. Procarbazine in combination with lomustine and vincristine (PCV) and the alkylating agent temozolomide (TMZ) showed good biological effectiveness and significant benefits in TC [11,12]. Concomitant to RT and adjuvant TMZ became a part of the standard therapy in high grade glial tumors. It resulted in a clinically meaningful and statistically significant survival advantage with minimal additional toxicity [11].

In the recent years standard, evidence-based therapy protocols had been defined and updated on the basis of subgrouping the brain tumors according to their molecular characteristics (isocitrate dehydrogenase (IDH)-mutation, ATRX-mutation, 1p19q-codeletion for glial tumors, methylation status of O^6-methylguanine-DNA-methyltransferase (MGMT) for glioblastoma multiforme (GBM), wingless (WNT) and sonic hedgehog (SHH)-mutation for medulloblastoma, LIN28A and C19MC for ETMR) [13]. However no clinical evidence could be drawn for rare CNS tumor entities for special age groups such as elderly or young

patients, and for the emerging radiation modalities, which require a clinical establishment in the frame of randomized clinical investigations.

Meninigiomas are usually slow-growing, well-circumscribed and benign tumors deriving from arachnoidal cells. They are the most common primary non-glial brain tumors in adults and account for 15–30% of all intracranial neoplasms [14,15]. Despite their generally benign character, they are often neighboring or infiltrating critical neurovascular structures and their growth can cause neurological or neurocognitive deficits leading to a significant worsening in quality of life. Gross total resection (GTR) provides long-term recurrence-free survival in many cases [16,17]. If only subtotal resection (STR) is the only available choice and for recurrent meningiomas, or in cases of grade II tumors, adjuvant RT should be considered. In cases of anaplastic meningiomas RT should be always a part of the therapy [18,19]. Beside surgical resection highly conformal RT has also become a primary treatment alternative over the last decades. Due to improvements in treatment planning and technical application of high precision photon RT, FSRT and IMRT have been well established. These techniques showed convincing local control (75–100%) and very low side effect rates [20,21]. In the case of non-diffuse infiltrating well circumscribed meningioma in critical location with close vicinity of radiosensitive structures such as optic nerve, chiasma, brainstem, the most selective therapeutic modality, charged particle therapy could be applied.

GBM is a malignant primary brain tumor and it accounts 12-15% of all intracranial neoplasms in adults. Usual histological features are coagulation necrosis or microvascular proliferation with thickened vascular walls due to endothelial cell hyperplasia [22]. Important prognostic factors are the co-deletion of 1p19q, MGMT promoter methylation and IDH mutation. GBM is associated with a median OS of only 15 months among patients treated with at least surgical resection and radiotherapy [23,24]. Age is a significant risk factor for GBM, and the incidence of GBM is increasing along with the aging of the general population [25]. Although survival rates have been improving in the recent years, likely a result of the increased use of TMZ concomitant to postoperative RT and/or as adjuvant therapy [23,26]. Further promising modalities may prolong survival by achieving additional anti-tumor effect, e.g. appropriate selection of antiepileptic drugs (e.g. valproate, levetiracetam), second-line therapy using monoclonal antibody against vascular endothelial growth factor (VEGF) bevacizumab alone or in combination with irinotecan, or tumor

treating field (TTF) therapy of high repetition of electric pole change. But these methods have not yet become the defined part of the standard treatment strategy.

Embryonal tumor with abundant neuropils and true rosettes (ETANTR), according to the new world health organization (WHO) classification of primary CNS tumor reclassified as ETMR, is characterized histologically by the presence of undifferentiated neuroepithelial cells, broad bands of well-differentiated neuropil islands, ependymoblastic rosettes [27] and C19MC gene amplification is also characteristic for this tumor entity [28]. It is a rare and highly malignant variant of embryonal brain tumors. It usually affects infants and young children under the age of 4 years and exhibits a very aggressive course with a dismal prognosis.

NC, which accounts for only 0.1–0.5 % of all brain neoplasms [29], displays a slow and benign clinical course with a low recurrence rate and a low tendency to spread. It has the properties of bipotential precursor cells, which can exhibit both glial and neuronal differentiation [30]. Immunohistochemical studies have identified markers of neuronal differentiation such as neuron-specific enolase and synaptophysin [31]. It mostly arises from the septum pellucidum, fornix or walls of the lateral ventricles, with relatively frequent extension to the lateral and third ventricles, often causing obstructive hydrocephalus. The lesions are mostly located in the midline supratentorially. It develops mainly in young adults around the third decade of life [29] (ranging from childhood to 70 years). It has been detected with a higher incidence in Asian populations, than among Caucasians. GTR ensures high progression-free survival (PFS) and OS rates without recurrence [32]. On the basis of the histological findings, such as nuclear atypia, anaplasia, vascular endothelial proliferation, focal necrosis, and/or an increased mitotic index [32,33] a subgroup of this tumor entity is defined as atypical NC. An MIB-1 labeling index (MB-1 LI) of ≥2 % or >3 % has been claimed to be associated with a significantly poorer survival and to correlate with a higher risk of relapse; moreover an MIB-1 LI of >4 % correlates significantly with an unfavorable clinical course [34]. Such a high proliferation index is quite uncommon and the detection of malignant transformation at the time of the diagnosis is extremely rare.

2. Aims

The aim of this thesis was to seek for strategies that can result in improved therapeutic index for different types of primary CNS tumors.
We investigated the feasibility of new therapeutic approaches for particular groups of brain tumor patients and evaluated the treatment outcome. Furthermore, on the basis of own results and comprehensive literature review we developed recommendations in order to enhance the effectiveness of CNS RT for a variety of primary brain tumors by the use of novel radiation qualities, by the introduction of combined treatment approaches, and by special target volume definition.

2.1. The purpose of the assessment of volumetric changes of different grade of meningiomas after treatment with different RBE irradiation was to evaluate the dynamics of tumor response due to different radiation qualities and techniques. We compared the tumor volume (TV) reduction effect of the different radiation qualities retrospectively, i.e.: photons, protons and carbon ions assessed by analysis of serial follow up MRI in patients diagnosed with different grade of meningiomas.

2.2. We aimed to evaluate the tolerance and effectivity of the combined treatment approach in elderly patients to define the clinical benefit and the applicability of the Stupp protocol in this special group of patients with GBM. We conducted a retrospective analysis of patients over 60 years of age diagnosed with GBM who completed a complex treatment of neurosurgery, adjuvant radio(chemotherapy) (RChT) and adjuvant ChT in order to define how this combined treatment is tolerated, and whether it is beneficial in this ageing group, and to search for prognostic factors for quality of life and overall survival.

2.3. In the lack of evidence-based approach we performed a wide literature search on two tumor rarities in the CNS in order to provide the best treatment options. Due to the poor outcome data of ETMR we performed an individual treatment strategy for that patient with long-term success. In the case of NC we followed to recommendations and on the basis of our analysis on the case histories and outcome data and we suggest to change the clinical routine for a special group of patients with NC.

2.3.1. Our aim was to introduce a complex therapeutic approach for childhood ETMR to improve the therapeutic index using novel technical possibilities with higher effectivity and reduced toxicity. We studied and evaluated a novel, combined treatment strategy of CSI followed with tumor bed boost with concomitant ChT and followed by modified metronomic chemotherapy for treatment of a girl with ETMR.

2.3.2. We evaluated different treatment options derived from the literature evaluation in the course of aggressive NC and the effect of the applied therapeutic approaches with the purpose to provide useful suggestions on effective management of this rare disease. We investigated the role of CSI, repeated irradiation in the case of recurrence and combination of RT with ChT in the management of atypical central NC.

3. Patients and methods

3.1. Volumetric response of intracranial meningioma after photon or particle irradiation.

The data of two groups of 77 patients who were suffering from inoperable (not even biopsy was feasible; grade of meningioma is unknown), residual or recurrent meningioma, and treated in two time periods with different radiation modalities, were analyzed and compared retrospectively. Group A consists of 38 patients who were treated at the Heidelberg Ion-Beam Therapy Center (HIT) between September 2010 and January 2012 due to inoperable (10/38), residual (6/38) or recurrent (22/38) meningiomas. Histological WHO grade was unknown in 10/38, grade I in 17/38, grade II in 10/38 and grade III in 1/38 patients. Median age at the time of RT was 52.5 years (range: 32.1–76.8 years). Male to female ratio was 9:29. The tumors were located at the skull base in 31/38, attached to the olfactory tract in 4/38, at the falx in 2/38 or in the orbit in 1/38 patients. Proton RT was delivered to the macroscopic tumor with a safety margin in benign cases (unknown and grade I 27/38) with a median dose of 56 GyE (range 54–58 Gy) in 1.8 or 2 GyE daily fractions. For high grade meningiomas (grade II and III 11/38) a mixed photon/carbon ion scheme according to the MARCIE protocol was used: 50 Gy in 2 Gy daily fractions with IMRT and 18 GyE in 3 GyE daily dose carbon ion boost to the macroscopic tumor [35].

For Group B, 39 patients were selected who had been treated between November 2000 and July 2009, and matched best regarding the clinical parameters (age, gender, tumor volume, etc.). They were irradiated because of inoperable (12/39), residual (10/39), or recurrent (17/39) meningiomas. Histological grade was unknown in 12/39, grade I in 16/39, grade II in 7/39, and grade III in 4/39 patients. Median age at the time of RT was 55.2 years (range 20.6–80.8 years). Male to female ratio was 11:28. Meningiomas were located at the skull base in 25/39, at the convexity in 5/39, in the cavernous sinus in 4/39, at the falx in 2/39, on the optic nerve in 2/39, or at the craniocervical junction in 1/39 patients. IMRT or FSRT was applied with a median dose of 56 Gy (range 39.6–60 Gy) in 1.8 or 2 Gy daily fractions (**Table 1**).

	Proton	IMRT+C^{12} boost	IMRT	FSRT
Patients (n)	27	11	16	23
Gender m:f (n)	4:23	5:6	5:11	6:17
WHO Grade (n)				
unknown	10	--	4	8
I	17	--	7	9
II	--	10	3	4
III	--	1	2	2
Localisation (n)				
Skull base	23	8	13	12
Olfactory tract	3	1		
Falx cerebri	--	2	--	2
Orbita	--	1		
Convexity	--	--	2	3
Cavernous sinus	--	--	--	4
N. opticus	--	--	--	2
Cranio-cervical junction	--	--	1	--
Cause of RT (n)				
Inoperable	10	0	4	8
Residual	3	3	3	7
Recurrent	14	8	9	8
Initial V_{mean} (cm^3)	26,1±22,2	26,5±15,4	37,3±29,5	26,7±23,1
1year V_{mean} (cm^3)	23,5±19,8	20,9±14,4	34,6±28,0	20,5±14,3
Relative TV at 1year (%)	86,4±15,6	77,9±22,0	89,2±24,9	84,0±22,9
2years V_{mean} (cm^3)	24,3±20,7	12,9±10,0	23,5±17,5	13,9±10,0

Relative TV at 2years (%)	86,2±9,2	70,1±23,5	69,4±17,7	77,0±14,6

Table 1. Patient characteristics

Patients were individually affixed with special head masks. For delineation of OARs and gross tumor volume (GTV), a trimodal image fusion of a contrast-enhanced CT scan with 3mm slices, a T1 weighted, contrast-enhanced MRI, and a DOTATOC-positron emission tomography was used. For photon and proton RT, the clinical target volume (CTV) included the GTV as well as a safety margin depending on histology was added as described previously (1–3mm in cases of low grade pathology and 10–20mm in atypical and anaplastic tumors). Anatomical borders were respected. According to the MARCIE trial, a 5mm safety margin was given to the GTV for the carbon ion boost RT. For all patients the planning target volume (PTV) was calculated with an additional margin of 2–3mm in Thermoplast- or 1–2mm in Scotch Cast masks-setup (**Figure 1**).

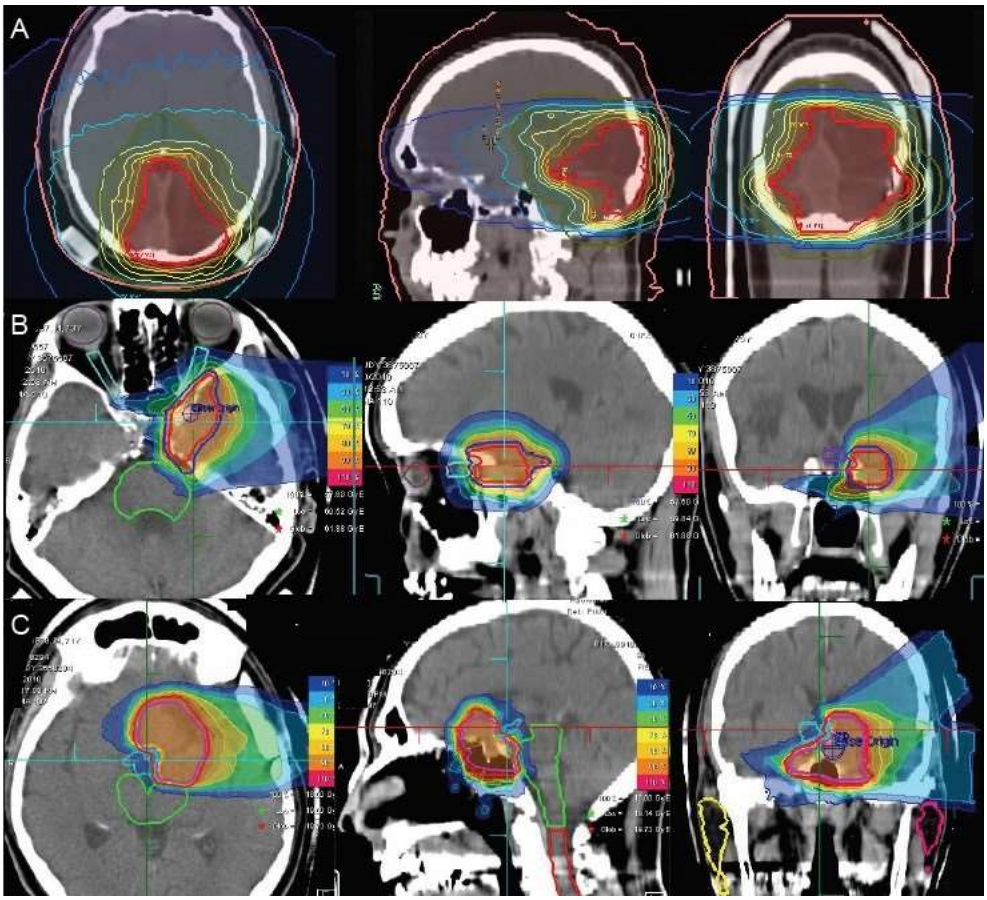

Figure 1. Treatment plans of three patients: IMRT (A), protons (B), and carbon ion boost according to the MARCIE protocol (C).

After RT, patients were enrolled in a continuous and regular in-house standard follow-up program: thorough clinical-neurological examination and contrast-enhanced MRI. The first- and second-year follow-up MRIs were compared to the pre-therapeutic one in each patient to evaluate the volumetric tumor response for this study. Therefore, the GTV was delineated on the initial pre-therapeutic MRI, as well as on the first- and second-year follow-up MRIs using Siemens Dosimetrist (Siemens Medical Solutions, Concord, CA). Afterwards, the three GTVs (pretherapeutic, first- and second-year follow-up) were compared, and TV were calculated in cm^3 (Masterplan Oncentra, Nucletron, Columbia, MD). The statistical analysis was performed with SPSS 20. Paired and two-sampled t-tests, as well as ANOVA tests were done.

3.2. Post-operative management of primary glioblastoma multiforme in patients over 60 years of age.

Records of 75 patients (male:female=34:41) with newly diagnosed and histologically proven GBM who were treated at the University of Debrecen and at the University of Szeged in the period from February 2001 to December 2010, were reviewed retrospectively. Eligible patients were at least 60 years old (median 65.1 years, range: 60-80 years) with histologically confirmed GBM at the time of first diagnosis and were required to have adequate renal, liver, and hematologic functions (**Table 2**).

Characteristics	Patients, n (%) (N=75)
Gender	
Male	34 (45.3)
Female	41 (54.7)
Age, years	
60-64.9	38 (50.7)
65-69.9	21 (28.0)
≥70	16 (21.3)
Post-operative KPS	
<70	23 (30.7)
≥70	44 (58.7)
Unknown	8 (10.7)
Type of surgery	

Biopsy	10 (13.3)
STR	32 (42.7)
GTR	29 (38.7)
Unknown	4 (5.3)
Adjuvant TMZ therapy	
None	33 (44.0)
1-5 cycles	26 (34.7)
6-12 cycles	10 (13.3)
≥12 cycles	6 (8.0)

Table 2. Patient characteristics.

All patients underwent surgery, which was classified by the surgeons as GTR in 29 (38.7%), STR in 32 (42.7 %), and biopsy in 10 (13.3%) patients. The extent of resection could not be determined for 4 patients. Seventy-one patients received standard RT (60 Gy in 30 fractions), three patients received reduced doses of irradiation (48 Gy or 30-33 Gy), and one patient did not receive any radiotherapy. Ten of 74 patients who underwent RT received no ChT. Of the remaining patients, 62 received concomitant and/or adjuvant TMZ therapy, and two patients received adjuvant 1,3-bis(2- chloroethyl)-1-nitrosourea (BCNU) but not TMZ. The patients were divided into three age groups: 60–64, 65–69, and ≥70 years. The study endpoints were OS and PFS. OS time was defined as the time between the date of neurosurgery and the date of death or final follow-up. PFS was defined as the time from the date of neurosurgery to the appearance of the recurrent or progressive tumor or neurologic deterioration. Progressive disease was defined as a ≥20% increase in the size of the tumor (assessed according to Response Evaluation Criteria In Solid Tumors [RECIST]) or by the appearance of a new tumor. Patients with newly diagnosed GBM received surgery followed by RT with or without concomitant and/or adjuvant TMZ. RT was administered as a conventionally fractionated regimen: once daily at 2 Gy per fraction, five days a week, for a total of 60 Gy. Concomitant TMZ was administered at a daily dose of 75 mg/m^2 for 42 consecutive days. Following a four-week rest period, TMZ was administered daily for five consecutive days at a dose of 150–200 mg/m^2 every 28 days. It was delivered at a dose of 150 mg/m^2 during the first cycle. Two patients required dose reductions to 100 mg/m^2 after the first cycle and, in another four patients, the dose was kept at 150 mg/m^2 during all cycles. All other patients receiving adjuvant TMZ were treated with a dose of 200 mg/m^2 after the first cycle. Before

2005, patients underwent various treatment modalities. After 2005, either the Stupp protocol was followed (i.e., patients received six cycles of adjuvant TMZ after concurrent RChT) or adjuvant TMZ therapy was continued until complete response or unequivocal progression was observed. Neuroradiologic imaging was performed every three months, and clinical performance was assessed every four weeks or whenever clinical deterioration occurred. The Kaplan-Meier method was used for survival analysis. Differences between survival curves were assessed by a log-rank test. The following baseline variables were considered for survival analysis: age, gender, postoperative Karnofsky performance score (KPS), type of surgery, tumor burden, reoperation, reirradiation, and tumor localization. For all statistical tests, a value of $p \leq 0.05$ was considered significant. The significance of putative prognostic factors was assessed by univariate and multivariate analyses using the Cox proportional hazards model. Only variables associated with a p value of <0.1 in the univariate model were included in the multivariate analysis. All analyses were conducted using SPSS 15.0 for Windows (IBM Corporation, Armonk, NY, USA) and GraphPad Prism 5, version 5.0 for Windows (GraphPad Software Inc, La Jolla, CA, USA).

3.3.1. The role of chemoradiotherapy in the good tumor response of embryonal tumor with abundant neuropil and true rosettes (ETANTR).

A 2-year-old girl was operated on a lesion with a diameter of 6 cm in the left cerebellum and left occipital lobe. Histopathological examination of the tumor sample revealed the diagnosis of ETMR. There was no evidence of spreading via CSF. She received adjuvant ChT according to the Medulloblastoma 2008 high-risk protocol (vincristine, cyclophosphamide, etoposide, carboplatin intravenously and intrathecal) which was followed by an autologous stem cell transplantation (SCT). 2.5 year later a local recurrence occurred (**Figure 2**) and a reoperation with STR was carried out. Thereafter, she received CSI, with 32 Gy in 1.6 Gy daily fractions followed by RChT comprising tumor bed boost with 24 Gy in 1.6 Gy daily fractions and a residual tumor boost with 6 Gy in 1.5 Gy daily fraction supplemented with 75 mg/m^2 TMZ daily. Modified adjuvant systemic therapy was continued according to the Kieran-Schema (thalidomide, celecoxib, fenofibrate, etoposide and cyclophosphamide was changed to TMZ) [36] for 1.5 years. She is still tumor-free 6 years after the tumor recurrence (**Figure 3**) without major neurocognitive deficits. This individual approach was evaluated

in a broad literature review and with long follow-up, to give advice for optimal treatment strategy in this rare primary brain tumor.

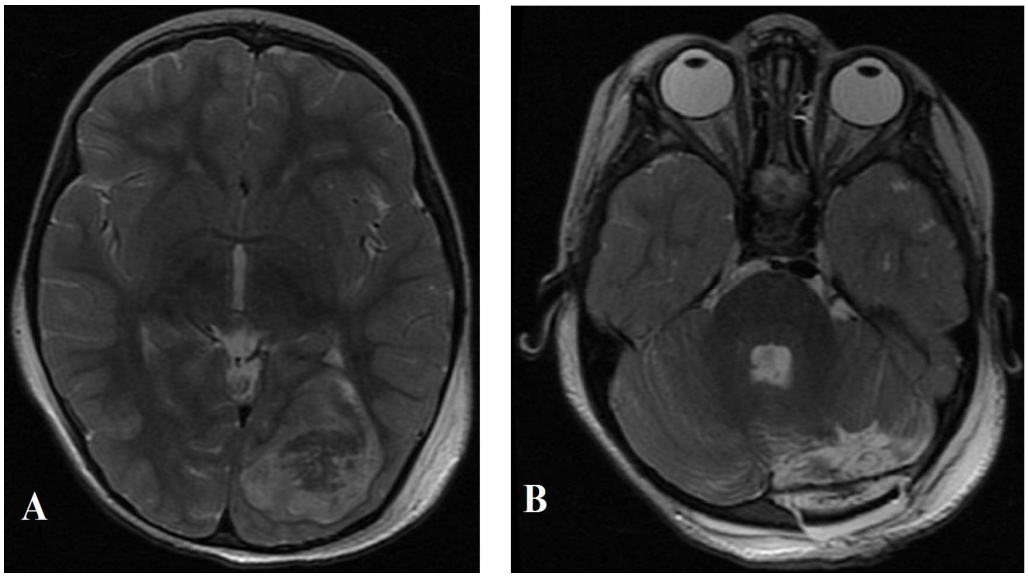

Figure 2. T2 weighted MRI shows the tumor recurrancy in the left occipital lobe (A) and in the postoperative cystic lesion in the left cerebellum and in the tentorium (B).

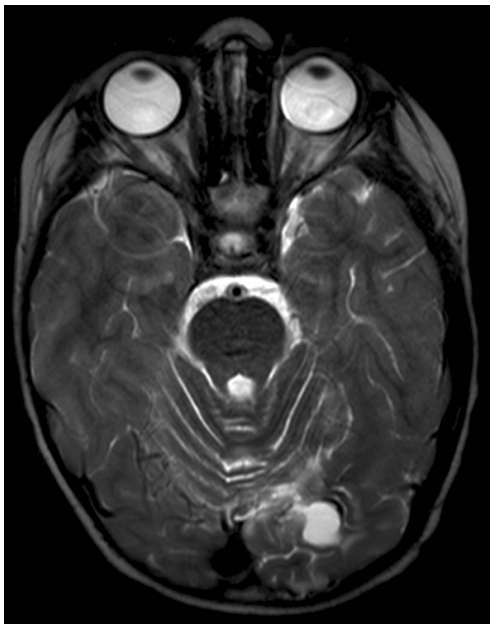

Figure 3. T2 weighted MRI shows the residual left occipital cystic lesion after the second surgery and RChT.

3.3.2. An indication for craniospinal irradiation - clinical course of central neurocytoma with malignant transformation.

A 40-year-old man was operated on a mass at the bottom and in the posterior third of the third ventricle, which constricted the aqueduct and caused an occlusive hydrocephalus. The cytopathological analysis resulted in the diagnosis of a WHO II° central CN with a MIB-1 LI of 25-30%. In the CSF there was no evidence of tumor cells. First postoperative CSI was planned, but after interdisciplinary discussion and literature review, an adjuvant focal 3D-RT was performed with a cumulative dose of 59.4 Gy in 1.8 Gy daily fractions. 3 years later a tumor spread was observed via the CSF along the spinal cord in different locations (**Figure 4**). Via hemilaminectomy, a tumor mass from the thoracic spinal cord was removed. Postoperative, conformal irradiation of the whole spinal cord was performed in a total dose of 36 Gy in 1.8 Gy daily fractions, and a 10 Gy boost with 2 Gy daily dose was delivered to the tumor bed in the thoracic IV–VI region. 6 months later the tumor progressed in the cervical spinal cord. At that time the patient underwent simultaneous RChT with 200 mg/m^2 TMZ five times per week in 28-days cycles and received a reirradiation with a dose of 22.5 Gy in 1.5 Gy daily fractions to the cervical spinal region. The treatment was well tolerated and released a symptom relief and partial remission on MRI. He was then placed on 200 mg/m^2 TMZ monotherapy. 1 year later multiple intracranial tumor recurrence occurred in the left frontal lobe, in the occipital lobes, and in the left cerebellum (**Figure 5**). Reirradiation was carried out to the whole brain in a cumulative dose of 27 Gy in 1.8 Gy daily fractions, with initial tumor bed avoidance, and an additional boost dose of 8 Gy in 1 Gy daily fractions to the macroscopic manifestations. 5 months later the patient died, 62 months after the initial diagnosis.

With a comprehensive literature review, we identified cases of atypical NCs with high MIB-1 LI and we drew attention on the importance and necessity of aggressive combined therapy from the diagnosis of the disease.

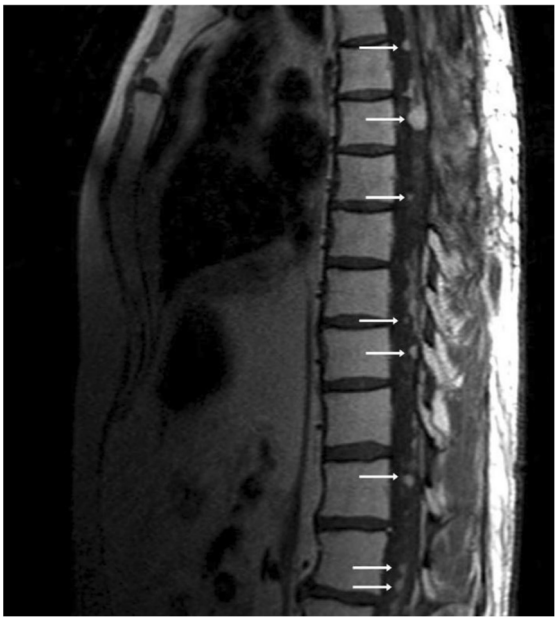

Figure 4. Transversal T1-weighted MRI showing hyperintense, contrast-itradural metastases in the thoracal spinal cord.

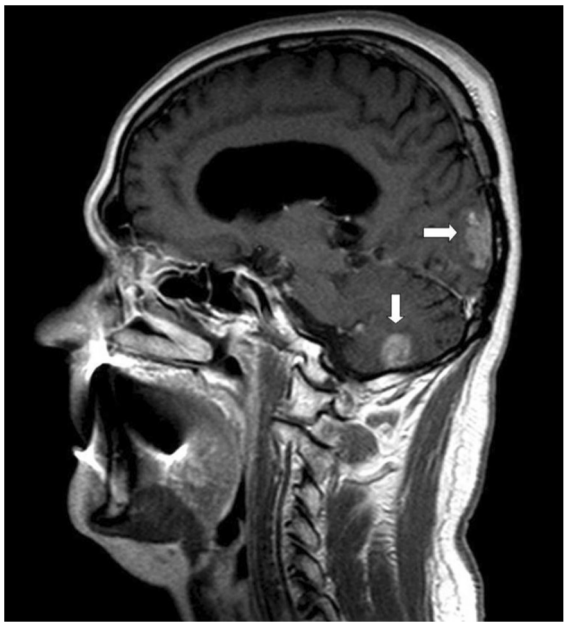

Figure 5. Sagittal T1-weighted MRI showing hyperintense, contrast-enhancing metastases with perifocal edema in the left cerebellum and occipital lobe.

4. Results

4.1. Volumetric response of intracranial meningioma after photon or particle irradiation.

In Group A, 27 patients were treated by proton RT. The mean initial TV was Vmean= 26.1 ± 22.2 cm^3. There was a significant absolute TV shrinkage after one year (Vmean=23.5 ± 19.8 cm^3; Vchange mean=3.7 ± 4.6 cm^3, p=0.001). At the two-year follow-up, a steady state could be observed compared to the volumes after one year (Vmean=24.3 ± 20.7 cm^3). Eleven patients were treated by carbon ion boost combined with IMRT. The mean initial TV was Vmean=26.5 ± 15.4 cm^3. There was a significant absolute TV shrinkage at one-year follow-up (Vmean=20.9± 14.4 cm^3; Vchange mean=5.7 ± 5.6 cm^3, p=0.011). At two-year follow-up, the contrast enhancing volume had decreased (Vmean=12.9 ± 10.0 cm^3), however, this shrinkage was not significant (p=0.083). There was no significant difference in TV changes between combined IMRT plus carbon ion boost and proton-treated patients.

In Group B, 16 patients were treated by IMRT. The mean initial TV was Vmean=37.3 ± 29.5 cm^3. There was a significant absolute TV shrinkage both after one year (Vmean=34.6 ± 28.0 cm^3; Vchange mean=4.3 ± 4.1 cm^3, p=0.003) and at the two-year follow-up (Vmean=23.5 ± 17.5 cm^3; Vchange mean=9.0 ± 5.2 cm^3, p=0.017). There was a significant absolute shrinkage after two years compared to the one-year follow-up as well (Vchange mean=3.4 ± 1.5 cm^3, p=0.020). Twenty-three patients were treated by FSRT. The mean initial TV was Vmean=26.7 ± 23.1 cm^3. There was a significant absolute TV shrinkage both after one year (Vmean=20.5 ± 14.3 cm^3; Vchange mean=7.0±14.7cm^3, p=0.042) and at the two-year follow-up (Vmean=13.9 ± 10.0 cm^3; Vchange mean=4.7±3.9cm^3, p=0.001). There was a significant absolute shrinkage at two-year compared to one-year follow-up as well (Vchange mean=1.3 ± 1.8 cm^3, p=0.038). There was no significant difference in TV changes between IMRT- and FSRT treated patients (**Figure 6**, **Figure 8**, **Table 1**).

A significant absolute TV shrinkage was found in male as well as in female patients. In men (20/77) the mean initial TV was Vmean=40.6 ± 31.4 cm^3, after one year Vmean=34.0 ± 27.4 cm^3 (p=0.018) and after two years Vmean=19.5 ± 13.2 cm^3 (p<0.0001). In women (57/77) the mean initial TV was Vmean=24.5 ± 18.4 cm^3, at one-year follow-up Vmean=21.6 ± 16.4 cm^3 (p<0.001) and two-year follow-up Vmean=17.5 ± 16.2 cm^3 (p<0.0001). Men showed a significantly higher shrinkage after irradiation by both modalities and at both follow-up examinations. In male patients the Vchange mean was 10.1 ± 15.8 cm^3 and 7.8 ± 4.6 cm^3 after one and two years, respectively. In women it was Vchange mean=3.5 ± 4.3 cm^3 and 3.9

± 3.3 cm^3 (Mann-Whitney U-test p=0.028, p=0.022). Therefore, gender was found to be an independent predictive factor for TV change.

In patients with grade III meningioma (5/77, initial Vmean=31.4 ± 21.5 cm^3) we observed significantly higher relative TV shrinkage in comparison to patients with unknown histology (22/77, initial Vmean=22.2 ± 15.1 cm^3) as well as to patients with grade I meningiomas (33/77, initial Vmean=30.0 ± 25.1 cm^3), both at one-year (p=0.045 and p=0.038) and two-year follow-up (p=0.010 and p=0.012). The mean relative size of the residual, contrast enhancing TV was 58.0 ± 22.9% and 52.1 ± 13.5% in the grade III cases after one and two years. In patients with unknown histology, the residual TV was 89.6 ± 19.9% and 81.7 ± 6.6% as well as 89.3 ± 17.3% and 83.0 ± 13.6% in grade I meningiomas, respectively. Patients with grade II meningioma showed a higher tumor shrinkage at the one- and two-year follow-up than patients with unknown or with grade I meningioma, but less tumor volume reduction than grade III. No significance could be detected between the group of grade II meningioma in comparison with the unknown or grade I and grade III tumors (**Figure 7, Table 1**).

Neither age, radiation modality (photon vs. particle), initial TV, nor operability were found to be significant independent predictive factors for volumetric response at the two-year follow-up.

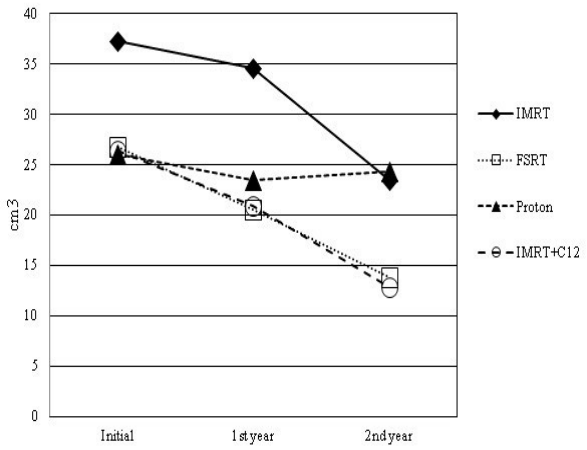

Figure 6. Absolute TV changes according to RT modalities.

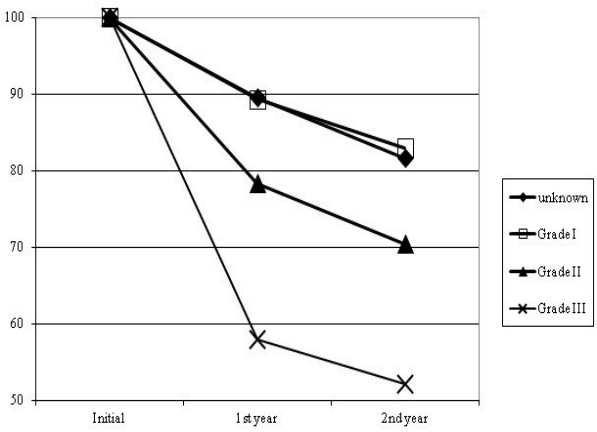

Figure 7. Relative TV changes according to WHO grade.

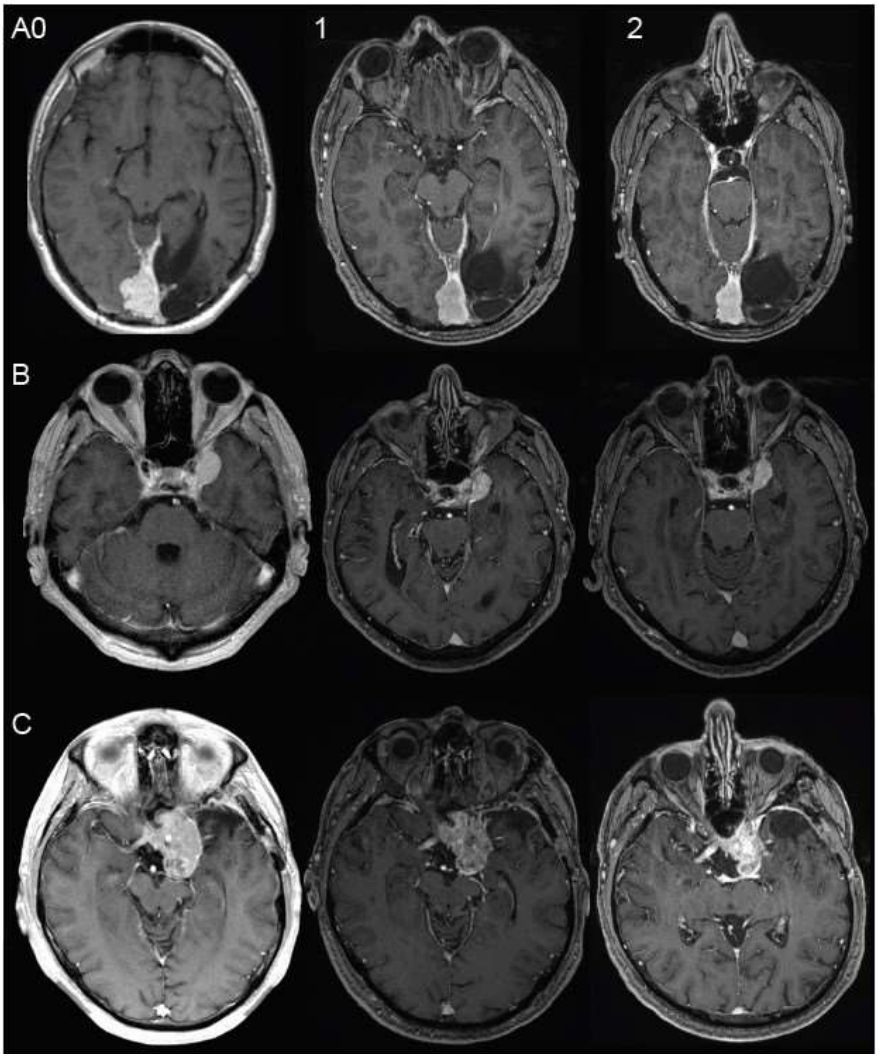

Figure 8. (0) Baseline MRI (for treatment planning) and follow-up MRIs after one (1) and two years (2) after RT by photons (A), protons (B) and after a combined RT by photons and carbon ions according to the MARCIE-protocol (C).

4.2. Post-operative management of primary glioblastoma multiforme in patients over 60 years of age.

After a median follow-up of 10.3 months (range: 2.2–56.2 months), four patients were alive and 71 had died of tumor progression. Treatment-related toxicity led to permanent discontinuation of ChT in five patients; two patients discontinued concomitant, and three discontinued adjuvant TMZ. Concomitant ChT was delivered in 82.7% of patients and no dose reductions were necessary. Of the 75 study participants, 21 underwent some form of salvage therapy because of disease progression after initial treatment. Salvage therapy consisted of surgery (n=13), RT (n=3), surgery plus RT (n=3), or surgery plus adjuvant

BCNU after progression on TMZ (n=2). Most patients with progressive disease received best supportive care only.

For the total study population (n=75), mean OS was 12.9 months and median OS was 10.3 months [95% confidence interval (CI), 8.9–11.7] **(Table 3)**. Median PFS was 4.1 months (95% CI, 3.9–9.3). The 6-month and 12-month OS rates were 73.3% and 42.6%, respectively, with a 2-year OS rate of 6.7%. Median OS was 4.2 months among patients who received concomitant ChT only and 13.8 months among those who received both concomitant and adjuvant ChT. The use and duration of adjuvant TMZ were highly significant prognostic factors of longer OS. Median OS times were significantly longer among patients who received adjuvant TMZ versus the median OS time (4.2 months) associated with concomitant therapy only **(Table 3, Figure 9A)**. Median OS after RT was 6.5 months. Biopsy only compared with gross total resection and KPS <70 were significant negative prognostic factors of OS in both univariate and multivariate analyses. Patients who underwent biopsy with no subsequent partial or total resection had a median OS (4.5 months) that was more than 50% shorter than that of the total study population (10.3 months) **(Table 3)**. The univariate analysis further suggested that additional surgery in patients who experienced disease progression was a significant predictor of longer OS (median OS, 17 vs. 9.2 months for those without salvage surgery, p =0.049). Survival analyses by age suggested no major differences in OS between age groups **(Table 3, Figure 9B)**. The median OS was 10.5 months for patients aged <70 years and 7.7 months for those aged ≥70 years; however, this difference was not statistically significant in univariate analysis (p=0.467). In contrast, age ≥70 years was a negative prognostic factor of PFS in univariate analysis (p=0.0008). The only other negative prognostic factor for PFS was the type of surgery. As for OS, biopsy only (versus total resection) was a negative prognostic factor for PFS in univariate analysis (p<0.0001). Other factors, including gender, KPS, and tumor size, were not found to be prognostic of PFS.

	Overall survival (months)			Progression-free survival (months)		
	N	Median	95% CI	N	Median	95% CI
Total study population						
	75	10.3	8.9–11.7	75	4.1	3.9–9.3
Gender						
Male	34	9.6	7.7–11.5	27	4.0	2.2–5.9
Female	41	10.5	8.2–12.8	28	5.0	3.8–10.8
Age, years						
60–64.9	38	11.0	8.3–13-7	30	4.8	3.9–9.8
65–69.9	21	10.0	7.3–12.7	14	4.2	0.8–10.5
≥70	16	7.7	6.3–9.1	11	2.3	0.3–3.2
Post-operative KPS						
<70	23	6.8	4.0–9.6	18	2.1	0.8–6.1
≥70	44	12.3	8.8–15.8	29	4.5	3.7–10.5
Type of surgery						
Biopsy	10	4.5	0.0–9.2	9	0.6	0.1–1.9
STR	32	10.2	8.8–13.7	18	4.6	2.8–6.9
GTR	29	10.7	9.1–11.9	24	5.0	4.5–12.8
Concomitant therapy only						
TMZ only	20	4.2	3.9–7.4	17	2.6	1.3–3.5
Adjuvant TMZ therapy						
1–5 cycles	26	10.5	8.0–13.0	20	6.0	4.0–13.5
6–12 cycles	10	15.3	10.5–20.1	6	11.0	4.4–16.3
≥12 cycles	6	29.6	21.5–37.7		Insufficient data	

Table 3. Overall and progression-free survival.

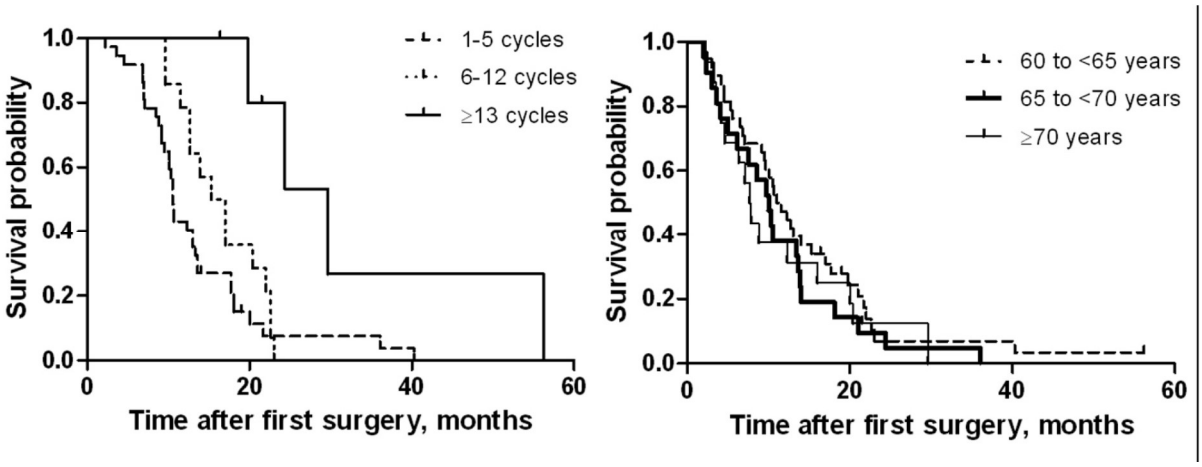

Figure 9. Kaplan-Meier estimates of overall survival by (A) number of cycles of adjuvant TMZ therapy and (B) by age group.

RChT was well tolerated and could be completed without interruption in most patients. TMZ was generally well tolerated. The most common adverse effects among patients who received adjuvant TMZ were fatigue and nausea. Grade III/IV adverse events consisted of grade III thrombocytopenia in 1 patient and grade III fatigue in two patients. Adjuvant TMZ treatment of three patients was discontinued because of thrombocytopenia (n=1), traumatic bone fractures (n=1), or voluntary withdrawal (n=1). Notably, none of the patients who received more than six cycles of adjuvant TMZ showed any toxicity at all.

4.3.1. The role of chemoradiotherapy in the good tumor response of embryonal tumor with abundant neuropil and true rosettes (ETANTR).

The patient treated with ETMR is still tumor free 6 years after the tumor recurrence without major neurocognitive deficits. A substitutional hormone therapy is necessary to ensure mental and physical development.

Our literature review in 2016 indicated 69 reported cases of ETMR, including our case. The mean age at the time of the diagnosis was 25.4 months, range: 3- 57 months. Survival data were available for 48 children (including our case): the median OS was 13.0 months. Patients who underwent STR or GTR had a significant survival benefit in comparison with patients on whom only biopsy could be performed (14 vs. 6 months, p = 0.006), but there were no major differences between the STR and GTR groups. The children, who were irradiated, had a significant survival benefit relative to non-irradiated children (16 vs. 11 months, p = 0.029).

Our literature search revealed 6 (including our case) unusually long survivors (at least 30 months after diagnosis) with ETMR (**Table 4**).

A/G	Loc.	Treatment	Outcome/FU	Ref.
24m/F	L front.	STR→11m RD→STR; IFO, CBDCA, VP-16; SCT	FoD, 30m	[37]
36m/F	L front.	STR; ChT; RT	FoD, 42m	[27]
7m/M	L temp-pariet.	GTR; VCR, CDDP, VP-16, CTX, MTX	FoD, 48m	[38]
48m/M	R pariet.	GTR; CRT: CSI 36 Gy, tb boost: 19,8 Gy with CBDCA, VCR; CDDP, VCR, CTX	FoD, 84m	[39]
48m/M	Pons, mesencephalon	GTR; MTX, VCR, VP-16, CTX, VCR, CDDP; RT: CSI 36 Gy, twice a day 1 Gy/fr, tb boost 30 Gy, twice a day 1 Gy/fr; 8 cycles: CBDCA, VCR, CCNU	FoD, 34m	[40]
24m/F	L cerebellum and occipit.	GTR; VCR, VP-16, CTX, CBDCA, ith: MTX, Ara-C, SCT, BU, VP-16, thiotepa→30m RD →STR; RChT: CSI 32 Gy, tb boost: 30 Gy with TMZ; THD, FF, celecoxib, CTX, BEV; TMZ	FoD, 52m	Present case

Table 4. Reported cases of ETANTR with long-term survival (at least 30 months).

A: age, G: gender, Loc: localization, FU: follow-up, M: male, F: female, L: left, R: right, m: month, ith: intrathecal, Ara-C: cytarabine, BEV: bevacizumab, BU: busulfan, CBDCA: carboplatin, CCNU: lomustine, CDDP: cisplatin, CTX: cyclophosphamide, FF: fenofibrate, IFO: ifosfamide, MTX: methotrexate, THD: thalidomide, TMZ: temozolomide, VCR: vincristine, VP-16: etoposide, GTR: gross total resection, STR: subtotal resection, ChT: chemotherapy, RChT: chemo-radiotherapy, CSI: craniospinal axis irradiation, RT: radiotherapy, SCT: stem cell transplantation, tb: tumor bed, FoD: free of disease, RD: recurrent disease

The mean age at diagnosis among the long survivals was 31.2 months (range 7–48 months). At the time of the report, each of the 6 children was free of disease. They were all operated: 2/6 STR and 4/6 GTR. 1 child who did not receive adjuvant therapy [37] was reoperated 11 months after the first surgery because of tumor recurrence and then received combined ChT followed by SCT. The other 5 children received high-dose ChT in various combinations. RT was applied in 4 cases: hyperfractionated CSI with 36 Gy and a 30 Gy tumor bed boost followed by 8 cycles of carboplatin, vincristine and lomustine [40]; CSI with 36 Gy and a 19.8 Gy tumor bed boost supplemented with concurrent carboplatin and vincristine followed by cisplatin, vincristine, and cyclophosphamide [39] (to date of the literature review he is the longest survivor); and in our case, CSI with 32 Gy and a 30 Gy tumor bed boost RChT supplemented with concomitant TMZ in 75mg/m² daily dose, and thereafter 150 mg/m^2 TMZ monthly up to 1.5 years combined with a modified adjuvant systemic therapy according to the Kieran-Schema (thalidomide, celecoxib, fenofibrate, and etoposide) [36]. The similarities of these cases are that all 6 children were operated after diagnosis, at least STR was performed and combined high-dose ChT was administered for a certain amount of time.

4.3.2. An indication for craniospinal irradiation - clinical course of central neurocytoma with malignant transformation.

Our case presented a high MIB-LI with 25-30% at the time of the initial diagnosis and 3 years after GTR and adjuvant radiotherapy with 60 Gy a tumor recurrence occurred. Salvage surgery, repeated RT courses, and application of TMZ resulted in symptom control and prolonged the survival of the patient with a good quality of life. Our literature review in 2013 resulted in 19 cases, including our case, with an unfavorable clinical course and rapid progression: high rates of local recurrence and craniospinal dissemination prior to the diagnosis or following surgical resection [41-55]. 11 of the 13 patients for whom data were accessible had an initial MIB- 1 LI >2 %. For the group of patients in whom the first tumor recurrence or dissemination occurred within 12 months, a higher mean MIB-1 LI was observed (mean 17.82 %, range 4.4–37.3 %). There was a non-significant tendency toward an unfavorable clinical course if the MIB-1 LI was initially elevated. The same phenomenon was observed for the patients who developed spinal metastases, who exhibited an initial mean MIB-1 LI of 13.4 %. 16/18 patients received adjuvant treatment, i.e. RT ±

chemotherapy. A huge variety of RT techniques (stereotactic radiosurgery=3, conformal RT=12), doses (25–66 Gy) and ChT combinations were used (etoposide, carboplatin, cyclophosphamide, cisplatin, vincristine, cytarabine, ifosfamide, imatinib, TMZ, topotecan, thioTEPA, and nimustine). Four patients received only ChT and two patients did not get any postoperative treatment. The whole craniospinal axis was treated only in the cases with proven manifestation in the spinal cord (n =2). The clinical outcome was available for all cases. The estimated mean survival was 27.9 months (range 5– 46 months). 7 patients died because of tumor dissemination and disease progression. 7 patients were in a stable condition at the time of their last follow-up examination. The mean follow-up period was 32.4 month (range 7–72). 2 patients were in disease progression at their last follow-up 15 and 7 months after the first operation. 2 patients were disease-free 9 and 132 months after the first tumor removal. The estimated mean progression-free survival was 15.3 months, ranging from 2 to 36 months. CSF spreading was detected in 16/18 cases.

5. Discussion

To find new approaches in the treatment of primary CNS tumors we analyzed 2 group of patients with frequent brain malignancies (meningioma and GBM) from special aspects. The group of patients with meningioma was treated with sophisticated irradiation techniques (IMRT, FSRT, proton and carbon ion irradiation) in order to evaluate the best therapeutic radiotherapy options. GBM is still an incurable brain malignancy and we analyzed a group of fragile patients whether they can tolerate and have benefit from standard combined treatment approach.

In the cases of two unique primary and highly malignant CNS tumor types (atypical NC and ETMR) we performed a broad literature review and presented our cases in order to enhance the importance of interdisciplinary teamwork in oncology and to provide evidence for effective treatment strategies.

5.1. Volumetric response of intracranial meningioma after photon or particle irradiation.

This is the first evaluation of the volumetric response of intracranial meningiomas after irradiation by particles and the first analysis comparing the change of TV after different RT modalities. We could show that both high precision photon RT and irradiation by charged particles alone or in combination with photon RT lead to a significant measurable TV reduction in the first and second year after RT. In the patient group where RT was performed with protons, a steady state could be observed between the volumes at one and two years after treatment contoured on the follow-up MRI. Further follow-up might provide more detailed results about volumetric changes. In all but one patient a size reduction of the TV was detected both on the one- and two-year follow-up MRIs. Mean tumor shrinkage of about 25% was measured after two years over all treatment modalities. In patients with inoperable tumors or after STR RT can be considered as a primary or as an adjuvant treatment [14,20]. In grade III tumors adjuvant RT significantly improves PFS and OS even if GTR could be performed [56]. In grade II meningiomas treatment concepts are still controversial. Astner et al. [57] described TV shrinkage by evaluating the initial and follow-up volumetric data of irradiated meningiomas. They measured the TVs of 53 FSRT and six radiosurgery-treated patients. For the FSRT-treated group, the mean follow-up period was 49.5 months (range 11–95 months) and the mean relative size reduction was 25.5% (range 0–69.6%). They

observed significant relative TV shrinkage of 17% after 24, 23% after 24–48, 30% after 48–72 and 26% after more than 72 months, respectively. However, they did not observe any additional reduction after more than 72 months, which might be the effect of a smaller number of available MRIs in further follow-up. A significant TV shrinkage was detected by Henzel et al. as well [58]. They prospectively observed 84 FSRT-treated patients with grade I meningiomas. They found a significant linear reduction of the volumes on every follow-up after 6, 12, 18, 24, and 36 months with 16.6%, 24.5%, 27.9%, 33.2% and 36.0% respectively. Henzel et al. predict a continuous decrease towards a steady state which they still could not describe.

This is the first study that compares the TV shrinkage of meningiomas according to different RT modalities. We could not demonstrate any significant difference in volume reduction depending on the applied radiation quality. IMRT and FSRT were administered with the similar median dose (56 Gy, range 39.6–60 Gy) in 1.8 or 2 Gy daily fractions. These photon techniques have already shown their positive effect on LC, disease-free survival and OS rates without major toxicity [18-21,56,59]. Our delivered equivalent proton irradiation doses were similar to the photon protocols (median 56 GyE; range 54–58 Gy) applied in 1.8 or 2 GyE daily fractions. Carbon ions were applied in a mixed photon/carbon ion scheme according to the MARCIE protocol [35]. Although a carbon ion boost combined with photon irradiation gave the option of dose escalation in the target volume, we could not observe higher TV reduction. Nevertheless, we have to underline the benefits of particle therapy due to dose reduction in the neighboring OARs. As patients suffering from meningiomas have long lifetime expectancy, the avoidance of late side effects such as second malignancies, neurocognitive deficits or vascular events is particularly important [60].

Volumetric tumor regression after RT according to the WHO grade was analyzed. Interestingly, we observed significantly higher TV shrinkage in patients with grade III meningiomas both at one- and two-year follow-up in comparison to grade I meningiomas and the group of patients with the unknown histology (**Figure 7**). The reason could be the increased proliferation and decreased regeneration of anaplastic cells leading to higher radiation sensitivity. On the contrary, higher grade is stated to be a negative prognostic factor in respect of DFS and OS [14,16,19,59].

5.2. Post-operative management of primary glioblastoma multiforme in patients over 60 years of age.

During the time period in which participants of this study were treated, the standard of care for patients with GBM changed substantially. In 2005, TMZ was approved in the US for the treatment of newly diagnosed GBM, based on the results of a phase III study showing that RT plus concomitant and adjuvant TMZ significantly prolonged the survival of patients with newly diagnosed GBM [11]. Consequently, the current standard of care for this patient population includes maximal, safe surgical resection, and subsequent RT with concomitant TMZ followed by six months of adjuvant TMZ. In our study, prolonged adjuvant TMZ therapy was well tolerated, consistent with clinical data suggesting that severe toxicity associated with prolonged use of TMZ is rare [26,61,62].

The role of adjuvant TMZ in elderly patients is still controversial, partly because GBM tends to be less chemosensitive in older patients than in younger ones [25]. However, in our study, adjuvant ChT with TMZ was associated with a significant survival benefit, with a clear trend toward longer survival with increasing cycles of therapy. Notably, despite the relatively small sample size, application of adjuvant TMZ cycles was associated with highly significant prolongation of OS compared with no adjuvant therapy. Most of the patients in our study presented with a good performance status, i.e., a KPS ≥70. Our finding that post-operative KPS ≥70 was a significant predictor of the prolonged OS is consistent with previous reports demonstrating the survival benefit of adjuvant TMZ in elderly patients with GBM [63,64]. Little is known about adjuvant TMZ therapy following RT only. Therefore, it is also a topic for future research.

Roa et al. randomized patients with a minimum age of 60 years and a mean age of 72.4 and 71 years to receive either a 6-week normofractionated or a 3-week hypofractionated regimen. Both groups had a median KPS of 70%. The trial was closed earlier due to the high similarity between the two arms. The trial demonstrated the equal efficacy of both dosing schemes, with a median OS of 5.1 and 5.6 months [65].

Straube et al. analyzed the data of 62 patients with a median age of 69.6 years (range 65.1-85.6 years). Single doses ranged from 1.8 to 3.0 Gy, total doses from 40.05 to 60.0 Gy, mean 52 Gy. All patients received 5 fractions per week. If ChT was administered, patients received 75 mg/m^2 TMZ daily during RT. Adjuvant treatment was started 4 weeks after the end of RChT and consisted of 150 to 200 mg/m^2/day of TMZ in 5 of 28 days (median number of cycles 6). The median OS of the cohort was 10.9 months (range 3.0 to 43.3). The median

PFS was 5.7 months (range 1.2-31.7), which are similar to our results. They found that KPS, MGMT, and extent of resection but not age or the time from surgery to RT were associated with longer survival [66].

In addition, the NOA- 08 prospective Phase III study found that TMZ only was non-inferior to RT in terms of OS in newly diagnosed elderly patients with GBM or malignant astrocytoma (median OS was 8.6 months for TMZ and 9.4 months for RT, p=0.033) [67]. Our findings demonstrated the efficacy and safety of adjuvant and concomitant TMZ and RT in patients aged ≥60 years with GBM with good KPS, thus supporting the results of these studies.

The extent of neurosurgical resection is a known prognostic factor for OS, and available data support the use of standard GTR in elderly patients with good performance status. For example, Vuorinen et al. demonstrated that in patients aged ≥65 years (n=30), OS was significantly longer after craniotomy and tumor resection than after stereotactic biopsy (by a factor of 2.8, p=0.035). Consistent with these findings, in our study, GTR was significantly associated with longer OS and PFS compared with biopsy only [68].

Overall, our results showed that otherwise healthy patients aged ≥60 years with newly diagnosed GBM had a longer OS if they underwent aggressive treatment, including post-operative RChT, and additional surgery and RT upon progression. There was a distinct difference in median OS between patients aged <70 years (10.3 months) and patients aged ≥70 years (7.7 months), and longer OS was only observed among patients aged <65 years; however, age was not identified as a significant predictor of OS. In addition, patients who received six to 12 cycles of adjuvant TMZ had a median OS very similar to that observed in patients aged 18 to 70 years in the randomized phase III trial of TMZ and concomitant RT (15.3 and 14.6 months, respectively) [11]. Furthermore, elderly patients with GBM and good prognostic factors who were treated with RT and concomitant and adjuvant TMZ in a recent clinical study achieved a median OS of 13.7 months [69]. Thus, our findings and those of others strongly suggest that advanced age alone (even older than 70 years) should not preclude the use of aggressive treatment, including surgery and RChT.

It was not possible to perform MGMT methylation status or IDH status, which are known important prognostic factors in GBM. Therefore, the role of these could not be evaluated in our study but is a topic for future research.

5.3.1. The role of chemoradiotherapy in the good tumor response of embryonal tumor with abundant neuropil and true rosettes (ETANTR).

ETMR according to the latest WHO classification of central nervous system tumors belongs to the group of embryonal tumors, like medulloblastoma, PNET, atypical teratoid/rhabdoid tumor or ependymoblastoma [13]. These tumor entities require an aggressive combined treatment strategy, which includes operation (GTR in the best case), polychemotherapy, RT or RChT and SCT in some cases. CSI is an important part of the treatment protocol of such aggressive pediatric tumors [70] and this technique has revealed its benefits in other malignancies with a high tendency to spread along the entire neuroaxis. ETMR most frequently occurs supratentorially (70.3 %) but has been described at all sites in the CNS [38] and metastatic cases have been reported, too [71]. This malignant feature and the very frequently reported poor outcome underline the need for aggressive multimodal therapy, which should include CSI, too. RT is often problematic in the cases of such young children. To avoid major late side-effects (e.g. neurocognitive deficit, intellectual loss, hearing and visual impairment, endocrine dysfunction, asymmetry of the bony and muscular structures, or second malignancies), it is recommended to use the most conformal technique available and delay it as long as possible [72].
The review by Alexiou et al. [38] concluded that children with ETMR who were irradiated had a significant survival benefit relative to non-irradiated children (16 vs. 11 months, $p = 0.029$). The art and dose of applied RT were different in the cases (tumor bed RT only or combined with CSI).

5.3.2. An indication for craniospinal irradiation - clinical course of central neurocytoma with malignant transformation.

MIB-1 is an antibody developed to detect Ki-67, which is a well-known cell proliferation marker. MIB-1 LI is calculated as the percentage of MIB-1–positive nuclei. MIB-1 LI correlates well with the prognosis of different central nervous malignancies [73]. The MIB-1 LI is an important prognostic tool for central NC as well. Imber et al. [74] found that the two year PFS was 48% for MIB-1 LI >4%, and 90% for MIB-1 LI <4%. Similarly, NC with MIB-1 LI <2% had a 10-year survival rate of 90%, compared to MIB-1 LI >2%, which had a 10-year survival rate of 63%.

Because of the rarity of NC cases, no evidence has been accumulated for treatment guideline. GTR provides the best local control and survival rates. Postoperative irradiation is beneficial after STR and for atypical NC cases [75,76]. There are no standard RT recommendations for RT technique (e.g. conformal-RT, FSRT, radiosurgery) and for dosage. Adjuvant focal RT dose can vary between 54-62 Gy [77]. Leenstra et al. [75] likewise concluded that postoperative RT significantly improved the local control rate.

There are still no recommendations about which cases of atypical NC should be treated eventually with up-front CSI or with R(Ch)T after tumor resection. It is known that elevated MIB-1-LI is correlated with poor outcome these cases might need to be selected from other benign cases and should be treated accordingly.

6. Summary and conclusions

6.1. Evaluation of contrast-enhancing tumor size after RT of meningiomas using MRI-based volumetric measurements is a precise method to detect tumor regression. We observed significant TV shrinkage independently of the applied radiation modality.

6.2. Our results demonstrated that RChT after neurosurgery was safe and effective in patients diagnosed with GBM aged ≥60 years. In particular, a significant survival benefit could be observed upon the administration of maintenance TMZ after surgery and RT. Overall, more aggressive antitumor therapy in selected patients with GBM over 60 years of age was associated with longer survival. Our findings suggest that aggressive treatment for GBM should not be withheld from patients solely because of their advanced age.

6.3.1. ETMR exhibits a highly malignant course, but some case reports provide evidence that long-term disease-free survival can be achieved through radical tumor resection, ChT, SCT and RT. CSI is strongly recommended because ETMR shows a high potential of spreading via the cerebrospinal fluid. The application of RChT using advanced RT delivery technique (i.e. simultaneous integrated boost) can result in a survival benefit, and TMZ might be effective in embryonal brain malignancies and well tolerated by young children.

6.3.2. The conclusions drawn from meta-analyses of reports on benign NC cannot be applied in cases with aggressive behavior. NC patients with potential malignant transformation should be differentiated and treated accordingly. Apart from histopathological malignant features, the correct evaluation of the MIB-1 LI can help in the identification of these patients. In that cases multimodal treatment including CSI should be considered.

7. Acknowledgements

First of all I wish to express my special thanks and honor to my supervisor, Katalin Hideghéty, associate professor, whose encouragement, generous support, patience, continuous motivation and scientific guidance helped me in the completion of this work.

I express my gratitude to Professor Zsuzsanna Kahán, director of the Department of Oncotherapy, University of Szeged, who provided excellent working conditions for me at the institute.

I am greatly indebted to Professor Stephanie Combs, director of the Department of RadioOncology, Klinikum rechts der Isar, Technical University Munich, who guided me in the field of particle therapy and supported an important part of my Ph.D. project in the unique Heidelberg Ion-Beam Therapy Center.

I greatly appreciate all the support and work of high standard provided by physicians, technicians, physicists and assistants of the Department of Oncotherapy, University of Szeged and all members of the multidisciplinary neurooncology board that helped this dissertation to be born.

Last but not least, I would like to thank my family, friends and Ph.D. student colleges for encouraging and supporting me.

8. References

1. Adult Central Nervous System Tumors Treatment (PDQ®) Health Professional Version PDQ Adult Treatment Editorial Board. Published online: January 31, 2017.
2. DeVita, Hellman, and Rosenberg's. Cancer: Principles & Practice of Oncology 10th edition 2016(Cancer: Principles & Practice (DeVita)(Single Vol.)) Section 10. Neoplasms of the central nervous system.
3. Gao H, Jiang X. Progress on the diagnosis and evaluation of brain tumors. Cancer Imaging 2013;13:466-81.
4. Perez AC, Brady LW. Principles and Practice of Radiation Oncology 6th edition 2016.
5. NCCN Clinical Practice Guidelines in Oncology. Central Nervous System Cancers. NCCN Evidence Blocks. Version I.2017.
6. Laperriere N, Zuraw L, Cairncross G. Radiotherapy for newly diagnosed malignant glioma in adults: a systematic review. Radiother Oncol. Ireland2002:259-73.
7. Hideghety K, Cserhati A, Nagy Z, et al. A prospective study of supine versus prone positioning and whole-body thermoplastic mask fixation for craniospinal radiotherapy in adult patients. Radiother Oncol. Ireland: 2011 Elsevier Ireland Ltd; 2012:214-8.
8. Combs SE, Schulz-Ertner D, Herfarth KK, Krempien R, Debus J. [Advances in radio-oncology. From precision radiotherapy with photons to ion therapy with protons and carbon ions]. Chirurg 2006;77:1126-32.
9. Britten RA, Nazaryan V, Davis LK, et al. Variations in the RBE for cell killing along the depth-dose profile of a modulated proton therapy beam. Radiat Res 2013;179:21-8.
10. Stewart DJ. A critique of the role of the blood-brain barrier in the chemotherapy of human brain tumors. J Neurooncol 1994;20:121-39.
11. Stupp R, Mason WP, van den Bent MJ, et al. Radiotherapy plus concomitant and adjuvant temozolomide for glioblastoma. N Engl J Med 2005;352:987-96.
12. Brada M, Stenning S, Gabe R, et al. Temozolomide versus procarbazine, lomustine, and vincristine in recurrent high-grade glioma. J Clin Oncol. United States2010:4601-8.

13. Louis DN, Perry A, Reifenberger G, et al. The 2016 World Health Organization Classification of Tumors of the Central Nervous System: a summary. Acta Neuropathol. Germany2016:803-20.
14. Marosi C, Hassler M, Roessler K, et al. Meningioma. Critical Reviews in Oncology Hematology 2008;67:153-71.
15. Bondy M, Ligon BL. Epidemiology and etiology of intracranial meningiomas: A review. Journal of Neuro-Oncology 1996;29:197-205.
16. Beks JWF, Dewindt HL. The recurrence of supratentorial meningiomas after surgery. Acta Neurochirurgica 1988;95:3-5.
17. Demonte F, Smith HK, Almefty O. Outcomome of aggressive removal of cavernous sinus meningiomas. Journal of Neurosurgery 1994;81:245-51.
18. Walcott BP, Nahed BV, Brastianos PK, Loeffler JS. Radiation Treatment for WHO Grade II and III Meningiomas. Frontiers in oncology 2013;3:227.
19. Adeberg S, Hartmann C, Welzel T, et al. Long-Term Outcome After Radiotherapy in Patients With Atypical and Malignant Meningiomas-Clinical Results in 85 Patients Treated in a Single Institution Leading to Optimized Guidelines for Early Radiation Therapy. International Journal of Radiation Oncology Biology Physics 2012;83:859-64.
20. Debus J, Wuendrich M, Pirzkall A, et al. High efficacy of fractionated stereotactic radiotherapy of large base-of-skull meningiomas: Long-term results. Journal of Clinical Oncology 2001;19:3547-53.
21. Combs SE, Adeberg S, Dittmar JO, et al. Skull base meningiomas: Long-term results and patient self-reported outcome in 507 patients treated with fractionated stereotactic radiotherapy (FSRT) or intensity modulated radiotherapy (IMRT). Radiotherapy and Oncology 2013;106:186-91.
22. Cummings TJ, Hulette CM, Bigner SH, Riggins GJ, McLendon RE. Ham56-immunoreactive macrophages in untreated infiltrating gliomas. Arch Pathol Lab Med 2001;125:637-41.
23. Koshy M, Villano JL, Dolecek TA, et al. Improved survival time trends for glioblastoma using the SEER 17 population-based registries. J Neurooncol 2012;107:207-12.
24. Darefsky AS, King JT, Jr., Dubrow R. Adult glioblastoma multiforme survival in the temozolomide era: a population-based analysis of Surveillance, Epidemiology, and End Results registries. Cancer 2012;118:2163-72.

25. Brandes AA, Compostella A, Blatt V, Tosoni A. Glioblastoma in the elderly: current and future trends. Crit Rev Oncol Hematol 2006;60:256-66.
26. Stupp R, Hegi ME, Mason WP, et al. Effects of radiotherapy with concomitant and adjuvant temozolomide versus radiotherapy alone on survival in glioblastoma in a randomised phase III study: 5-year analysis of the EORTC-NCIC trial. Lancet Oncol 2009;10:459-66.
27. Gessi M, Giangaspero F, Lauriola L, et al. Embryonal tumors with abundant neuropil and true rosettes: a distinctive CNS primitive neuroectodermal tumor. Am J Surg Pathol 2009;33:211-7.
28. Kleinman CL, Gerges N, Papillon-Cavanagh S, et al. Fusion of TTYH1 with the C19MC microRNA cluster drives expression of a brain-specific DNMT3B isoform in the embryonal brain tumor ETMR. Nat Genet 2014;46:39-44.
29. Hassoun J, Soylemezoglu F, Gambarelli D, Figarella-Branger D, von Ammon K, Kleihues P. Central neurocytoma: a synopsis of clinical and histological features. Brain Pathol 1993;3:297-306.
30. Kane AJ, Sughrue ME, Rutkowski MJ, Tihan T, Parsa AT. The molecular pathology of central neurocytomas. J Clin Neurosci 2011;18:1-6.
31. Kubota T, Hayashi M, Kawano H, et al. Central neurocytoma: immunohistochemical and ultrastructural study. Acta Neuropathol 1991;81:418-27.
32. Vasiljevic A, Francois P, Loundou A, et al. Prognostic factors in central neurocytomas: a multicenter study of 71 cases. Am J Surg Pathol 2012;36:220-7.
33. Söylemezoglu F, Scheithauer BW, Esteve J, Kleihues P. Atypical central neurocytoma. J Neuropathol Exp Neurol 1997;56:551-6.
34. Rades D, Schild SE, Fehlauer F. Prognostic value of the MIB-1 labeling index for central neurocytomas. Neurology 2004;62:987-9.
35. Combs SE, Edler L, Burkholder I, et al. Treatment of patients with atypical meningiomas Simpson grade 4 and 5 with a carbon ion boost in combination with postoperative photon radiotherapy: The MARCIE Trial. Bmc Cancer 2010;10:8.
36. Robison NJ, Campigotto F, Chi SN, et al. A phase II trial of a multi-agent oral antiangiogenic (metronomic) regimen in children with recurrent or progressive cancer. Pediatr Blood Cancer 2014;61:636-42.
37. Eberhart CG, Brat DJ, Cohen KJ, Burger PC. Pediatric neuroblastic brain tumors containing abundant neuropil and true rosettes. Pediatr Dev Pathol 2000;3:346-52.

38. Alexiou GA, Stefanaki K, Vartholomatos G, Sfakianos G, Prodromou N, Moschovi M. Embryonal tumor with abundant neuropil and true rosettes: a systematic literature review and report of 2 new cases. J Child Neurol 2013;28:1709-15.
39. Manjila S, Ray A, Hu Y, Cai DX, Cohen ML, Cohen AR. Embryonal tumors with abundant neuropil and true rosettes: 2 illustrative cases and a review of the literature. Neurosurg Focus 2011;30:E2.
40. La Spina M, Pizzolitto S, Skrap M, et al. Embryonal tumor with abundant neuropil and true rosettes. A new entity or only variations of a parent neoplasms (PNETs)? This is the dilemma. J Neurooncol 2006;78:317-20.
41. Kulkarni V, Rajshekhar V, Haran RP, Chandi SM. Long-term outcome in patients with central neurocytoma following stereotactic biopsy and radiation therapy. Br J Neurosurg 2002;16:126-32.
42. Coelho Neto M, Ramina R, de Meneses MS, Arruda WO, Milano JB. Peritoneal dissemination from central neurocytoma: case report. Arq Neuropsiquiatr 2003;61:1030-4.
43. Stapleton CJ, Walcott BP, Kahle KT, et al. Diffuse central neurocytoma with craniospinal dissemination. J Clin Neurosci 2012;19:163-6.
44. Amini E, Roffidal T, Lee A, et al. Central neurocytoma responsive to topotecan, ifosfamide, carboplatin. Pediatr Blood Cancer 2008;51:137-40.
45. Elek G, Slowik F, Eross L, Tóth S, Szabó Z, Bálint K. Central neurocytoma with malignant course. Neuronal and glial differentiation and craniospinal dissemination. Pathol Oncol Res 1999;5:155-9.
46. Eng DY, DeMonte F, Ginsberg L, Fuller GN, Jaeckle K. Craniospinal dissemination of central neurocytoma. Report of two cases. J Neurosurg 1997;86:547-52.
47. Brandes AA, Amistà P, Gardiman M, et al. Chemotherapy in patients with recurrent and progressive central neurocytoma. Cancer 2000;88:169-74.
48. Ando K, Ishikura R, Morikawa T, et al. Central neurocytoma with craniospinal dissemination. Magn Reson Med Sci 2002;1:179-82.
49. Tran H, Medina-Flores R, Cerilli LA, et al. Primary disseminated central neurocytoma: cytological and MRI evidence of tumor spread prior to surgery. J Neurooncol 2010;100:291-8.
50. Ogawa Y, Sugawara T, Seki H, Sakuma T. Central neurocytomas with MIB-1 labeling index over 10% showing rapid tumor growth and dissemination. J Neurooncol 2006;79:211-6.

51. Takao H, Nakagawa K, Ohtomo K. Central neurocytoma with craniospinal dissemination. J Neurooncol 2003;61:255-9.
52. Amagasa M, Yuda F, Sato S, Kojima H. Central neurocytoma with remarkably large rosette formation and rapid malignant progression: a clinicopathological follow-up study with autopsy report. Clin Neuropathol 2008;27:252-7.
53. Tomura N, Hirano H, Watanabe O, et al. Central neurocytoma with clinically malignant behavior. AJNR Am J Neuroradiol 1997;18:1175-8.
54. Cook DJ, Christie SD, Macaulay RJ, Rheaume DE, Holness RO. Fourth ventricular neurocytoma: case report and review of the literature. Can J Neurol Sci 2004;31:558-64.
55. Bertalanffy A, Roessler K, Koperek O, Gelpi E, Prayer D, Knosp E. Recurrent central neurocytomas. Cancer 2005;104:135-42.
56. Park HJ, Kang HC, Kim IH, et al. The role of adjuvant radiotherapy in atypical meningioma. Journal of Neuro-Oncology 2013;115:241-7.
57. Astner ST, Theodorou M, Dobrei-Ciuchendea M, et al. Tumor Shrinkage Assessed by Volumetric MRI in the Long-Term Follow-Up after Stereotactic Radiotherapy of Meningiomas. Strahlentherapie Und Onkologie 2010;186:423-9.
58. Henzel M, Gross MW, Hamm K, et al. Significant tumor volume reduction of meningiomas after stereotactic radiotherapy: Results of a prospective multicenter study. Neurosurgery 2006;59:1188-94.
59. Milker-Zabel S, Zabel A, Schulz-Ertner D, Schlegel W, Wannenmacher M, Debus J. Fractionated stereotactic radiotherapy in patients with benign or atypical intracranial meningioma: Long-term experience and prognostic factors. International Journal of Radiation Oncology Biology Physics 2005;61:809-16.
60. Combs SE, Laperriere N, Brada M. Clinical Controversies: Proton Radiation Therapy for Brain and Skull Base Tumors. Seminars in Radiation Oncology 2013;23:120-6.
61. Khasraw M, Bell D, Wheeler H. Long-term use of temozolomide: could you use temozolomide safely for life in gliomas? J Clin Neurosci 2009;16:854-5.
62. Khasraw M, Lassman AB. Advances in the treatment of malignant gliomas. Curr Oncol Rep 2010;12:26-33.
63. Combs SE, Wagner J, Bischof M, et al. Postoperative treatment of primary glioblastoma multiforme with radiation and concomitant temozolomide in elderly patients. Int J Radiat Oncol Biol Phys 2008;70:987-92.

64. Gerstein J, Franz K, Steinbach JP, et al. Postoperative radiotherapy and concomitant temozolomide for elderly patients with glioblastoma. Radiother Oncol 2010;97:382-6.
65. Roa W, Brasher PM, Bauman G, et al. Abbreviated course of radiation therapy in older patients with glioblastoma multiforme: a prospective randomized clinical trial. J Clin Oncol. United States2004:1583-8.
66. Straube C, Scherb H, Gempt J, et al. Does age really matter? Radiotherapy in elderly patients with glioblastoma, the Munich experience. Radiat Oncol 2017;12:77.
67. Wick W, Platten M, Meisner C, et al. Temozolomide chemotherapy alone versus radiotherapy alone for malignant astrocytoma in the elderly: the NOA-08 randomised, phase 3 trial. Lancet Oncol 2012;13:707-15.
68. Vuorinen V, Hinkka S, Farkkila M, Jaaskelainen J. Debulking or biopsy of malignant glioma in elderly people - a randomised study. Acta Neurochir (Wien) 2003;145:5-10.
69. Brandes AA, Franceschi E, Tosoni A, et al. Temozolomide concomitant and adjuvant to radiotherapy in elderly patients with glioblastoma: correlation with MGMT promoter methylation status. Cancer 2009;115:3512-8.
70. Gerber NU, von Hoff K, Resch A, et al. Treatment of children with central nervous system primitive neuroectodermal tumors/pinealoblastomas in the prospective multicentric trial HIT 2000 using hyperfractionated radiation therapy followed by maintenance chemotherapy. Int J Radiat Oncol Biol Phys 2014;89:863-71.
71. Kleinschmidt-DeMasters BK, Boylan A, Capocelli K, Boyer PJ, Foreman NK. Multinodular leptomeningeal metastases from ETANTR contain both small blue cell and maturing neuropil elements. Acta Neuropathol 2011;122:783-5.
72. Hoffman KE, Yock TI. Radiation therapy for pediatric central nervous system tumors. J Child Neurol 2009;24:1387-96.
73. Ho DM, Wong TT, Hsu CY, Ting LT, Chiang H. MIB-1 labeling index in nonpilocytic astrocytoma of childhood: a study of 101 cases. Cancer. United States1998:2459-66.
74. Imber BS, Braunstein SE, Wu FY, et al. Clinical outcome and prognostic factors for central neurocytoma: twenty year institutional experience. J Neurooncol 2016:193-200.

75. Leenstra JL, Rodriguez FJ, Frechette CM, et al. Central neurocytoma: management recommendations based on a 35-year experience. Int J Radiat Oncol Biol Phys 2007;67:1145-54.
76. Lee J, Chang SM, McDermott MW, Parsa AT. Intraventricular neurocytomas. Neurosurg Clin N Am 2003;14:483-508.
77. Rades D, Schild SE, Ikezaki K, Fehlauer F. Defining the optimal dose of radiation after incomplete resection of central neurocytomas. Int J Radiat Oncol Biol Phys 2003;55:373-7.

9. Appendix