

# Evolution of lung segmentectomy at our department

Ph.D. Thesis

**TIBOR GÉCZI MD**

Supervisors:

József Furák MD, PhD

Tamás Zombori MD, PhD



Department of Surgery

Faculty of Medicine

University of Szeged

Szeged

2023

# CONTENTS

LIST OF PAPERS	3
LIST OF ABBREVIATIONS	6
1, INTRODUCTION	7
2, OBJECTIVES	13
3, STUDY I.	14
Changes in the clinicopathological features of surgically treated lung cancer around the millennium	
3,1. Materials and methods I.	14
3,2. Results I.	15
3,3. Discussion I.	19
4, STUDY II.	22
The more the micropapillary pattern in stage I lung adenocarcinoma, the worse the prognosis-a retrospective study on digitalized slides	
4,1. Materials and methods II.	22
4,2. Results II.	24
4,3. Discussion II.	29
5, STUDY III.	35
Near-infrared fluorescence guided surgery: State of the evidence from a health technology assessment perspective	
5,1. Materials and methods III.	35
5,2. Results III.	37
5,3. Discussion III.	38
6, SUMMARY	39
7, ACKNOWLEDGEMENTS	40
8, REFERENCES	42

## List of papers:

### This doctoral thesis is based on the following publications:

I. Géczi, Tibor, Csada, Edit, Tiszlavicz, László, Lázár, György, Furák, József A műtéileg kezelt tüdőrák klinikopatológiai jellemzőinek változása az ezredfordulónkon [Changes in the clinicopathological features of surgically treated lung cancer around the millennium] ORVOSI HETILAP 159 : 10 pp. 391-396. 6 p. (2018) DOI WoS Scopus PubMed Matarka MOB SZTE Publicatio IF:0.564

II. Tamás Zombori, Tibor Nyári, László Tiszlavicz, Regina Pálföldi, Edit Csada, Tibor Géczi, Aurél Otlakán, Balázs Pécsy, Gábor Cserni, József Furák. The more the micropapillary pattern in stage I lung adenocarcinoma, the worse the prognosis-a retrospective study on digitalized slides *Virchows Archives* 472, pages949–958 (2018) DOI: 10.1007/s00428-018-2337-x IF:2.868

III. Tibor Géczi, Zsolt Simonka, Judit Lantos, Melinda Wetzel, Zsolt Szabó, György Lázár, József Furák. Near-infrared fluorescence guided surgery: State of the evidence from a health technology assessment perspective *Front. Surg.* 9:919739. DOI: 10.3389/fsurg.2022.919739 IF:2.568

Total impact factor of original papers directly related to the thesis: 6.0

### List of abstracts related to the subject of the thesis:

Szabo, Zsolt ; Fabo, Csongor ; Oszlanyi, Adam ; Hawchar, Fatime ; Geczi, Tibor ; Lantos, Judit ; Furak, Jozsef Anesthetic (r)evolution from the conventional concept to the minimally invasive techniques in thoracic surgery-narrative review *JOURNAL OF THORACIC DISEASE* 14 : 8 pp. 3045-3060. , 16 p. (2022)

Furák, József ; Németh, Tibor ; Lantos, Judit ; Fabó, Csongor ; Gécsi, Tibor ; Zombori-Tóth, Noémi ; Paróczai, Dóra ; Szántó, Zalán ; Szabó, Zsolt Perioperative Systemic Inflammation in Lung Cancer Surgery FRONTIERS IN SURGERY 9 Paper: 883322 , 7p. (2022)

Furák, József ; Szabó, Zsolt ; Theodor, Horváth ; Gécsi, Tibor ; Pécsy, Balázs ; Németh, Tibor ; Ottlakán, Aurél ; Molnár, Zsolt ; Lázár, György Nem intubált, spontán légző betegnél, egy metszésből, minimálisan invazív módon elvégzett tüdőlebeny-eltávolítás mint új műtéti eljárás klinikánk gyakorlatában [Non-intubated, uniportal, video assisted thoracic surgery (VATS) lobectomy, as a new procedure in our department] MAGYAR SEBÉSZET 70 : 2 pp. 113-117. , 5 p. (2017)

Furak, J ; Pecsy, B ; Ottlakan, A ; Nemeth, T ; Geczi, T ; Tizslavicz, L ; Lakatos, A ; Lazar, G Minimálisan invazív tüdőlebeny-eltávolítás eredményei osztályunk öt éves anyagában [Results of the video-assisted thoracic surgery lobectomy at our department in the last five-year periode] MAGYAR SEBÉSZET 69 : 3 pp. 100-104. , 5 p. (2016)

Furák, József ; Gécsi, Tibor ; Pécsy, Balázs ; Morvay, Zita Szükséges-e a naponkénti rutinmellkasröntgen tüdőresectio után?: bizonyítékalapú döntési taktika MAGYAR SEBÉSZET 67 : 4 pp. 252-255 , 4p. (2014)

Geczi, T ; Furak, J ; Sztancsik, Z ; Vincze, A ; Tizslavicz, L ; Lazar, G Bal főhörgő-bifurcatio resectiója és anatómiai segmentectomia kettős granularis sejtes daganat miatt [Bifurcation resection of the left mainstem bronchus and segmentectomy for double granular cell tumors]: [esetismertetés] MAGYAR SEBÉSZET 62 : 5 pp. 304-307. , 4 p. (2009)

## **Publications not directly related to the thesis:**

Németh, Tibor ; Pécsy, Balázs ; Gécsi, Tibor ; Sas, Katalin ; Szpisjak, László ; Rieth, Anna ; Kiss, Valéria ; Szőnyegi, Ferenc ; Tizslavicz, László ; Zombori, Tamás et al. Tetraplegia sikeres multidiszciplináris kezelése mellkassebészeti műtéttel. Unicentrikus mediastinalis Castleman-betegség esete [Successful multidisciplinary management of tetraplegia with a thoracic operation. Unicentric, mediastinal Castleman disease]: esetismertetés ORVOSI HETILAP 161 : 1 pp 33-38. , 6p. (2020)

Ottlakan, A ; Geczi, T ; Pecsy, B ; Borda, B ; Lantos, J ; Lazar, G ; Tizslavicz, L ; Klivenyi, P ; Furak, J Myasthenia gravis miatt végzett három különböző típusú csecsemőmirigy-eltávolítás sebészeti és korai neurológiai eredményei [Three different types of thymectomy for myasthenia gravis: Surgical and early neurological results] MAGYAR SEBÉSZET 68 : 6 pp. 219-224. , 6 p. (2015)

Németh, Tibor ; Gécsi, Tibor ; Tizslavicz, László ; Wolfárd, Antal ; Lázár, György ; Furák, József Óriás gátori fibrolipoma mint ritka gátori daganat műtéti eltávolítása: [esetismertetés] MAGYAR SEBÉSZET 64 : 5 pp. 235-238. . 4p. (2011)

Furak, J ; Geczi, T ; Tizslavicz, L ; Lazar, G Postoperative paraplegia after resection of a giant posterior mediastinal tumour. Importance of the blood supply in the upper spinal cord: [case

report] INTERACTIVE CARDIOVASCULAR AND THORACIC SURGERY 12 :5 pp. 855-856. , 2p. (2011)

Géczi, T ; Paszt, A ; Simonka, Z ; Furák, J ; Lázár, G Ritka szövődmény nyelőcső-resectiót követően: a csőgyomor korai pepticus fekélyének perforatiója: [esetismertetés] MAGYAR SEBÉSZET 64 : 5 pp. 239-241. , 3 p. (2011)

Furak, J ; Geczi, T ; Wolfard, A ; Lantos, J ; Lazar, G Videothoracoscopos módon, a jobb mellüreg felől elvégzett csecsemőmirigy-eltávolítás - új műtéti eljárás klinikánk gyakorlatában MAGYAR SEBÉSZET 64 : 4 pp. 202-206. , 5 p. (2011)

Nemeth, T ; Furak, J ; Wolfard, A ; Geczi, T ; Tiszlavicz, L ; Lazar, G A mellhártya elsődleges daganatainak sebészi kezelése osztályunk anyagában MAGYAR SEBÉSZET 63 : 2 pp. 67-74. , 8 p. (2010)

## List of abbreviations:

CT	Computer Tomography
COVID	COronaVirus Induced Disease
TNM	Tumor Node Metastasis
OS	Overall Survival
DFS	Disease-Free Survival
VATS	Video-Assisted Thoracic Surgery
NIR	Near-InfraRed
ICG	IndoCyanine Green
FDA	Food and Drug Administration
PET-CT	Positron Emission Tomography- CT
ACOSOG	American College of Surgeons Oncology Group
NSCLC	Non-Small Cell Lung Cancer
FEV1	Forced Expiratory Volume in 1 second
DLCO	Diffusing Capacity for Carbon Monoxide
GGO	Ground Glass Opacity
TTF-1	Thyroid Transcription Factor 1
KRAS	Kirsten RAAt Sarcoma virus (oncogene)
EGFR	Epidermal Growth FactorR
WHO	World Health Organization
IASLC	International Association for the Study of Lung Cancer
ATS	American Thoracic Society
ERS	European Respiratory Society
STAS	Spread Through Air Spaces
NITS	Non-Intubated Thoracic Surgery

# 1. Introduction

Cancer-related mortality is on the second place following cardiovascular mortality in developed countries. Lung cancer is the most common malignant tumor among men, while it is on the third place after breast and colorectal malignancies among women. Every year 2.1 million new lung cancer cases and 1.8 million lung cancer-related deaths are estimated worldwide, so lung cancer is the most frequently diagnosed cancer and the most common cause of cancer-related death (Fig.1)(1). According to the data of the Hungarian National Cancer Registry, there were 6341 men and 4959 women diagnosed with lung cancer in Hungary in 2019 (Fig.2)(2). Smoking plays significant role in the development of lung cancer, 80-85% of lung cancer patients have more than 5 years of smoking history, and at the same time it is proved, that passive smoking is also carcinogen, this effect depends on the time and severity of smoke exposure (3).

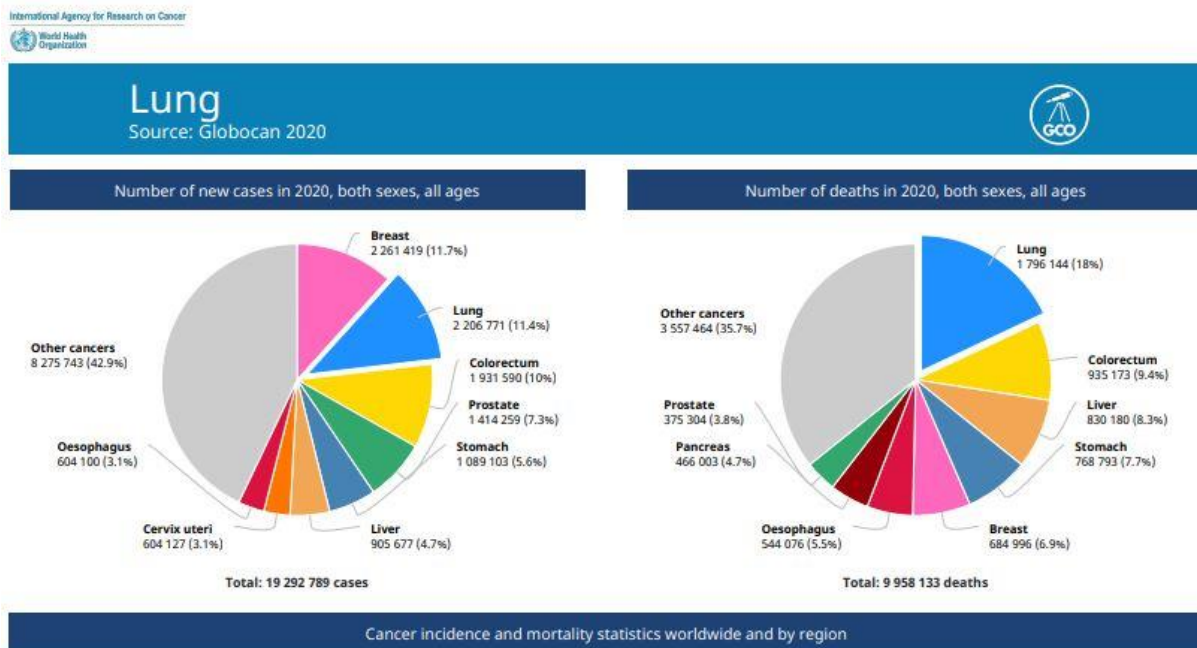


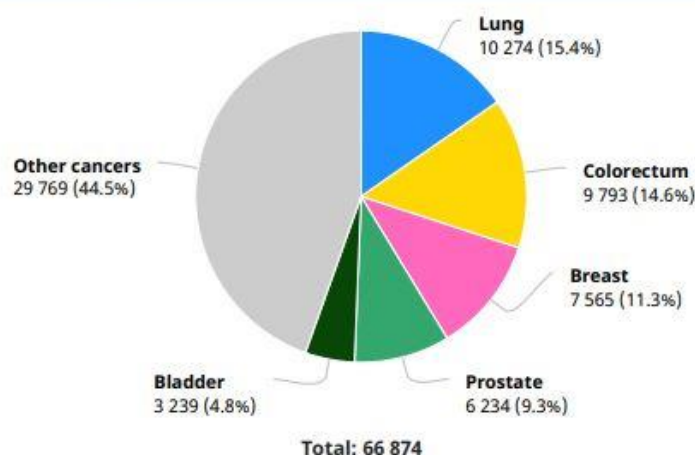
Fig.1.: New cancer cases and cancer-related deaths in 2020.

<https://gco.iarc.fr/today/data/factsheets/cancers/15-Lung-fact-sheet.pdf>

# Hungary

Source: Globocan 2020

Number of new cases in 2020, both sexes, all ages



Number of new cases in 2020, males, all ages

Fig.2.: Types of diagnosed cancers in Hungary in 2020

<https://gco.iarc.fr/today/data/factsheets/populations/348-hungary-fact-sheets.pdf>

By seeing the fact, that lung cancer is the leading cause of cancer-related death, it is clear that screening, diagnosis and the treatment of lung cancer is far away from being good, in spite of the development in the field of radiology, pulmonology, surgery and oncology over the last few decades. According to the current data, the screening rate by chest X-ray of the hungarian population was around 25%. Thanks to this fact and the frequently poor functional status, only 30% of these patients are candidates for radical lung surgery, although this is the only one curative treatment method, even if adjuvant therapy might be indicated (4).

Our world is continuously changing. By the efforts of the governments of developed countries, smoking has been pushed back a bit, therefore the increase of lung cancer incidence looks like to be stopped rising, but this process also lead to the decrease of squamous cell carcinomas and the increase of adenocarcinomas, with the advantages and disadvantages of this change. At the same time, attention is paid on different screening programmes, so much more early stage lung cancers are diagnosed than earlier. In Hungary, the Hunchest programme has been introduced providing effective screening with low dose chest CT for the endangered



population, for smoking people being over 50 years (5). Furthermore, the widespread use of CT in the investigation of patients with different type of chest problems, in the use of follow-up after any type cancer therapy leads to much more newly discovered solitary pulmonary nodule, providing more chance for lung cancer therapy and more difficulty in differential diagnosis. This process has been recently amplified by the latest big human catastrophe, the COVID, because the number of chest CTs has been grown by leaps and bounds. On the other hand, human population is getting older, there is more chance to develop lung cancer and probably second or third lung or other tumor during lifetime. And at the same time, surgery should be performed in an older population with impaired lung function and often with severe comorbidities. So the surgeons' demand to perform more parenchyma preserving lung resections using less invasive way from surgical and anaesthesiological point of view as well is natural.

Since 'radical lobectomy' was published by Cahan in 1960, the standard surgical care for lung cancer has been lobectomy, in which units of the lobe are removed with their specific regional hilar and mediastinal lymphatic vessels and nodes (6). Therefore sublobar resections were mostly performed for benign lung diseases, like tuberculosis etc. Atypical wedge resection and segmentectomy are known as sublobar resections. These limited resections were recognized as 'compromise' procedures, although some investigators stated that it could be the standard treatment for T1N0 lung cancer patients. Pulmonary function-preserving limited resection for lung cancer has gradually become more prevalent in the late 20th century.

Pastorino et al. published a retrospective study of comparison of lobectomy and sublobar resection, with no significant differences in 5-year survival and recurrences between the lobectomy and sublobar resection groups. Global 5-year survival for sublobar resections and lobectomies was 55% and 49%, respectively. 5-year survival was 73% and 35% of the T1 and T2 tumors, respectively, for sublobar resections; and 55% and 46%, for lobectomies, respectively. The recurrence rate was 36% for sublobar resections and 38% for lobectomies (7, 8). Thanks to this retrospective study, in 1995, Ginsberg et al. conducted a randomized controlled trial in which limited resection (segmentectomy and wide-wedge resection) and lobectomy for stage I lung cancer were compared and found that sublobar resection is not recommended for healthy patients with stage IA lung cancer (9). In their study the primary endpoint was overall survival (OS). The 5-year OS was 42% in the limited resection group and 63% in the lobectomy group, so limited resection has been proved to be inferior compared to lobectomy. Furthermore, the local recurrence rate after lobectomy was 6%, while it was

significantly higher (17%) in sublobar resection group (8). Thanks to these controversial results, sublobar resection for lung cancer has been, and still is, a controversial issue. Sublobar resections were associated with a significant increase in local recurrence compared with lobectomies, but cancer-related and overall death rates were similar, did not show significant differences, although they were higher in the sublobar resection group (10). Because of the increased risk of recurrence in sublobar resections, lobectomy was established as the minimal acceptable resection for lung cancer, while sublobar resections were considered to be a compromise solution for those patients who could not be candidates for lobectomy. The main weaknesses of these retrospective and prospective studies were the confusion of wedge resections and segmentectomies in the same group as sublobar resections and question of the extent of lymphadenectomies. A meta-analysis by Nakamura et al. on survival following lobectomy and limited resection for stage I lung cancer confirmed the results of the randomised trial: there were no statistically significant differences between the two groups, but there was a small benefit in the lobectomy group (11). By now, most thoracic surgeons accept that segmentectomy is an option for patients otherwise inoperable from functional point of view and it is equal to lobectomy for T1N0 lung cancer patients after careful patient selection. On the other hand, wedge resection is easy to perform, but it is inferior to lobectomy, the recurrency rate is significantly higher, the OS is lower.

There are a few more important questions to be asked and proper patient selection is mandatory. We have to identify the so-called „high risk” patients, who are not candidates for lobectomy, but can undergo sublobar resections. Furthermore and not less importantly, we have to identify those early-stage lung cancer patients, who can have sublobar resections with the same expected survival as with lobectomy. There can be many factors to be considered during decision making, like tumor size, localization, histological type etc. Tumor histology is one of the most important questions.

Adenocarcinoma is the most frequent histological subtype among non-small cell carcinomas. Most cases of adenocarcinoma are neoplasms with mixed architecture. They should be subclassified according to the predominant growth pattern, after identification and quantification of all histological patterns in the tumour in 5% increments (12). Most studies have focused on predominant growth patterns and their impact on survival. It is well documented that lepidic predominant carcinomas have better outcome (13), while solid and micropapillary predominant carcinomas have an unfavourable prognosis (13,14). These results have validated the novel classification of lung adenocarcinomas. However, many lung

adenocarcinomas show mixed-subtype patterns with two or more different growth patterns, and the impact of non-predominant growth patterns on survival is controversial. Three growth patterns of invasive adenocarcinomas have been investigated recently, namely the lepidic, the solid and micropapillary patterns. Higher proportion of lepidic component is usually associated with better prognosis (15). Pure lepidic carcinoma is defined as in situ adenocarcinoma with 100% overall survival and disease-free survival. The rates of overall and disease-free survival are similarly excellent in case of minimally invasive adenocarcinoma which is a lepidic predominant tumor with invasive focus less than 5 mm (15). Invasive, lepidic predominant carcinomas belong to low grade tumours according to the architectural grade, due to their favourable prognosis. A higher proportion of solid or micropapillary pattern refers to worse prognosis. Local recurrence, lymph node and distant metastases are more common among these neoplasms (16). Some authors have found that even 1% or 5% (16-20) of these components may cause an unfavourable outcome. In contrast, Roh and coworkers (21) could not confirm that 5% of micropapillary component results in worse overall survival. Similarly, Sumiyoshi et al. found that the mean percentages of micropapillary pattern showed no significant differences in the recurrent (20.4%) and non-recurrent (18.3%) groups (22). Beneath the evaluation of proportions of components, predominant and secondary predominant growth patterns can be investigated, as well. Zhao and coworkers have found that acinar/papillary carcinomas having secondary predominant solid or micropapillary patterns show worse prognosis than acinary/papillary carcinomas without secondary solid or micropapillary components (23).

Performing sublobar lung resections might be challenging. Atypical wedge resections are usually straightforward, because this procedure doesn't respect the anatomical borders. Segmentectomies, when the resection line must be exactly in the intersegmental plane, not to leave devitalized lung parenchyma in situ and preserve as much parenchyma as possible, can be technically difficult. There are a few techniques developed for intersegmental plane identification. Traditionally, the inflation and deflation technique has been used for intersegmental plane identification, owing to difficulties in emphysematous lungs and obstruction of the surgical view, mainly during VATS procedures (24). To avoid these problems, many other techniques have been developed, while in 2009, Misaki et al. conducted an experimental study on dogs and demonstrated the feasibility of intersegmental plain identification using near-infrared imaging (NIR) after intravenous administration of indocyanine green (ICG) (25). During the last 2 decades, the intraoperative use of invisible NIR fluorescence imaging has started to find its role in the surgical theater, filling the gap between

preoperative imaging and intraoperative findings (26). NIR fluorescence imaging systems use a special camera to detect the infrared light emitted by a fluorescent dye after excitation by a specified infrared light. All these systems can be integrated into a camera used during open surgery or within laparoscopic or robotic instruments. Nowadays, different NIR systems have been developed, such as „Novadaq SPY™ system, Hamamatsu’s Photodynamic Eye, Artemis™, Fluoptics’ Fluobeam, functional intraoperative FMI systems: FLARE™ imaging system” etc (26). There are several advantages of using NIR light-imaging systems. While visible light can travel to the tissue only a few microns, NIR light (700–900 nm) can penetrate even up to centimeters through different tissues (27). As the tissue shows minimal autofluorescence in the infrared spectrum, the so called signal-to-background ratio can be maximized, when using NIR fluorescent dyes, creating “white stars in a black sky” (28), achieving optimal contrast during imaging. In addition, using this technique there is no use of ionizing radiation, making it basically safe. Furthermore, as NIR light is not visible to the human eye, it does not affect the surgeon’s vision (26). There are many different fluorophores used during NIR surgery and ICG is the dye that is used most frequently. It is a water-soluble, amphiphilic, tricyanocyanine fluorophore with a molecular weight of approximately 775 D and an absorption and fluorescence spectrum in the NIR region (29). When administered systemically, the ICG forms nanoparticles by rapidly binding to plasma proteins and lipoproteins. The liver takes up and excretes more than 80% of the available ICG into the bile within 18 h of administration (29). ICG is safe at systemic doses as high as 5 mg/kg, although some cases of anaphylaxis have been reported (30). Wavelengths of excitation and emission are approximately 805 and 830 nm, when ICG is dissolved in blood (30). The 830 nm wavelength of emission spectrum of ICG shows tissue penetration to up to 15 mm, and there is almost no autofluorescence from endogenous tissues (31). Having of the amphiphilic features and protein-binding attributes of ICG, it is able to migrate within lymphatic veins. Furthermore, ICG is quite cheap, non-toxic, Food and Drug Administration (FDA)-approved, and readily available, making it an optimal dye for NIR fluorescence guidance. Currently, the FDA specifically approves of using ICG for cardiac output tests, hepatic function tests, and ophthalmic angiography (30). However, ICG also has some disadvantages, such as moderate photostability, a relatively narrow fluorescence quantum yield, a high propensity to bind plasma proteins and aggregation in water solutions (32).

## **2. Objectives:**

Our main goal was to study the changes of the lung cancer and the impact of this change on the surgical treatment, its possible effect on the surgical trends and techniques.

I.: In our retrospective study we studied the changes in the clinicopathological features of surgically treated lung cancer around the millenium. In our work, the data of lung cancer patients of the last 15 years were retrospectively analyzed, we examined the demographic characteristics, the histological type, the stage of the lung cancer, the type of the surgical procedure used, other supplemental treatment and survival (33).

II.: After observation of ground gaining of sublobar resections, we aimed to identify the parameters for proper patient selection. In the literature, the radiological criteria have been extensively investigated, we focused on the histopathological features. In our second study our aim was to analyse the predominant and the secondary predominant components and the proportions of different growth patterns, namely lepidic, acinar, papillary, solid, micropapillary and cribriform, in stage I lung adenocarcinoma and their influence on overall and disease-free survival. To reach this aim, we decided to use an objective measurement, i.e. the best approximation of areas involved by each pattern available for the cases (34).

III.: Thirdly, in our mini-review, we intended to overlook the use of NIR fluorescence guided surgery during thoracic procedures, emphasizing the usefulness of ICG. This technique is very effective during many different thoracic surgical procedures, like sentinel lymph node localization, evaluation of vascular supply of different organs and intersegmental plane identification in difficult cases (24).

## **3. Study I.:**

Géczi, Tibor, Csada, Edit, Tiszlavicz, László, Lázár, György, Furák, József. A műtéileg kezelt tüdőrák klinikopatológiai jellemzőinek változása az ezredfordulónkon [Changes in the clinicopathological features of surgically treated lung cancer around the millennium] ORVOSI HETILAP 159 : 10 pp. 391-396. , 6 p. (2018) DOI WoS Scopus PubMed Matarka MOB SZTE Publicatio (33)

### **3.1. Materials and methods I.**

I.: We compared the clinicopathological features of lung resection cases carried out in our department of 2 different 5-year periods. The earlier period was defined as operations performed between 01.01.1998 and 31.12.2002, while the later one was between 01.01.2008 and 31.12.2012. The interval period was ignored during data collection. Patient age, sex, change of cancer histological type and the evolution of different surgical methods were studied. Preoperative examination of the patient was carried out in the competent pulmonology departments, performing chest X-ray, CT, bronchoscopy, transbronchial needle biopsy, spirometry and when indicated PET-CT and ergospirometry as well. Certainly, the final therapeutic decision was made by the multidisciplinary team meeting. During the first period TNM staging was determined by the 6th TNM classification of lung tumors, but the 7th TNM classification has been used since January 2010, This change might distort the data of the non-early lung cancer cases, but it has no effect on the I/A stage. Statistical analysis was performed by the SPSS (Statistical Package for the Social Sciences, 19.0, SPSS Inc. Chicago, IL, USA) programme using  $\chi^2$  and Kaplan-Meier probe.

### 3.2. Results I.

I. There were 497 patients (27% women and 73% men) operated during the first period, their age varied between 30 and 80 years (mean age:58.5 years) and 63.1% of them were smokers. During the second period much more, 799 patients had thoracic surgery for primary lung cancer, only 43% of them were women and 57% men. Their mean age was 61.5 years (23-85 years) and 68% of them were smokers (*Table 1*).

	<b>1st period</b> (1998-2003)	<b>2nd period</b> (2008-2012)
Operations	497	799
Sex (women/men)	27%/73%	43%/57%
Average age (years)	58.5 years (30-80)	61.5years (23-85)
Smokers (%)	63.1%	68%

*Table 1. Age and sex distribution of resected lung cancer cases*

During the second period there were quite many, 126 patients (16%) presenting with lung cancer as second primary malignant tumor. In 42 cases (33%) this lung cancer developed after a successfully treated first, but different lung tumor, it is 5.2% of all the lung cancer cases. The histology of these surgically resected lung cancers are shown in *Table 2*. We would like to emphasize that occurrence of the adenocarcinoma, squamous cell and large cell carcinoma cases changed significantly.

	<b>1st period</b> (1998-2002)	<b>2nd period</b> (2008-2012)	<b>p-value</b>
Addenocarcinoma	<b>199 (40%)</b>	<b>499 (62.5%)</b>	0.001
Squamous cell carcinoma	<b>203 (40.8%)</b>	<b>205 (25.7%)</b>	0.001
Large cell carcinoma	23/497	3/799	0.001
Small cell carcinoma	14/497	32/799	0.352
Carcinoid	29/497	28/799	0.162

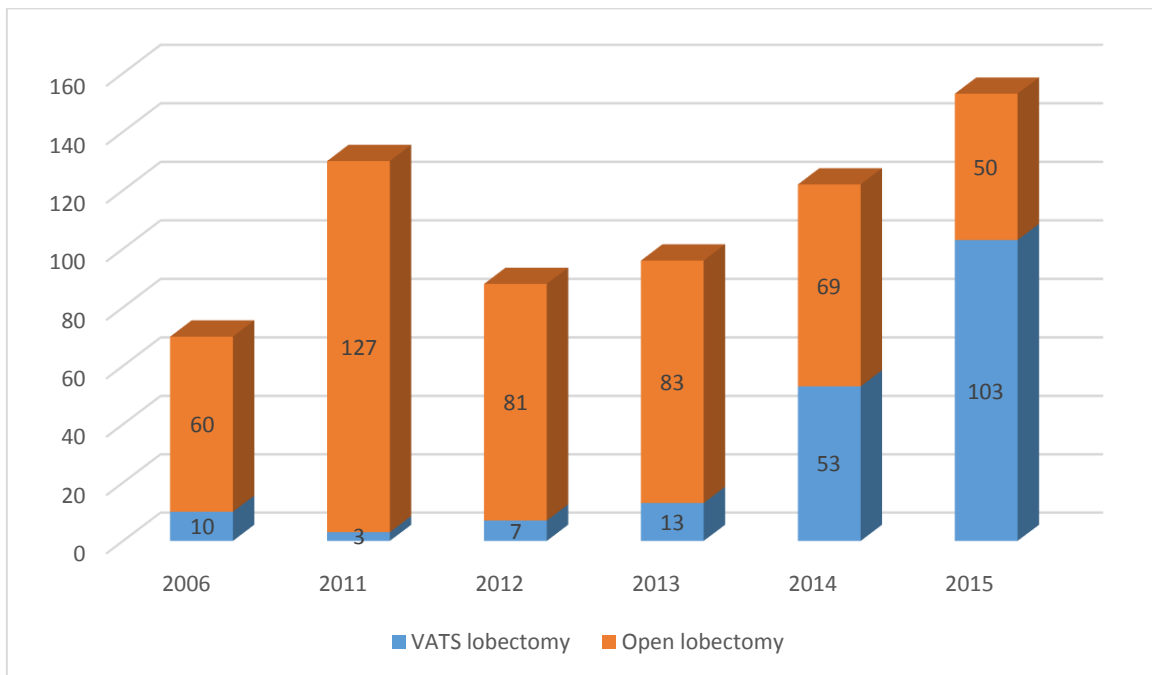
*Table 2. Histology of resected lung cancer cases*

Analyzing the different surgical methods, we can see that the rate of pneumonectomies decreased from 27.1% to 9,4% (*Table 3.*). Parallel to this fact, the rate of lobectomies and sleeve lobectomies increased from 58% to 75.2%. This is due to the improvement and increase of sleeve lobectomies, because this technique can replace pneumonectomy, while reaching the same radicality and preserving lung parenchyma in certain cases. Therefore there were patients who became operable from functional point of view. During the second period thoracoscopy became the method of choice for lobectomies too, it was our learning curve for major VATS resections. In the first period only minor resections, atypical wedge resections were carried out via thoracoscopy (*Table 3.*). There was no anatomical segmentectomy performed during the first period, while 3.2% of patients had segmentectomy in the second one.



	<b>1st period</b> (1998-2002) (497 patients)	<b>2nd period</b> (2008-2012) (799 patients)	<i>p</i> -value
Pneumonectomy	27.1%	9.4%	0.001
Lobectomy	58%	75.2%	0.001
Bilobectomy	2.2%	3.3%	0.149
Pneumonectomy/ sleeve lobectomy	104/13	78/76	
Segmentectomy	0%	3.2%	0.051
Atypical wedge resection	7,8%	7,2%	0,134
Exploratory thoracotomy	4.3%	2.8%	0.139

*Table 3. Distribution of different surgical types for lung cancer*



*Fig. 3. Open and VATS lobectomies*

Distribution of lung cancer cases according to staging is shown in *Table 4*. Due to the change of TNM classification, comparison of advanced cases might be distorted, but the early cases are unchanged. 30 day mortality after neoadjuvant chemo/radiotherapy was 5.7% (3/53) in the second period, while there was no preoperative treatment in the first one. There were also 3 cases, where the final pathology report revealed R1 resection, microscopic tumor cells in the resection line without macroscopic invasion.

	<b>1st period</b> (1998-2002)	<b>2nd period</b> (2008-2012)	<b>p-value</b>
I/A	87 (17.5%)	261 (32.7%)	0.001
I/B	145/497	202 (25.3%)	0.029
II/A	7/497	46/799	0.001
II/B	91 (18,3%)	48/799	0.001
III/A	83 (16.7%)	169 (21.2%)	0.142
III/B	29/497	15/799	0.001
IV	26/497	39/799	0.6

*Table 4. TNM staging of the resected lung cancer cases*

5-year survival was similar in both periods, 52% in the first period and 50% in the second one. Median survival was 27 months after lung resections following neoadjuvant treatment. Less than half of the patients (45.2%) were able to tolerate adjuvant chemo- or radiotherapy after pneumonectomy. This ratio was significantly ( $p=0,016$ ) higher (82.6%) after sleeve lobectomies. This difference is clearly visible in overall survival as well, patients being able to receive complete adjuvant therapy survived significantly ( $p=0,009$ ) longer (44 months) compared those, who could not (20 months).

### 3.3. Discussion I.

The leading cause of cancer-related mortality is the lung cancer among men and it is on the third place among women. From our article No. I. it is clearly visible, that the significant majority of male sex is decreasing, the ratio of women is continuously rising. This tendency is observable in the data of National Cancer Registry as well (2). Analyzing the histological results we can see that the previously most frequent histological type, the squamous cell carcinoma is currently on the second place, nowadays thoracic surgeons meet lung adenocarcinomas most often. Viewing the distribution of tumor stages it is clear that the proportion of early, I/A stage lung cancers has significantly increased, from 17.5% to 32.5 ( $p = 0,001$ ). It can be partially thanked to the improving quality of digitalized radiographical technique and low-dose CT screening and partially to the fact, that the routine follow-up of patients treated with cancer is performed with CT, therefore small, early-stage lung cancers are more frequently diagnosed (35). The ratio of pneumonectomies decreased from 27.1% in the first period to 9.4% in the second one, parallel to this the amount of lobectomies and sleeve lobectomies increased from 58% to 75.2%. This significant change is the result of evolution of sleeve lobectomies, which can replace pneumonectomy in certain cases. Therefore surgical trauma and lung parenchyma loss can be decreased, survival can be increased and the number of surgical candidates can be widened. Patients undergoing sleeve lobectomy tolerate adjuvant chemotherapy better than after pneumonectomy. After pneumonectomy only 45.2% of the patients were able to undergo and receive the whole adjuvant chemotherapy. This ratio is significantly higher (82.6%) after sleeve lobectomy. After careful preoperative evaluation some advanced stage lung cancers can become resectable, if preoperative, neoadjuvant therapy is used. There was no neoadjuvant therapy in the first period, but 53 patients (11.9%) received oncological treatment in the second period, there were 47 preoperative chemotherapy patients (4 Pancoast-tumors, 2 central tumors) and it was supplemented with radiotherapy in 6 cases. Currently, minimally invasive surgery, VATS is the gold standard. During the first period only the „minor procedures” were performed by VATS, there was no VATS lobectomy. The first VATS lobectomy was carried out in 2006 in our department and 70% of the lobectomies were performed by VATS in 2015.

Most importantly, sublobar resections, primarily segmentectomy is used more and more often with curative intent in the literature and in our practice as well. There was no segmentectomy during the first period, while 3.2% of the operations was anatomical

segmentectomy in the second period. This ratio is continuously rising in our practice, according to the European data 6.5% of resections for tumor is segmentectomy (36).

With the continuous rise of the incidence of freshly discovered small, early-stage lung cancer cases and the more and more older patients with poor lung function, the claim of thoracic surgeons for performing less invasive, more parenchyma-preserving lung surgeries is natural. There were and there are many viewpoints which must be taken into consideration during patient selection. Originally, sublobar resections were considered for only high-risk patients with compromised lung function. One of the most frequently used definitions for high-risk patients comes from the American College of Surgeons Oncology Group (ACOSOG) Z4032 trial of stage I non-small cell lung cancer (NSCLC), with tumors  $\leq 3$  cm, that focused on clinical details to define high risk (37, 38). Patients were considered to be high-risk, if their lung function tests showed a Forced Expiratory Volume in 1 second (FEV1)  $\leq 50\%$  of predicted, or if their Diffusing Capacity for Carbon Monoxide (DLCO) was  $\leq 50\%$  of predicted, or if they met two of the following criteria: age  $\geq 75$  years, FEV1 51%-60% predicted, DLCO 51%-60%, diagnosed with pulmonary hypertension (pulmonary artery systolic greater  $> 40$  mmHg) as estimated by echocardiography or cardiac catheterization, left ventricular ejection fraction  $\leq 40\%$ , resting or exercise arterial pO<sub>2</sub>  $\leq 55$  mmHg or SpO<sub>2</sub>  $\leq 88\%$ , pCO<sub>2</sub>  $> 45$  mmHg, or Modified Medical Research Council Dyspnea Scale score  $\geq 3$ .

It is very important to emphasize, that nowadays, sublobar resections, especially segmentectomy can be curative surgical operations with the same radicality for otherwise fit patients, who would be candidates for lobectomy as well. There are various clinicopathological, radiological and surgical criterias we should take into consideration to achieve this goal.

Mery et al. in their study examined the overall survival after lobectomy or sublobar resection and patients' age in 3 different age groups,  $<65$  years, between 65 and 75 years and older than 75 years. They found that in the first 2 groups lobectomy could provide significantly better survival compared to wedge resections, but over 75 years this difference has vanished. Further statistical analysis showed the age of 71 year to be the turning point (39).

Pulmonary function-preserving limited resection for lung cancer has gradually become more prevalent in the late 20th century. Ginsberg et al. conducted a randomized controlled trial in which limited lung resection and lobectomy for stage I lung cancer were compared and reported that limited resection should not be applied to healthy patients (9). In contrary to this, other studies showed that segmentectomy can provide the same overall and tumor-free survival

than lobectomy in selected patients. Nakamura et al. in their meta-analysis found that in the examined 13 retrospective studies the survival after limited resection for stage I lung cancer is comparable to lobectomy, there is no significant difference (11). Miller et al. examined the survival of 1cm or smaller non-small cell lung cancer cases treated with lobectomy and sublobar resections (37). There was no difference in tumor recurrence rate between lobectomy and sublobar resections, but wedge resection had higher recurrency rate, 38,5% of wedge resections, 16,7% of segmentectomies and 14,7 of lobectomies. El-Sherif et al. in their study investigated 577 patients after lobectomy and 207 after sublobar resection (40). They found that the overall survival of patients with IA stage lung cancer was similar, significant difference could have been proved only in stage IB. Okumura et al showed the same, the 5 and 10 year survival of lobectomy patients with tumor less than 2 cm were 81% and 64%, while these were 83% and 62% (41). 2 cm tumor size was the cut-off value in other studies as well (42, 43). Aokage et al. in their review of the recently finished and ongoing studies of the Japan Clinical Oncology Group examined the results after segmentectomy and hilar lymph node dissection (44). According to their opinion it results satisfactory prognoses in patients with predominantly Ground Glass Opacity (GGO) lung cancers ( $C/T$  ratio  $\leq 0.5$ ) and tumour sizes exceeding 2 cm but 3 cm or less. Thus, they commenced another non-randomized confirmatory trial to confirm the efficacy of segmentectomy for clinical T1abN0 lung cancers with GGO. According to the results of JCOG0802/WJOG4607L study, Saji et al. published segmentectomy to be non-inferior and superior to lobectomy with regards to overall survival (45). Therefore, they concluded that segmentectomy should be the standard surgical procedure, rather than lobectomy, for patients with small-sized ( $\leq 2$  cm, consolidation-to-tumour ratio  $> 0.5$ ) peripheral non small cell lung cancer, even though they could not find the expected evidence of superiority in postoperative respiratory function in the segmentectomy group. However, locoregional recurrences were found more frequently in the segmentectomy group, although no significant difference was reported in the overall relapse-free survival. Death from other cancers (including second primary lung cancer), respiratory disease, and cerebro-vascular disease, occurred more frequently in the lobectomy group than in the segmentectomy group. By contrast, the incidences of second other cancers and second primary lung cancers in both groups were similar, and incidences of carcinomas in situ were also similar.

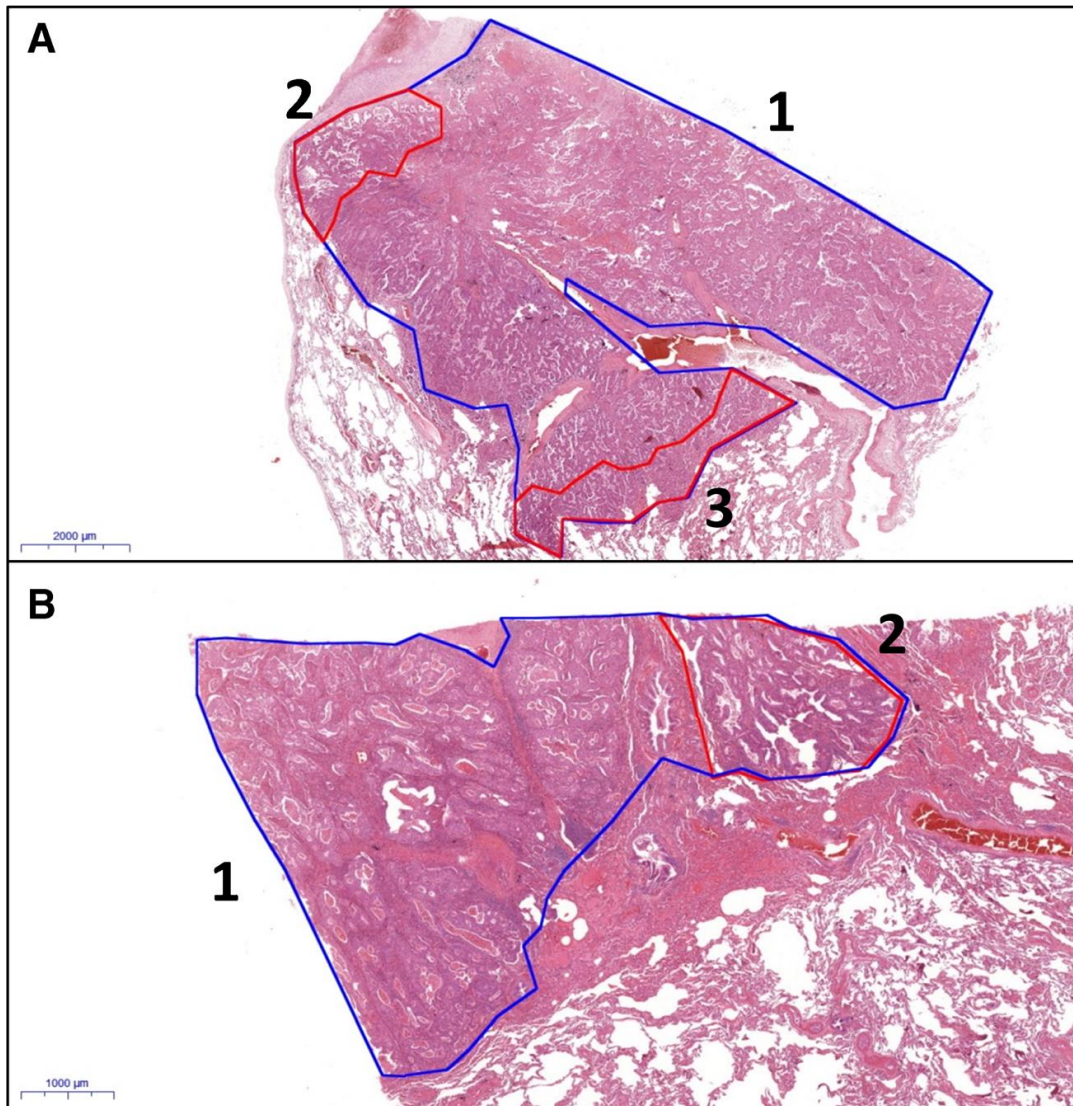
## **4. Study II.**

Tamás Zombori, Tibor Nyári, László Tizslavicz, Regina Pálföldi, Edit Csada, Tibor Géczi, Aurél Otlakán, Balázs Pécsy, Gábor Cserni, József Furák. The more the micropapillary pattern in stage I lung adenocarcinoma, the worse the prognosis-a retrospective study on digitalized slides *Virchows Archives* 472, pages949–958 (2018) DOI: 10.1007/s00428-018-2337-x

### **4.1. Materials and methods II.**

Haematoxylin-eosin slides of consecutive patients having pulmonary adenocarcinoma in stage I according the 8th Edition of TNM Classification were analysed in our retrospective cohort study II. The patients were operated on between 2004 and 2013 at the Division of Thoracic Surgery, Department of Surgery, University of Szeged. The following cases were excluded: patients having multicentric, metachronous or metastatic tumours, or variants of adenocarcinoma, namely invasive mucinous, mixed invasive mucinous/non-mucinous, colloid, foetal, enteric and pleomorphic/sarcomatoid, and those having lung cancer surgery in the preceding 2 years, positive surgical margins, perioperative death, vascular invasion and lack of immunohistochemical phenotyping. For all cases included, mucin staining and immunohistochemistry were applied in the routine diagnostic process. Mucin production and TTF-1 positivity were considered as evidence in support of a primary pulmonary adenocarcinoma for non-small cell lung cancer cases. For TTF-1-negative tumours, further immunohistochemical results have been considered to rule out squamous cell carcinoma (p40 negativity) and metastatic carcinoma (different markers for different primaries). Clinical data, including gender, age, tumour localization, type of surgery, smoking habits, KRAS and EGFR mutation status and site of recurrence, and follow-up data were obtained from medical charts. Stage I was defined by the combination of tumour size and nodal status in addition to clinical data about the lack of distant metastasis. In all cases, lymphadenectomy was part of the operation and the lymph nodes were examined histologically. The follow-up of patients consisted of three-monthly physical examination, chest x-ray examination and abdominal

ultrasonography evaluation in the first 2 years, then six monthly until the fifth year. Chest computer tomography (CT) was performed every 6 months for the first 2 years, then 6 or 12 monthly depending on the patient, until the fifth year. In case of any suspicion of progression, chest CT and abdominal ultrasonography were included. The follow-up period ended on the 31th August 2017. All available tumour containing slides were digitalized by a Panoramic 250 scanner (3DHistec, Budapest). As one section was taken from each centimetre of the largest tumour dimension, the number of slides digitalized was influenced by tumour size. The Case Viewer software (3DHistec, Budapest) was utilised for evaluating the cases. In the present study, we used digitalized slides. In the first step, the proportions of growth patterns were estimated in 5% increments, and the predominant, secondly and thirdly predominant components were determined with naked eye evaluation. In the second step, the different patterns of the entire tumour were annotated and their areas were measured in square millimetre. The proportions of each component were calculated from the measured areas (*Fig. 4*). In the third step, the predominant and secondly predominant patterns were reevaluated in one third of the cases after a time period of minimum 2 weeks. The patterns were re-annotated for assessing intra-observer variability. All available tumour slides were used for all the listed evaluations. Statistical models were based on the calculated proportions of the components (second step evaluation mentioned above). Spearman's rank correlation was used to investigate intraobserver variability. Five-year overall and disease-free survival estimates and mean survival times with their 95% confidence intervals (95% CI) for overall and disease-free survival were assessed using Kaplan-Meier estimates. The log rank test was used for pairwise comparisons. All statistical tests were two-sided, and  $p < 0.05$  values were considered statistically significant. We utilised the SPSS Statistics software (IBM, SSPS 22.0, Armonk, NY, USA).



*Fig. 4. Examples of annotations of digitalized slides (A: HE, 0.5×; B: HE, 1.5×; 1 (blue): whole tumour, 2 and 3 (red): minor components of tumour)*

## **4.2. Results II.**

Altogether, 327 patients matched the inclusion criteria described in the materials and methods' section in our histopathological study. Clinical follow-up data were missing in 35 cases of surviving and in 31 cases of deceased patients. Slides were not available in 18 cases. After exclusion of patients with missing data or slides, 243 cases remained for this retrospective analysis, with 141 cases in stage IA1–3 and 102 cases in stage IB. Median age of the patients



was 62.3 years (range 33–85). No gender predominance was observed (female 50.7% vs. male 49.3%) in stage I. Most patients had complete lobectomy (lobectomy 90.1% vs. sublobar resection 9.9%). *Table 5.* displays the most important clinicopathological data.

<b>Clinicopathological data</b>		
<b>Gender</b>		<b>n (%)</b>
	<b>Female</b>	123 (50.7%)
	<b>Male</b>	120 (49.3%)
<b>Age</b>		<b>years</b>
	<b>mean</b>	61.6
	<b>median</b>	62.3
<b>Localisation</b>		<b>n (%)</b>
	<b>Left</b>	144 (59.2%)
	<b>Right</b>	99 (40.8%)
<b>Type of surgery</b>		<b>n (%)</b>
	<b>Lobar resection</b>	219 (90.1%)
	<b>Sublobar resection</b>	24 (9.9%)
<b>Smoking habits</b>		<b>n (%)</b>
	<b>Active smoker</b>	170 (70%)
	<b>Not anymore &gt; 1year</b>	21 (8.6%)
	<b>Never</b>	52 (21.4%)
<b>pT (pN0, pM0)</b>		<b>n (%)</b>
	<b>T1a</b>	13 (5.5%)
	<b>T1b</b>	64 (26.3%)
	<b>T1c</b>	64 (26.3%)
	<b>T2a</b>	102 (41.9%)
<b>Stage</b>		
	<b>IA1-3</b>	141 (58.1%)
	<b>IB</b>	102 (41.9%)
<b>Immunophenotype/Histochemistry</b>		<b>n (%)</b>
	<b>TTF-1 positive</b>	188 (77.3%)
	<b>CK-7 positive</b>	243 (100%)
	<b>Alcian-blue positive</b>	198 (81.4%)

*Table 5. Clinicopathological characteristics of patients*

With all available haematoxylin-eosin-stained slides digitalized and evaluated, the median number of slides per patient was 3 (range 2–5). Although the statistical results described below were based on the calculated proportions of the components, the results were similar if the proportions were determined with naked eye. In *Table 6*, the different growth patterns were

recorded in all cases as predominant, secondly predominant, thirdly predominant or absent and associated with 5-year overall and disease-free survival estimates. The median follow-up was 61.5 months (range 1.5– 175.3 months). Significant differences in survival rates were found in association with proportions of lepidic pattern (better survival) and proportions of micropapillary or solid patterns (worse survival).

Growth pattern	Predominant (1)			Secondly predominant (2)			Thirdly predominant (3)			Absent (0)			p
	n (%)	OS (%)	DFS (%)	n (%)	OS (%)	DFS (%)	n (%)	OS (%)	DFS (%)	n (%)	OS (%)	DFS (%)	
													(log rank test)
Lepidic	48 (20)	90.5	89.4	25 (10)	67.2	54	34 (14)	75	75	136 (56)	69.4	60.3	p1-0=0.005 (OS)
													p1-0=0.004 (DFS)
													p1-2=0.019 (OS)
													p1-2<0.001 (DFS)
Acinar	36 (15)	83.3	61.,5	45 (19)	84.4	76.3	17 (7)	58.4	63.5	145 (59)	70.9	66.7	
Papillary	35 (15)	85.2	72.4	44 (19)	72.4	73.9	31 (13)	91.4	82.,5	133 (53)	66.,8	56.1	
Solid	100 (41)	64.1	56.3	10 (4)	69.5	60	26 (11)	73.1	72.1	107 (44)	82.9	73.2	p1-0<0.001 (OS)
													p1-0=0.023 (DFS)
Micropapillary	16 (7)	28.1	28.1	20 (8)	51.1	57.8	26 (11)	65.7	63.4	181 (73)	74.9	67.8	p1-0<0.001 (OS)
													p1-0=0.004 (DFS)
													p2-0=0.002 (OS)
													p2-0=0.05 (DFS)
													p1-2=0.02 (OS)
													p1-2=0.004 (DFS)
Cribriform	8 (4)	75	75	9 (4)	88	88	7 (3)	68.6	71.4	219 (89)	73.3	64.2	
	Mean OS	95%CI*		Mean OS	95%CI*		Mean OS	95%CI*		Mean OS	95%CI*		
		lower	upper		lower	upper		lower	upper		lower	upper	
Lepidic	127.8	115.4	140.3	101.6	64.3	118.8	97.7	87.5	120.4	82.0	64.4	109.0	
Acinar	105.7	93.2	118.4	108.8	91.7	123.4	98	89.6	114.8	102	90.0	115.8	
Papillary	112.4	94.9	130.7	103.0	87.2	112.8	115.7	102.3	128.4	93.4	85.5	108.8	
Solid	89.4	77.0	101.8	98.4	65.6	131.7	104.1	84.7	123.6	119.2	109.1	129.2	
Micropapillary	53.9	32.8	73.7	95.5	75.6	109.4	101.5	68.2	115.8	117.7	111.5	134.4	
Cribriform	98.2	65.2	131.5	126.4	97.6	155.2	79.6	55.9	98.4	104.5	96.7	112.5	

\*95CI: 95% confidence interval

*Table 6. Kaplan-Meier estimates of 5-year OS and DFS rates, and mean values of OS and DFS associated with predominant, secondly and thirdly predominant or absent growth patterns and the log rank p values found significant are displayed.*

Growth p	>75%			51-75%			25-50%			<25%			0%		
	n (%)	OS (%)	DFS (%)	n (%)	OS (%)	DFS (%)	n (%)	OS (%)	DFS (%)	n (%)	OS (%)	DFS (%)	n (%)	OS (%)	DFS (%)
Lepidic	25 (10)	88	91.4	14 (6)	70.3	76.2	4 (2)	75	75	21 (9)	75.2	60	179 (73)	70.5	61
Acinar	20 (8)	90	68.7	15 (6)	93.3	79.4	21 (9)	72.5	66.3	51 (21)	78.3	72.8	136 (56)	67.8	60
Papillary	24 (10)	82.9	70	14 (6)	92.9	77.9	13 (5)	84.6	76.9	63 (26)	78.3	74.9	129 (53)	65.1	56.8
Solid	81 (34)	58.2	52.2	15 (6)	68	65.2	13 (5)	50	53.8	29 (12)	80	78.1	105 (43)	82.5	72.7
Micropap	15 (6)	25	25	18 (7)	38.9	37	12 (5)	55	57.80	37 (15)	70.6	68.4	161 (67)	74.1	68
Cribriform	6 (2)	66.7	66.7	7 (3)	100	100	5 (2)	100	100	18 (7)	82.5	63.2	207 (86)	72.4	73.1
	Mean	95%CI*		Mean	95%CI*		Mean	95%CI*		Mean	95%CI*		Mean	95%CI*	
	OS	lower	upper	OS	lower	upper	OS	lower	upper	OS	lower	upper	OS	lower	upper
Lepidic	131.6	114.9	148.4	114.1	89.1	125.7	106.7	87.4	121.2	105.3	85.3	110.4	98.2	88.8	105.1
Acinar	110.4	97.6	124.4	113.4	101.5	124.7	107.4	82.7	131.5	105.6	90.1	120.6	97.3	86.0	108.5
Papillary	112.4	94.9	130.7	103.0	87.2	112.8	100.2	82.8	123.4	115.7	102.3	128.4	92.5	82.4	106.4
Solid	76.3	49.3	96.9	83.5	70.2	106.3	94.7	78.8	101.2	111.8	98.5	125.1	118.7	108.5	128.9
Micropap	66.1	35.4	95.2	66.0	40.6	86.7	78.1	50.6	106.3	112.1	99.4	120.3	119.4	104.4	135.7
Cribriform	101.6	91.4	122.7	105.7	95.3	126.8	110.2	92.2	125.1	103.2	92.6	118.9	102.4	89.1	110.3

\*95CI: 95% confidence interval

*Table 7. demonstrates the overall and disease-free estimates of growth patterns grouped into five groups, namely 0, ≤ 25, 26–50, 51–75 and ≥ 75%. Significant differences were observed between various subgroups of lepidic, solid and micropapillary patterns.*

The overall and disease-free survival rates of growth patterns classified as  $\geq 5$  and  $< 5\%$  and  $\geq 1$  and  $< 1\%$  are displayed in *Table 8*. With the 5% cut-off point, significant differences in survival were observed in lepidic, solid and micropapillary patterns, and with the 1% cut-off point in lepidic and solid patterns.

Growth pattern	≥5%			<5%			log rank	
	n (%)	OS (%)	DFS (%)	n (%)	OS (%)	DFS (%)	p (OS)	p (DFS)
Lepidic	61 (25)	81.4	77.8	182 (75)	72.1	61.6	<b>0.04</b>	<b>0.021</b>
Acinar	100 (42)	72.6	61.2	143 (58)	68.5	59.8	0.23	0.28
Papillary	104 (43)	78.6	71.4	139 (57)	73.4	67.4	0.54	0.12
Solid	127 (52)	67.5	58.7	116 (48)	80.2	71.7	<b>0.012</b>	<b>0.005</b>
Micropapillary	56 (23)	61.2	53	187 (77)	75.6	68.7	<b>0.045</b>	<b>0.041</b>
Cribriform	24 (10)	86.3	72	219 (90)	82	64.3	0.31	0.56
		95%CI*			95%CI*			
	Mean OS	lower	upper	Mean OS	lower	upper		
Lepidic	121.5	105.0	131.4	99.4	90.6	106.2		
Acinar	105.2	91.1	112.2	101.2	93.7	115.6		
Papillary	110.7	102.8	118.6	105.6	95.5	113.5		
Solid	95.1	84.1	106.7	116.7	107.5	126.5		
Micropapillary	94.5	81.5	105.1	114.5	105.2	124.4		
Cribriform	102.6	89.5	110.0	101.1	91.8	118.7		
Growth pattern	≥1%			<1%			log rank	
	n (%)	OS (%)	DFS (%)	n (%)	OS (%)	DFS (%)	p (OS)	p (DFS)
Lepidic	64 (27)	82.2	78.9	179 (73)	71.7	61	<b>0.037</b>	<b>0.008</b>
Acinar	107 (44)	75.8	71	167 (56)	67.8	60	0.33	0.58
Papillary	114 (47)	80.3	74.1	129 (53)	71.5	65.2	0.27	0.078
Solid	138 (57)	66.7	60.2	105 (43)	82.5	72.7	<b>0.045</b>	<b>0.005</b>
Micropapillary	72 (30)	69.4	56.6	171 (70)	74.1	68.6	0.95	0.11
Cribriform	31 (13)	82.5	71.9	212 (87)	72.4	64	0.42	0.49
		95%CI*			95%CI*			
	Mean OS	lower	upper	Mean OS	lower	upper		
Lepidic	119.8	106.5	131.6	98.7	88.8	107.7		
Acinar	104.9	92.4	116.6	95.4	82.2	106.5		
Papillary	115.8	106.2	125.4	108.7	95.4	115.7		
Solid	89.4	75.6	101.2	107.6	98.6	116.9		
Micropapillary	105.4	91.1	119.0	105.8	95.6	114.3		
Cribriform	103.5	82.4	125.8	96.6	87.4	108.2		

\*95CI: 95% confidence interval

Table 8. Five-year OS and DFS estimates and mean values of ≥5% or less and ≥1% or less component with log rank model results

There was no recurrence in 151 cases (62.1%). Among these cases, the predominant patterns were the following: lepidic (n = 40), acinar (n = 22), papillary (n = 25), solid (n = 54), micropapillary (n = 5) and cribriform (n = 5). Recurrence was diagnosed in 92 cases including lepidic (n = 8), acinar (n = 14), papillary (n = 10), solid (n = 46), micropapillary (n = 11) and cribriform (n = 3) carcinomas. The rate of recurrence was low in lepidic carcinoma (16.6%); intermediate in acinar (38.8%), papillary (28.5%) and cribriform carcinomas (37.5%); and high in solid (46%) and micropapillary carcinomas (68.7%). Systemic dissemination was detected in 59 patients including lepidic (n = 5), acinar (n = 8), papillary (n = 6), solid (n = 30), micropapillary (n = 9) and cribriform (n = 1) carcinomas. In the non-recurrent group, the average proportion of lepidic, solid and micropapillary patterns were 20, 4 and 5%, respectively, whereas in the recurrent group, these rates were 8, 48 and 13%, respectively. The proportions of other patterns were close to equal in the recurrent and non-recurrent groups.

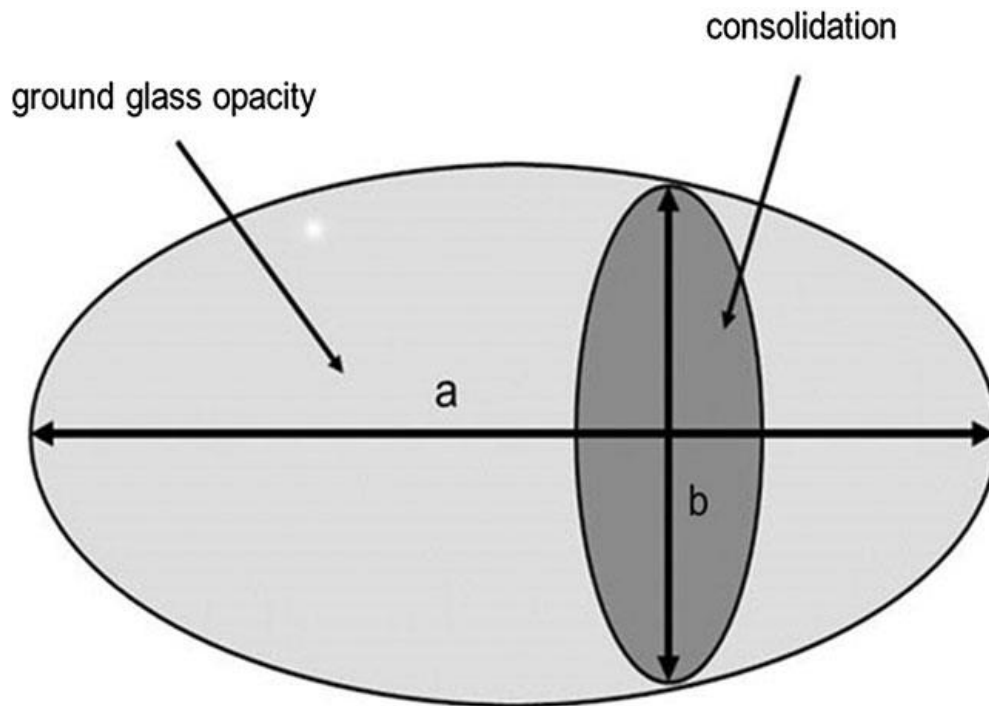
Besides the morphological evaluation, KRAS and EGFR mutation profiles were analysed in cases with available data. Sixty-seven percent of KRAS mutations were found in high-grade tumours, especially in solid neoplasms, while most EGFR activating mutations (88.8%) were in low–intermediate-grade tumours, like lepidic, acinar and papillary carcinomas. In this study, we used naked eye estimation and area measuring for determining the proportions of patterns. As concerns the variability of these methods for the determination of the area of different growth patterns, the opinion agreement was the highest in lepidic, acinar and solid patterns, while papillary, micropapillary and cribriform patterns showed higher variability. In all but one case, the concordance was significant, i.e. there were no relevant differences between the estimated and the calculated proportions of growth patterns.

### **4.3. Discussion II.**

Tumor-free resection margin is one of the basic oncosurgical principles. Local recurrence is a major concern after sublobar resection of non-small cell lung cancer. El-Sherif et al. postulated that a large proportion of local recurrence is related to inadequate resection margins (46). Their report studied the local recurrence after sublobar resection of stage I lung cancer. Stratification based on distance of the tumor (<1 cm vs larger or equal to 1 cm) to the staple line was performed. Margin distance significantly impacted local recurrence; 6 of 41

patients (14.6%) developed local recurrence in the group with margin less than 1 cm versus 3 of 40 patients (7.5%) in the group with margin equal to or more than 1 cm ( $P=0.04$ ). Of the 41 patients with margins  $<1$  cm, segmentectomy was used in 7 (17%), whereas in the 40 patients with larger than 1 cm margins, segmentectomy was used in 19 (47.5%). They concluded that margin is an important consideration after sublobar resections. Wedge resection is frequently associated with margins less than 1 cm and a high risk for locoregional recurrence. Segmentectomy appears to be a better choice when this is chosen as therapy, but achieving resection margin larger than 1cm is crucial.

During the careful preoperative imaging evaluation, we can get information not only about the details of the planned surgical procedure, but sometimes about the likely histological type of the tumor as well. Predominance of GGO of a lung nodule on thin-sliced CT has been widely recognized to correlate with less-invasive pathological finding of cancer cells replacing the alveolar epithelial cells (lepidic growth). Many researchers have reported that patients with lung adenocarcinomas of predominantly GGO on CT images achieved very good prognoses following surgical resection (90-94). Radiological non-invasive lung adenocarcinoma was initially defined as those with a consolidated maximum tumour diameter to tumour diameter ratio (C/T ratio) of less than 0.5 based on previous reports (Fig.5). On CT consolidation component is defined as an area of increased opacification that completely obscures the underlying vascular structures, while ground-glass opacity is defined as an increased hazy density that does not obscure the underlying vascular structure. In an exploratory analysis, Suzuki et al. examined several C/T ratio cut-off values and found 0.25 resulted in diagnostic specificity of 98.7% for being non-invasive adenocarcinomas (52).



*Fig. 5. Schematic of a pulmonary nodule with ground-glass opacity on CT. Length a: the maximum tumour dimension, including the ground glass part, in the lung window. Length b: the maximum consolidation size in the lung window. The consolidation-to-tumour ratio (C/T ratio) was defined as  $b/a$ . (52)*

It is clear that the final histology type of small-sized lung cancers has a huge impact on survival. Among the small, early non-small cell lung cancers squamous cell carcinomas are rare, adenocarcinomas are more common. Okumura et al. in their study showed that segmentectomy resulted in a poor outcome in patients with large cell carcinomas (41).

The new WHO classification of lung adenocarcinomas follows the recommendations of the International Association for the Study of Lung Cancer (IASLC), the American Thoracic Society (ATS) and the European Respiratory Society (ERS). Although the majority of these carcinomas are mixed, the classification takes only the predominant pattern into consideration. Recent studies have shown that secondly predominant patterns or even a small proportion of some patterns can alter prognosis. Lepidic growth pattern is defined by neoplastic cells growing along the pre-existing alveolar walls. This pattern is the first morphologic sign of carcinogenesis, and if the tumour shows only this pattern, it is called in situ carcinoma and has an excellent prognosis (13). The lepidic pattern may be associated with other patterns in mixed

tumours. Lepidic carcinoma is an invasive mixed tumour with lepidic predominant component and is associated with favourable outcome; therefore, it may be proposed that the more lepidic pattern, the better the prognosis. Our results confirm the evidence that lepidic predominant carcinoma has a favourable prognosis, but there was no difference in overall or disease-free survival between tumours with secondly predominant lepidic component and tumours without lepidic component. A difference was found between the mean proportion of lepidic component of tumours with recurrence (8%) and those without recurrence (20%).

Solid pattern lacking glandular differentiation is a feature of high-grade lung adenocarcinomas. Recent studies have shown that solid predominant adenocarcinoma has a poor outcome (13, 53) and secondary predominant solid pattern or even a small amount of solid component ( $\geq 5$  or  $\geq 1\%$ ) may worsen the prognosis (54, 55, 56). A significant difference was observed between OS and DFS of tumours having  $\geq 5$  or  $\geq 1\%$  solid component and those having less. Similarly, significant differences were found in OS and DFS between various comparisons of tumours with solid component of 0,  $\leq 25$ , 26–50, 51–75 and  $> 75\%$ . Concerning a solid predominant component, significant differences were found between the OS and DFS estimates of solid predominant tumours and neoplasms without solid features. Despite the worsening tendency of OS and DFS with growing proportion of the solid pattern, there were no differences between tumours having secondly or thirdly predominant solid component and tumours without solid pattern. The mean proportion of solid pattern in tumours with recurrence was 48%, contrasting with the 5% in adenocarcinomas without recurrence. The micropapillary pattern has been incorporated in the adenocarcinoma classification since 2015. Although, according to the classification based on predominant pattern, it would seem that only the greatest proportion of this pattern matters, some studies (57-65) indicated that even a minimal amount of micropapillary area is associated with poor prognosis. Kamiya et al. found that both OS and DFS estimates were worse with the increase in the proportion of the micropapillary component (58). Zhang et al. have divided their patients into four groups according to the extent of micropapillary component, namely  $< 1$ , 1–5, 6–50 and  $> 51\%$ . Their conclusion was similar to that of Kamiya et al. (66). Our results also parallel these two cited studies. The tumours having more than 25% of micropapillary component formed a uniform group according to OS and DFS estimates and differed from tumours having 0–25% micropapillary area. When using the 5% cut-off for micropapillary component, a significant difference was observed in survival in comparison with tumours with no micropapillary component, while at 1% cut off point, such a difference was not found. In contrast with Sumiyoshi and coworkers (67), a difference was



observed between the groups of patients with and without recurrence: the mean proportions of micropapillary pattern were 13 and 4%, respectively. In the present study, a significant difference in survival was observed between tumours without micropapillary pattern and micropapillary predominant tumours. As our study showed, there is a broad spectrum of morphological intra-tumour heterogeneity in lung adenocarcinomas. Interestingly, the invasive tumours having only one component had a more unfavourable prognosis, than neoplasms having mixed pattern. This finding may be explained by the fact that most tumours having one component were solid tumours with poor outcome. Several series have concluded that this morphological heterogeneity is paralleled by a more complex genetic heterogeneity, as well. Instead of the traditional single-gene approaches, a huge number of genes can be analysed by next-generation sequencing.

The prognostic impact of predominant growth pattern was proven on the basis of measuring the area occupied by each pattern on all available (and digitalized) slides, i.e. the most precise way of determining the size of each component from the material available. We think that our study is unique in this respect. Tumours with a secondary predominant micropapillary component demonstrated significant differences in OS and DFS from micropapillary predominant tumours and non-micropapillary tumours. Therefore, we suggested using predominant and secondly predominant patterns particularly in tumours having solid (as suggested by others (20, 23, 53) or micropapillary (as proven by our data (34)) patterns. Our results are in tight correlation with the new proposed grading system of the lung adenocarcinomas by the Study of Lung Cancer (IASLC) Pathology Committee, which recommended to state all the adenocarcinomas containing at least 20% of solid, micropapillary or cribriform component to be high grade (68).

We have confirmed that lepidic predominant stage I adenocarcinomas have a good prognosis and solid or micropapillary predominant ones have the worst prognosis. A secondly predominant component of the bad prognostic patterns also worsen prognosis; therefore, the reporting of all patterns observed beyond the predominant component is recommended. Naked eye estimation of the proportions of each pattern does not seem to be worse than objective measurement on digitalised slides and can be used in routine practice (34).

Stage I lung cancer are tumors smaller than 3 cm without lymph node or distant metastases. The current TNM staging doesn't take into consideration the newly discovered invasion type of lung adenocarcinomas, the so called „Spread Through Air Spaces” (STAS), which has been extensively studied by Kadota et al. (69-75). It is defined as spread of cells

into air spaces in the lung parenchyma adjacent to the main tumor, histologically tumor cells within air spaces in the lung parenchyma beyond the edge of the main tumor. In their retrospective study the risk of developing any types (locoregional or distant) of recurrence was significantly higher in patients with STAS-positive tumors than in patients with STAS-negative tumors and STAS-positive tumors was significantly associated with worse overall survival (76). STAS was proved to be a significant prognostic factor for recurrence in patients undergoing limited resection. It was found in almost 40% of resected lung adenocarcinomas and observed tumor cells over 1 cm away from the edge of the tumor. STAS was found mostly in predominant micropapillary and solid adenocarcinomas, lepidic pattern was less frequently identified in STAS positive tumors. STAS is an insidious pattern of invasion, because it is not detectable by pathologists on macroscopic examination and by surgeons during surgery, and there is no radiological sign of it.

## **5. Study III.**

Tibor Géczi, Zsolt Simonka, Judit Lantos, Melinda Wetzel, Zsolt Szabó, György Lázár, József Furák. Near-infrared fluorescence guided surgery: State of the evidence from a health technology assessment perspective *Front. Surg.* 9:919739. DOI: 10.3389/fsurg.2022.919739

### **5.1. Materials and methods III.**

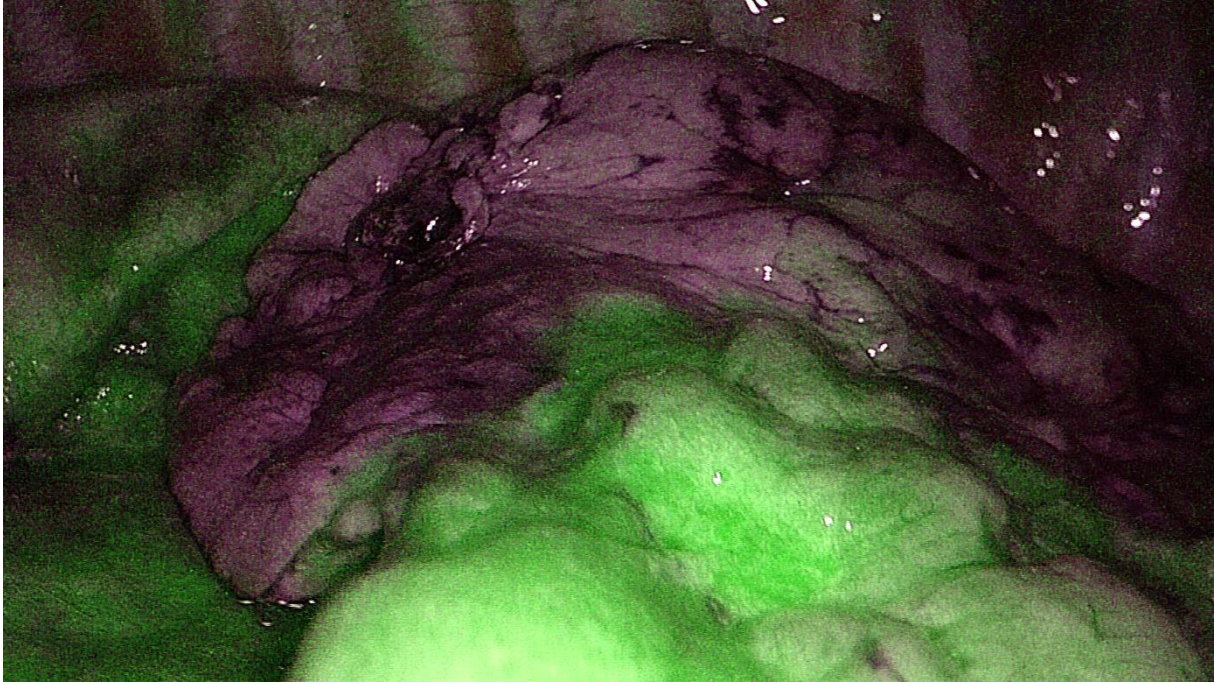In our mini-review, we summarized the use of NIR guided fluorescence surgery, focusing on the indocyanine green after careful evaluation of the current literature on this topic (Table 9).

LUNG						
	Study	Year	Dose	Administration route	Interval	Number of patients
<b>Intersegmental plane</b>	Misaki (77)	2009	25mg	iv.	30-90s	dogs
	Mun (78)	2017	0,25mg/kg		30-90s	22
	Guigard (79)	2017	25mg			24
	Meacci (80)	2018	12,5-17,5mg			
	Pschlik (81)	2018	0,15mg/kg			86
	Bedat (82)	2018	12,5mg			67
	Chen (83)	2019	25mg			19
	Jin (84)	2019	0,5mg/kg			21
	Motono (85)	2019	5mg			22
	Yotsukura (86)	2021	0,25mg/kg			209
	Sun (87)	2021	5mg			198
	Oh (88)	2013	25mg	intra	bronchial	40
	Wada (89)	2020	10-15mg	intra	bronchial	15
	Sekine (90)	2012	10mg	iv.		10
<b>Pulmonary nodule identification</b>	Doo (91)	2015	0,2ml	intra	tumoral inj.	34
	Ujie (92)	2017	0,15ml	intra	tumoral inj.	20
	Wen (93)	2018	0,5ml	intra	tumoral inj.	26
	Wu (94)	2021	1-2,5mg	intra	tumoral inj.	32
	Jiang (95)	2015	0,7-10mg/kg	iv.		1min-72h mice
	Okusanya (96)	2014	5mg/kg	iv.		24h 16
	Predina (97)	2017	OTL38:0,025mg/kg	iv.		3-6h 20
	Kim (98)	2016	1mg/kg			24h 11
	Hamaji (99)	2019	0,25mg/kg	iv.		12-24h 22
	Predina (97)	2019	5mg/kg	iv.		24h 30
<b>Sentinel lymph node</b>	Yamashita (100)	2011	10mg	peritumoral		10min 31
	Gilmore (101)	2021		peritumoral		before surgery 29
	Hachey (102)	2017	0,5ml	peritumoral (bronchoscopy)		before surgery 20
	Digesu (103)	2018	0,5ml	peritumoral		42
<b>Thoracic duct</b>	Kamiya (104)	2009	7,5mg	bilateral inguinal		14min 1 (case report)
	Matsutani (105)	2014	7,5mg	bilateral inguinal		10min 1 (case report)
	Vecchiato (106)	2020	1,5mg/kg	bilateral inguinal lymph nodes		10,5min 19

*Table 9. Literature review of the use of ICG in near-infrared fluorescence guided thoracic surgery (76-105)*

## 5.2. Results III.

Performing segmentectomy can be very difficult, mainly by thoracoscopy. As mentioned previously, traditionally, the inflation and deflation technique has been used for intersegmental plane identification, owing to difficulties in emphysematous lungs and obstruction of the surgical view mainly during VATS procedures. To avoid these problems, other techniques have been developed, such as selective bronchoscopic ventilation of the affected bronchus, inflation of the selected bronchus by instilling oxygen through a butterfly needle, slip-knot ligation of the bronchus, or selective dye administration into the segmental pulmonary bronchus or artery (107-111). In 2009, Misaki et al. conducted an experimental study on dogs and demonstrated the feasibility of intersegmental plain identification using near-infrared imaging after intravenous administration of ICG (25). During the surgery, immediately after the identification and division of the segmental arteries, ICG was injected through a peripheral vein (112-118) (Fig. 6.). In emphysematous and bullous lungs, the blood flow is lower than that in the normal lung; therefore, visualization is more problematic, requiring a repeat and a higher dose of ICG (79). All authors emphasized the importance of proper preoperative evaluation with multiplanar CT and 3D reconstruction to identify segmental arterial branches because anatomical variations are quite frequent. Bedat et al. reported that NIR angiography results modified the surgical technique in 10% of patients. Additional arterial branch ligation or more extensive parenchymal resection has been indicated (82). Although there is an animal study of intersegmental plane identification by direct injection of the dye into the segmental pulmonary arteries (106), there has been no study about using the fluorescence dye by this technique among clinical circumstances, and all authors have used the previously summarized negative staining method. ICG can also be injected into the segmental bronchi. Oh et al. reported about a segmentectomy technique (88). In their prospective study during video-assisted open lung segmentectomy, after ligation or stapling of the segmental artery, vein, and bronchus, they injected ICG into the peripheral bronchus; thus, they were able to visualize the intersegmental border not only at the lung surface but also in the deep lung parenchyma. This technique has not become popular, perhaps because it first requires the division of all hilar structures. Wada et al. used an ultrathin bronchoscope to inject ICG into the targeted segmental or subsegmental bronchus immediately after intubation (89).



*Fig. 6. Intersegmental plane identification using ICG during VATS segmentectomy (right 2nd segment segmentectomy, from own material)*

### **5.3. Discussion III:**

As we could see, after careful and proper patient selection segmentectomy can provide sufficient radicality and lung parenchyma preservation at the same time. Surgical trauma can be further minimized by VATS, which reduces the surgical trauma coming from surgical access and moreover non-intubated thoracic surgery (NITS) is able to lower the anaesthetic trauma coming from securing airway and artificial ventilation (122, 123). When performing segmentectomy, proper intersegmental plane identification is important, because thoracic surgeons want to achieve sufficient tumor-free margin and do not want to leave atelectatic, devitalized lung parenchyma in situ. The traditionally used inflation and deflation technique for intersegmental plane identification can be problematic in emphysematous lungs and might obstruct the surgical view, mainly during VATS procedures. NIR fluorescence surgery can provide an excellent alternative. During surgery, immediately after the identification and division of the segmental arteries, ICG is injected through a peripheral vein (24). Thanks to

this, the lung segment having no circulation will not show fluorescence and the border between this area and the lung parenchyma with normal circulation will be clearly visible. In emphysematous and bullous lungs, the blood flow is lower than that in the normal lung; therefore, visualization is more problematic, so a repeat and a higher dose of ICG might be required. All authors emphasized the importance of proper preoperative evaluation with multiplanar CT and 3D reconstruction to identify segmental arterial branches, because anatomical variations are quite frequent. In conclusion, NIR angiography is a safe, easy-to-reproduce, effective, and inexpensive method to improve the quality of VATS segmentectomy (24).

## **6. Summary of our 3 studies**

1. In summary, we can say, that in our first study we ascertained that the proportion and number of small-sized, early-stage lung cancers, mostly adenocarcinomas are continuously increasing in an older population with poorer lung function and general status.
2. At the same time the proportion of women is also rising in this population
3. The surgical practice accommodated to this tendency, there are more and more sublobar resections (and importantly segmentectomies) performed in this population
4. According to our second study, we showed that lepidic predominant carcinoma has a favourable prognosis, while predominant micropapillary and solid pattern suggests worse survival
5. We also suggested using predominant and secondly predominant patterns particularly in tumours having solid or micropapillary patterns, because these have their own individual effect on survival
6. In our third article we showed the usefulness of ICG and NIR fluorescence imaging in thoracic surgery, mainly in identification of intersegmental plane during segmentectomies

In our practice, after careful preoperative evaluation of the patient and images, we perform lung segmentectomy for patients with lymph node negative non-small cell lung cancer smaller than 2 cm, when the minimum 1 cm tumor-free margin can be achieved. If necessary, ICG and near-infrared fluorescence guidance is used for intersegmental plane identification.

## **6. ACKNOWLEDGEMENTS**

I would like to express my sincere gratitude to those who have supported me during my scientific work.

József Furák MD PhD, Head of the Division of Thoracic Surgery, Department of Surgery, University of Szeged, who gave me incredible help not only during writing the articles and the thesis, but during the daily work, who taught me the theory and practice of thoracic surgery. With his vast knowledge and continuous support he gave me a secure background in my research work. Thank him for his excellent scientific guidance he has provided since my undergraduate years.

Tamás Zombori MD, PhD, whose help was inevitable during the histopathological studies. Without this support it would have been extremely difficult for a surgeon to look into the depth of this science.

György Lázár, Professor and Head of the Department of Surgery, University of Szeged, and Member of the Hungarian Academy of Sciences, who provides me the chance to work as a surgeon and who has always encouraged me to do science work.

My colleagues and friends József Hóhn MD, PhD, László Libor MD and Tímea Óvári MD with whom working as a team is a great pleasure. Thank my co-authors for your indispensable help during this work.

I would also like to thank Dóra Somogyi for her endless patience and help in editing articles.

I wish to express my special gratitude to my family as well. They were always supported me and provided free time and calm atmosphere during scientific work.



## References

- 1, Global Cancer Observatory, <https://gco.iarc.fr/>
- 2, National Cancer Registry. [Nemzeti Rákregiszter.] Available from: <http://www.onkol.hu/hu/rakregiszter-statisztika> [accessed: October 3, 2017]. [Hungarian]
- 3, Di Maio M, Perrone F, Morabito A, et al. Epidemiology and aetiology of lung cancer. In: Kuzdzal J. (ed.) ESTS Textbook of Thoracic Surgery. Medycyna Praktyczna, Cracow, 2015; pp. 679–688.
4. Thoracic surgery in the everyday practice. [Epidemiológia. In: Csekeő A. (szerk.) Mellkassebészet a hétköznapi gyakorlatban.] Akadémiai Kiadó, Budapest, 2013; pp. 123–124. [Hungarian]
5. Kovács G. Screening. [Szűrővizsgálatok.] Korányi Bulletin 2015; 1: 21–26. [Hungarian]
6. Cahan WG. Radical lobectomy. *J Thoracic Cardiovasc Surg* 1960;39:555–72.
7. Pastorino U, Valente M, Bedini V, Infante M, Tavecchio L, Ravasi G. Limited resection for stage I lung cancer. *Eur J Surg Oncol* 1991; 17: 42–46.
8. R. Rami-Porta, M. Tsuboi. Sublobar resection for lung cancer. *European Respiratory Journal* 2009 33: 426-435. DOI: 10.1183/09031936.00099808
9. Ginsberg RJ, Rubinstein LV. Randomized trial of lobectomy versus limited resection for T1 N0 non-small cell lung cancer. Lung Cancer Study Group. *Ann Thoracic Surg* 1995;60:615–22discussion 22-3. DOI: 10.1016/0003-4975(95)00537-u
10. Rubinstein LV, Ginsberg RJ. Lobectomy versus limited resection in T1N0 lung cancer. *Ann Thorac Surg* 1996; 62: 1249–1250. DOI: 10.1016/0003-4975(96)85176-9
11. Nakamura H, Kawasaki N, Taguchi M, Kabasawa K. Survival following lobectomy vs limited resection for stage I lung cancer: ameta-analysis. *Br J Cancer* 2005; 92: 1033–1037. DOI: 10.1038/sj.bjc.6602414
12. Travis WD, Brambilla E, Nicholson AG, Yatabe Y, Austin JHM et al: The 2015 World Health Organization classification of lung tumors: impact of genetic, clinical and radiologic advances since the 2004 classification. *J Thorac Oncol* 10:1243–1260. <https://doi.org/10.1097/JTO.0000000000000630>

13. Yoshizawa A, Sumiyoshi S, Sonobe M, Kobayashi M, Fujimoto M, et al.: Validation of the IASLC/ATS/ERS lung adenocarcinoma classification for prognosis and association with EGFR and KRAS gene mutations: analysis of 440 Japanese patients. *J Thorac Oncol* 2013 8:52–61. DOI: 10.1097/JTO.0b013e3182769aa8
14. Ujiie H, Kadota K, Chaft JE, Buitrago D, Sima CS et al.: Solid predominant histologic subtype in resected stage I lung adenocarcinoma is an independent predictor of early, extrathoracic, multisite recurrence and of poor postrecurrence survival. *J Clin Oncol* 2015. 33:2877–2884. DOI: 10.1200/JCO.2015.60.9818
15. Mäkinen JM, Laitakari K, Johnson S, Mäkitaro R, Bloigu R, et al.: Nonpredominant lepidic pattern correlates with better outcome in invasive lung adenocarcinoma. *Lung Cancer* 2015;90:568–574. DOI: 10.1016/j.lungcan.2015.10.014
16. Miyoshi T, Satoh Y, Okumura S, Nakagawa K, Shirakusa T, et al.: Early-stage lung adenocarcinomas with a micropapillary pattern, a distinct pathologic marker for a significantly poor prognosis. *Am J Surg Pathol* 2003. 27:101–109. DOI: 10.1097/00000478-200301000-00011
17. Sánchez-Mora N, Presmanes MC, Monroy V, Moreno N, Lara- Martínez JM, et al: Micropapillary lung adenocarcinoma: a distinctive histologic subtype with prognostic significance. Case series. *Hum Pathol* 2008. 39:324–330. DOI: 10.1016/j.humpath.2007.05.029
18. Yeh YC, Wu YC, Chen CY, Wang LS, Hsu WH, et al: Stromal invasion and micropapillary pattern in 212 consecutive surgically resected stage I lung adenocarcinomas: histopathological categories for prognosis prediction. *J Clin Pathol* 2012. 65:910–918. DOI: 10.1136/jclinpath-2012-200882
19. Tsubokawa N, Mimae T, Sasada S, Yoshiya T, Mimura T, et al: Negative prognostic influence of micropapillary pattern in stage IA lung adenocarcinoma. *Eur J Cardiothorac Surg* 2015. 49:293–299. DOI: 10.1093/ejcts/ezv058
20. Yanagawa N, Shiono S, Abiko M, Katahira M, Osakabe M, et al: The clinical impact of solid and micropapillary patterns in resected lung adenocarcinoma. *J Thorac Oncol* 2016. 11:1976–1983. DOI: 10.1016/j.jtho.2016.06.014

21. Roh MS, Lee JI, Choi PJ, Hong Y. Relationship between micropapillary component and micrometastasis in the regional lymph nodes of patients with stage I lung adenocarcinoma. *Histopathology* 2004. 45:580–586. DOI: 10.1111/j.1365-2559.2004.01953.x
22. Shinji Sumiyoshi, Akihiko Yoshizawa, Makoto Sonobe, Masashi Kobayashi, Masakazu Fujimoto, et al. Pulmonary adenocarcinomas with micropapillary component significantly correlate with recurrence, but can be well controlled with EGFR tyrosine kinase inhibitors in the early stages. *Lung Cancer* 2013. 81:53–59. DOI: 10.1016/j.lungcan.2013.04.003
23. Zhao ZR, Xi SY, Li W, Situ DR, Chen KM, et al: Prognostic impact of pattern-based grading system by the new IASLC/ATS/ERS classification in Asian patients with stage I lung adenocarcinoma. *Lung Cancer* 2015. 90:604–609. DOI: 10.1016/j.lungcan.2015.10.026
24. Tibor Géczi, Zsolt Simonka, Judit Lantos, Melinda Wetzels, Zsolt Szabó, György Lázár, József Furák. Near-infrared fluorescence guided surgery: State of the evidence from a health technology assessment perspective *Front. Surg.* 9:919739. DOI: 10.3389/fsurg.2022.919739
25. Misaki N, Chang SS, Gotoh M, Yamamoto Y, Satoh K, Yokomise H. A novel method for determining adjacent lung segments with infrared thoracoscopy. *J Thorac Cardiovasc Surg.* (2009) 138:613–8. DOI: 10.1016/j.jtcvs.2009.01.003
26. Schaafsma BE, Mieog JS, Hutteman M, van der Vorst JR, Kuppen PJ, Löwik CW, et al. The clinical use of indocyanine green as a near-infrared fluorescent contrast agent for image-guided oncologic surgery. *J Surg Oncol.* (2011) 104:323–32. DOI: 10.1002/jso.21943
27. Chance B. Near-infrared images using continuous, phase-modulated, and pulsed light with quantitation of blood and blood oxygenation. *Ann N Y Acad Sci.* (1998) 838:29–45. DOI: 10.1111/j.1749-6632.1998.tb08185.x
28. Frangioni JV. In vivo near-infrared fluorescence imaging. *Curr Opin Chem Biol.* (2003) 7:626–34. DOI: 10.1016/j.cbpa.2003.08.007
29. Moody ED, Viskari PJ, Colyer CL. Non-covalent labeling of human serum albumin with indocyanine green: a study by capillary electrophoresis with diode laser-induced fluorescence detection. *J Chromatogr B Biomed Sci Appl.* (1999) 729:55–64. DOI: 10.1016/s0378-4347(99)00121-8

30. Okusanya OT, Hess NR, Luketich JD, Sarkaria IS. Infrared intraoperative fluorescence imaging using indocyanine green in thoracic surgery. *Eur J Cardiothorac Surg.* (2018) 53:512–8. DOI: 10.1093/ejcts/ezx352
31. De Grand AM, Lomnes SJ, Lee DS, Pietrzykowski M, Ohnishi S, Morgan TG, et al. Tissue-like phantoms for near-infrared fluorescence imaging system assessment and the training of surgeons. *J Biomed Opt.* (2006) 11:014007. DOI: 10.1117/1.2170579
32. Luo S, Zhang E, Su Y, Cheng T, Shi C. A review of NIR dyes in cancer targeting and imaging. *Biomaterials.* (2011) 32:7127–38. DOI: 10.1016/j.biomaterials.2011.06.024
33. Géczi, Tibor, Csada, Edit, Tiszlavicz, László, Lázár, György, Furák, József A műtétiileg kezelt tüdőrák klinikopatológiai jellemzőinek változása az ezredfordulónkon [Changes in the clinicopathological features of surgically treated lung cancer around the millennium] *ORVOSI HETILAP* 159 : 10 pp. 391-396. 6 p. (2018) DOI: WoS Scopus PubMed Matarka MOB SZTE Publicatio
34. Tamás Zombori, Tibor Nyári, László Tiszlavicz, Regina Pálföldi, Edit Csada , Tibor Géczi, Aurél Otlakán, Balázs Pécsy, Gábor Cserni, József Furák. The more the micropapillary pattern in stage I lung adenocarcinoma, the worse the prognosis-a retrospective study on digitalized slides *Virchows Archives* 472, pages949–958 (2018) DOI: 10.1007/s00428-018-2337-x
35. Furák J, Troján I, Szőke T, et al. Lung cancer as a second primary malignant tumor: prognostic values after surgical resection. *Interact Cardiovasc Thorac Surg.* 2008; 7: 50–53. DOI: 10.1510/icvts.2007.160846
36. Database Reports. Available from:  
[http://www.ests.org/collaboration/database\\_reports.aspx](http://www.ests.org/collaboration/database_reports.aspx) [accessed: October 3, 2017]
37. Fernando HC, Landreneau RJ, Mandrekar SJ, et al. The impact of adjuvant brachytherapy with sublobar resection on pulmonary function and dyspnea in high-risk patients with operable disease: preliminary results from the American College of Surgeons Oncology Group Z4032 trial. *J Thorac Cardiovasc Surg* 2011;142:554-62. DOI: 10.1016/j.jtcvs.2010.10.061
38. Dolan DP, Swanson SJ. Sublobar resection in high-risk patients for lobectomy: current and future strategy. *Mini-invasive Surg* 2021;5:3. <http://dx.doi.org/10.20517/2574-1225.2020.101>

39. Mery CM, Pappas AN, Bueno R, et al. Similar long-term survival of elderly patients with non-small cell lung cancer treated with lobectomy or wedge resection within the Surveillance, Epidemiology, and End Results database. *Chest* 2005;128:237–245. DOI: 10.1378/chest.128.1.237
40. El-Sherif A, Gooding WE, Santos R, et al. Outcomes of sublobar resection versus lobectomy for stage I non-small cell lung cancer: a 13-year analysis. *Ann Thorac Surg* 2006;82:408–416. DOI: 10.1016/j.athoracsur.2006.02.029
41. Okumura M, Goto M, Ideguchi K, et al. Factors associated with outcome of segmentectomy for non-small cell lung cancer: long-term follow-up study at a single institution in Japan. *Lung Cancer* 2007;58:231–237. DOI: 10.1016/j.lungcan.2007.06.014
42. Rami-Porta R, Tsuboi M. Sublobar resection for lung cancer. *Eur Respir J*. 2009 Feb;33(2):426-35. DOI: 10.1183/09031936.00099808.
43. Siene W, Dango S, Kirschbaum A, et al. Sublobar resections in stage IA non-small cell lung cancer: segmentectomies result in significantly better cancer-related survival than wedge resections. *Eur J Cardiothorac Surg* 2008;33:728–734. DOI: 10.1016/j.ejcts.2007.12.048
44. Aokage K, Yoshida J, Hishida T, Tsuboi M, Saji H et al. Limited resection for early-stage non-small cell lung cancer as function-preserving radical surgery: a review *Jpn J Clin Oncol*. 2017 Jan;47(1):7-11. doi: 10.1093/jjco/hyw148.
45. Saji H, Okada M, Tsuboi M, Nakajima R, Suzuki K et al. Segmentectomy versus lobectomy in small-sized peripheral non-small-cell lung cancer (JCOG0802/WJOG4607L): a multicentre, open-label, phase 3, randomised, controlled, non-inferiority trial *Lancet* 2022; 399: 1607–17.
46. El-Sherif A, Fernando HC, Ricardo S, Pettiford B, Luketich JD et al. Margin and Local Recurrence After Sublobar Resection of Non-Small Cell Lung Cancer *Annals of Surgical Oncology* 14(8):2400–2405 DOI: 10.1245/s10434-007-9421-9
47. Ohde Y, Nagai K, Yoshida J, et al. The proportion of consolidation to ground-glass opacity on high resolution CT is a good predictor for distinguishing the population of non-invasive peripheral adenocarcinoma. *Lung cancer* 2003;42:303–10. DOI: 10.1016/j.lungcan.2003.07.001

48. Suzuki K, Asamura H, Kusumoto M, et al. 'Early' peripheral lung cancer: Prognostic significance of ground glass opacity on thin-section computed tomographic scan. *Ann Thoracic Surg* 2002;74:1635–9. DOI: 10.1016/s0003-4975(02)03895-x
49. Jang HJ, Lee KS, Kwon OJ, et al. Bronchioloalveolar carcinoma: focal area of ground-glass attenuation at thin-section CT as an early sign. *Radiology* 1996;199:485–8. DOI: 10.1148/radiology.199.2.8668800
50. Kodama K, Higashiyama M, Yokouchi H, et al. Prognostic value of ground-glass opacity found in small lung adenocarcinoma on highresolution CT scanning. *Lung Cancer* 2001;33:17–25. DOI: 10.1016/s0169-5002(01)00185-4
51. Aoki T, Tomoda Y, Watanabe H, et al. Peripheral lung adenocarcinoma: correlation of thin-section CT findings with histologic prognostic factors and survival. *Radiology* 2001;220:803–9. DOI: 10.1148/radiol.2203001701
52. Suzuki K, Koike T, Asakawa T, et al. A prospective radiological study of thin-section computed tomography to predict pathological noninvasiveness in peripheral clinical IA lung cancer (Japan Clinical Oncology Group 0201). *J Thoracic Oncol* 2011;6:751–6. DOI: 10.1097/JTO.0b013e31821038ab
53. Jiang W, Xi J, Xu S, Lu S, Wang Q (2015) Analysis of the effect of different pathological subtypes to prognosis in stage I pulmonary adenocarcinoma. *Zhonghua Wai Ke Za Zhi* 53:737–741 [abstract only]
54. Cha MJ, Lee HY, Lee KS, Jeong JY, Han J, Shim YM, Hwang HS (2014) Micropapillary and solid subtypes of invasive lung adenocarcinoma: clinical predictors of histopathology and outcome. *J Thorac Cardiovasc Surg* 147:921–928. DOI: 10.1016/j.jtcvs.2013.09.045
55. Yanagawa N, Shiono S, Abiko M, Katahira M, Osakabe M, Ogata SY (2016) The clinical impact of solid and micropapillary patterns in resected lung adenocarcinoma. *J Thorac Oncol* 11:1976–1983. DOI: 10.1016/j.jtho.2016.06.014
56. Zhao ZR, Xi SY, Li W, Situ DR, Chen KM, Yang H, Su XD, Lin YB, Long H (2015) Prognostic impact of pattern-based grading system by the new IASLC/ATS/ERS classification in Asian patients with stage I lung adenocarcinoma. *Lung Cancer* 90:604–609. DOI: 10.1016/j.lungcan.2015.10.026

57. Nitadori J, Bograd AJ, Kadota K, Sima CS, Rizk NP, Morales EA, Rusch VW, Travis WD, Adusumilli PS (2013) Impact of micropapillary histologic subtype in selecting limited resection vs lobectomy for lung adenocarcinoma of 2 cm or smaller. *J Natl Cancer Inst* 105:1212–1220. DOI: 10.1093/jnci/djt166
58. Kamiya K, Hayashi Y, Douguchi J, Hashiguchi A, Yamada T, Izumi Y, Watanabe M, Kawamura M, Horinouchi H, Shimada N, Kobayashi K, Sakamoto M (2008) Histopathological features and prognostic significance of the micropapillary pattern in lung adenocarcinoma. *Mod Pathol* 21:992–1001. DOI: 10.1038/modpathol.2008.79
59. Nagano T, Kim YH, Goto K, Kubota K, Ohmatsu H, Niho S, Yoh K, Naito Y, Saijo N, Nishiwaki Y (2009) Re-challenge chemotherapy for relapsed non-small-cell lung cancer. *Lung Cancer* 69:315– 318. DOI: 10.1016/j.lungcan.2009.11.016
60. Cha MJ, Lee HY, Lee KS, Jeong JY, Han J, Shim YM, Hwang HS (2014) Micropapillary and solid subtypes of invasive lung adenocarcinoma: clinical predictors of histopathology and outcome. *J Thorac Cardiovasc Surg* 147:921–928. DOI: 10.1016/j.jtcvs.2013.09.045
61. Miyoshi T, Satoh Y, Okumura S, Nakagawa K, Shirakusa T, Tsuchiya E, Ishikawa Y (2003) Early-stage lung adenocarcinomas with a micropapillary pattern, a distinct pathologic marker for a significantly poor prognosis. *Am J Surg Pathol* 27:101–109. DOI: 10.1097/00000478-200301000-00011
62. Sánchez-Mora N, Presmanes MC, Monroy V, Moreno N, Lara- Martínez JM, Aladro MH, Alvarez-Fernández E (2008) Micropapillary lung adenocarcinoma: a distinctive histologic subtype with prognostic significance. Case series. *Hum Pathol* 39:324– 330. DOI: 10.1016/j.humpath.2007.05.029
63. Yeh YC, Wu YC, Chen CY, Wang LS, Hsu WH, Chou TY (2012) Stromal invasion and micropapillary pattern in 212 consecutive surgically resected stage I lung adenocarcinomas: histopathological categories for prognosis prediction. *J Clin Pathol* 65:910–918. DOI: 10.1136/jclinpath-2012-200882
64. Tsubokawa N, Mimae T, Sasada S, Yoshiya T, Mimura T, Murakami S, Ito H, Miyata Y, Nakayama H, Okada M (2015) Negative prognostic influence of micropapillary pattern in stage IA lung adenocarcinoma. *Eur J Cardiothorac Surg* 49:293–299. DOI: 10.1093/ejcts/ezv058

65. Yanagawa N, Shiono S, Abiko M, Katahira M, Osakabe M, Ogata SY (2016) The clinical impact of solid and micropapillary patterns in resected lung adenocarcinoma. *J Thorac Oncol* 11:1976–1983. DOI: 10.1016/j.jtho.2016.06.014
66. Zhang J, Liang Z, Gao J, Luo Y, Liu T (2011) Pulmonary adenocarcinoma with a micropapillary pattern: a clinicopathological immunophenotypic and molecular analysis. *Histopathology* 59:1204–1214. DOI: 10.1111/j.1365-2559.2011.04050.x
67. Sumiyoshi S, Yoshizawa A, Sonobe M, Kobayashi M, Fujimoto M, Tsuruyama T, Date H, Haga H (2013) Pulmonary adenocarcinomas with micropapillary component significantly correlate with recurrence, but can be well controlled with EGFR tyrosine kinase inhibitors in the early stages. *Lung Cancer* 81:53–59. DOI: 10.1016/j.lungcan.2013.04.003
- 68 C Weng, C Huang, S Huang, M Wu, A Tseng, et al. New International Association for the Study of Lung Cancer (IASLC) Pathology Committee Grading System for the Prognostic Outcome of Advanced Lung Adenocarcinoma Cancers (Basel) 2020 Nov 18;12(11):3426. doi: 10.3390/cancers12113426
69. Kadota K, Suzuki K, Kachala SS, et al. A grading system combining architectural features and mitotic count predicts recurrence in stage I lung adenocarcinoma. *Mod Pathol.* 2012; 25(8):1117–1127. DOI: 10.1038/modpathol.2012.58
70. Kadota K, Villena-Vargas J, Yoshizawa A, et al. Prognostic significance of adenocarcinoma in situ, minimally invasive adenocarcinoma, and nonmucinous lepidic predominant invasive adenocarcinoma of the lung in patients with stage I disease. *Am J Surg Pathol.* 2014; 38(4):448–460. DOI: 10.1097/PAS.0000000000000134
71. Kadota K, Yeh YC, Sima CS, et al. The cribriform pattern identifies a subset of acinar predominant tumors with poor prognosis in patients with stage I lung adenocarcinoma: a conceptual proposal to classify cribriform predominant tumors as a distinct histologic subtype. *Mod Pathol.* 2014; 27(5):690–700. DOI: 10.1038/modpathol.2013.188
72. Kadota K, Yeh Y-C, D'Angelo SP, et al. Associations between mutations and histologic patterns of mucin in lung adenocarcinoma: Invasive mucinous pattern and extracellular mucin are associated with KRAS mutation. *Am J Surg Pathol.* 2014; 38(8):1118–1127. DOI: 10.1097/PAS.0000000000000246
73. Kadota K, Nitadori J, Sarkaria IS, et al. Thyroid transcription factor-1 expression is an independent predictor of recurrence and correlates with the IASLC/ATS/ERS histologic



classification in patients with stage I lung adenocarcinoma. *Cancer*. 2013; 119(5):931–938. DOI: 10.1002/cncr.27863

74. Nitadori J, Bograd AJ, Kadota K, et al. Impact of micropapillary histologic subtype in selecting limited resection vs lobectomy for lung adenocarcinoma of 2cm or smaller. *J Natl Cancer Inst*. 2013; 105(16):1212–1220. DOI: 10.1093/jnci/djt166

75. Suzuki K, Kadota K, Sima CS, et al. Clinical Impact of Immune Microenvironment in Stage I Lung Adenocarcinoma: Tumor Interleukin-12 Receptor beta2 (IL-12Rbeta2), IL-7R, and Stromal FoxP3/CD3 Ratio Are Independent Predictors of Recurrence. *J Clin Oncol*. 2013; 31(4):490–498. DOI: 10.1200/JCO.2012.45.2052

76. Kadota K, Nitadori J, Sima C, Ujiie H, Rizk N. et al. Tumor Spread Through Air Spaces is an Important Pattern of Invasion and Impacts the Frequency and Location of Recurrences Following Limited Resection for Small Stage I Lung Adenocarcinomas *J Thorac Oncol*. 2015 May ; 10(5): 806–814. DOI:10.1097/JTO.0000000000000486.

77. Misaki N, Chang SS, Gotoh M, Yamamoto Y, Satoh K, Yokomise H. A novel method for determining adjacent lung segments with infrared thoracoscopy. *J Thorac Cardiovasc Surg*. (2009) 138:613–8. DOI: 10.1016/j.jtcvs.2009.01.003

78. Mun M, Okumura S, Nakao M, Matsuura Y, Nakagawa K. Indocyanine green fluorescence-navigated thoracoscopic anatomical segmentectomy. *J Vis Surg*. (2017) 3:80. DOI: 10.21037/jovs.2017.05.06

79. Guigard S, Triponez F, Bédard B, Vidal-Fortuny J, Licker M, Karenovics W. Usefulness of near-infrared angiography for identifying the intersegmental plane and vascular supply during video-assisted thoracoscopic segmentectomy. *Interact Cardiovasc Thorac Surg*. (2017) 25:703–9. DOI: 10.1093/icvts/ivx225

80. Meacci E, Nachira D, Congedo MT, Chiappetta M, Petracca Ciavarella LP, Margaritora S. Uniportal video-assisted thoracic lung segmentectomy with near infrared/indocyanine green intersegmental plane identification. *J Vis Surg*. (2018) 4:17. DOI: 10.21037/jovs.2017.12.16

81. Pischik VG, Kovalenko A. The role of indocyanine green fluorescence for intersegmental plane identification during video-assisted thoracoscopic surgery segmentectomies. *J Thorac Dis*. (2018) 10(Suppl 31):S3704–11. DOI: 10.21037/jtd.2018.04.84

82. Bédât B, Triponez F, Sadowski SM, Ellenberger C, Licker M, Karenovics W. Impact of near-infrared angiography on the quality of anatomical resection during video-assisted thoracic surgery segmentectomy. *J Thorac Dis.* (2018) 10(Suppl 10): S1229–34. DOI: 10.21037/jtd.2018.01.29
83. Chen R, Ma Y, Li C, Li Y, Yang B, Guo J, et al. A pilot study of pulmonary segmentectomy with indocyanine green near-infrared angiography. *Surg Innov.* (2019) 26:337–43. DOI: 10.1177/1553350618824914
84. Jin Y, Wang M, Xue L, Zhao X. Clinical application of near-infrared thoracoscopy with indocyanine green in video-assisted thoracoscopic anatomical segmentectomy. *Surg Innov.* (2019) 26:473–7. DOI: 10.1177/1553350619848197
85. Motono N, Iwai S, Funasaki A, Sekimura A, Usuda K, Uramoto H. Low-dose indocyanine green fluorescence-navigated segmentectomy: prospective analysis of 20 cases and review of previous reports. *J Thorac Dis.* (2019) 11:702–7. DOI: 10.1037/jtd.2019.02.70
86. Yotsukura M, Okubo Y, Yoshida Y, Nakagawa K, Watanabe SI. Indocyanine green imaging for pulmonary segmentectomy. *JTCVS Tech.* (2021) 6:151–8. DOI: 10.1016/j.xjtc.2020.12.005
87. Sun Y, Zhang Q, Wang Z, Shao F, Yang R. Feasibility investigation of near-infrared fluorescence imaging with intravenous indocyanine green method in uniport video-assisted thoracoscopic anatomical segmentectomy for identifying the intersegmental boundary line. *Thorac Cancer.* (2021) 12:1407–14. DOI: 10.1111/1759-7714.13923
88. Oh S, Suzuki K, Miyasaka Y, Matsunaga T, Tsushima Y, Takamochi K. New technique for lung segmentectomy using indocyanine green injection. *Ann Thorac Surg.* (2013) 95:2188–90. DOI: 10.1016/j.athoracsur.2012.12.068
89. Wada H, Yamamoto T, Morimoto J, Sakairi Y, Suzuki H, Nakajima T, et al. Near-infrared-guided pulmonary segmentectomy after endobronchial indocyanine green injection. *Ann Thorac Surg.* (2020) 109:396–403. DOI: 10.1016/j.athoracsur.2019.08.083
90. Sekine Y, Ko E, Oishi H, Miwa M. A simple and effective technique for identification of intersegmental planes by infrared thoracoscopy after transbronchial injection of indocyanine green. *J Thorac Cardiovasc Surg.* (2012) 143:1330–5. DOI: 10.1016/j.jtcvs.2012.01.079

91. Doo KW, Yong HS, Kim HK, Kim S, Kang EY, Choi YH. Needlescopic resection of small and superficial pulmonary nodule after computed tomographic fluoroscopy-guided dual localization with radiotracer and hookwire. *Ann Surg Oncol.* (2015) 22:331–7. DOI: 10.1245/s10434-014-3884-2
92. Ujiie H, Kato T, Hu HP, Patel P, Wada H, Fujino K, et al. A novel minimally invasive near-infrared thoracoscopic localization technique of small pulmonary nodules: a phase I feasibility trial. *J Thorac Cardiovasc Surg.* (2017) 154:702–11. DOI: 10.1016/j.jtcvs.2017.03.140
93. Wen CT, Liu YY, Fang HY, Hsieh MJ, Chao YK. Image-guided videoassisted thoracoscopic small lung tumor resection using near-infrared marking. *Surg Endosc.* (2018) 32:4673–80. DOI: 10.1007/s00464-018-6252-7
94. Wu Z, Zhang L, Zhao XT, Zhou D, Yang XY. Localization of subcentimeter pulmonary nodules using an indocyanine green near-infrared imaging system during uniportal video-assisted thoracoscopic surgery. *J Cardiothorac Surg.* (2021) 16:224. DOI: 10.1186/s13019-021-01603-x
95. Jiang JX, Keating JJ, Jesus EM, Judy RP, Madajewski B, Venegas O, et al. Optimization of the enhanced permeability and retention effect for nearinfrared imaging of solid tumors with indocyanine green. *Am J Nucl Med Mol Imaging.* (2015) 5:390–400.
96. Okusanya OT, Holt D, Heitjan D, Deshpande C, Venegas O, Jiang J, et al. Intraoperative near-infrared imaging can identify pulmonary nodules. *Ann Thorac Surg.* (2014) 98:1223–30. doi: 10.1016/j.athoracsur.2014.05.026. DOI: 10.1016/j.athoracsur.2014.05.026
97. Predina JD, Newton AD, Keating J, Dunbar A, Connolly C, Baldassari M, et al. A phase I clinical trial of targeted intraoperative molecular imaging for pulmonary adenocarcinomas. *Ann Thorac Surg.* (2018) 105:901–8. DOI: 10.1016/j.athoracsur.2017.08.062
99. Kim HK, Quan YH, Choi BH, Park JH, Han KN, Choi Y, et al. Intraoperative pulmonary neoplasm identification using near-infrared fluorescence imaging. *Eur J Cardiothorac Surg.* (2016) 49:1497–502. DOI: 10.1093/ejcts/ezv367
99. Hamaji M, Chen-Yoshikawa TF, Minami M, Date H. Near-infrared imaging using intravenous indocyanine green at a conventional dose to locate pulmonary metastases: a pilot study. *Thorac Cardiovasc Surg.* (2019) 67:688–91. DOI: 10.1055/s-0038-1675346

100. Yamashita S, Tokuishi K, Anami K, Miyawaki M, Moroga T, Kamei M, et al. Video-assisted thoracoscopic indocyanine green fluorescence imaging system shows sentinel lymph nodes in non-small-cell lung cancer. *J Thorac Cardiovasc Surg.* (2011) 141:141–4. DOI: 10.1016/j.jtcvs.2010.01.028
101. Gilmore DM, Khullar OV, Colson YL. Developing intrathoracic sentinel lymph node mapping with near-infrared fluorescent imaging in non-small cell lung cancer. *J Thorac Cardiovasc Surg.* (2012) 144:S80–4. DOI: 10.1016/j.jtcvs.2012.05.072
102. Hachey KJ, Digesu CS, Armstrong KW, Gilmore DM, Khullar OV, Whang B, et al. A novel technique for tumor localization and targeted lymphatic mapping in early stage lung cancer. *J Thorac Cardiovasc Surg.* (2017) 154:1110–8. DOI: 10.1016/j.jtcvs.2016.12.058
103. Digesu CS, Weiss KD, Colson YL. Near-infrared sentinel lymph node identification in non-small cell lung cancer. *JAMA Surg.* (2018) 153:487–8. DOI: 10.1001/jamasurg.2017.5928
104. Kamiya K, Unno N, Konno H. Intraoperative indocyanine green fluorescence lymphography, a novel imaging technique to detect a chyle fistula after an esophagectomy: report of a case. *Surg Today.* (2009) 39:421–4. DOI: 10.1007/s00595-008-3852-1
105. Matsutani T, Hirakata A, Nomura T, Hagiwara N, Matsuda A, Yoshida H, et al. Transabdominal approach for chylothorax after esophagectomy by using fluorescence navigation with indocyanine green. *Case Rep Surg.* (2014) 2014:464017. DOI: 10.1155/2014/464017
106. Vecchiato M, Martino A, Sponza M, Uzzau A, Ziccarelli A, Marchesi F, et al. Thoracic duct identification with indocyanine green fluorescence during minimally invasive esophagectomy with patient in prone position. *Dis Esophagus.* (2020) 33:1–6. DOI: 10.1093/dote/daaa030
107. Okada M, Mimura T, Ikegaki J, Katoh H, Itoh H, Tsubota N. A novel videoassisted anatomic segmentectomy technique: selective segmental inflation via bronchofiberoptic jet followed by cautery cutting. *J Thorac Cardiovasc Surg.* (2007) 133:753–8. DOI: 10.1016/j.jtcvs.2006.11.005
108. Kamiyoshihara M, Kakegawa S, Morishita Y. Convenient and improved method to distinguish the intersegmental plane in pulmonary segmentectomy using a butterfly needle. *Ann Thorac Surg.* (2007) 83:1913–4. DOI: 10.1016/j.athoracsur.2006.06.052

109. Oizumi H, Kato H, Endoh M, Inoue T, Watarai H, Sadahiro M. Slip knot bronchial ligation method for thoracoscopic lung segmentectomy. *Ann Thorac Surg.* (2014) 97:1456–8. DOI: 10.1016/j.athoracsur.2013.07.125
110. Sugimoto S, Oto T, Miyoshi K, Miyoshi S. A novel technique for identification of the lung intersegmental plane using dye injection into the segmental pulmonary artery. *J Thorac Cardiovasc Surg.* (2011) 141:1325–7. DOI: 10.1016/j.jtcvs.2010.09.029
111. Sekine Y, Ko E, Oishi H, Miwa M. A simple and effective technique for identification of intersegmental planes by infrared thoracoscopy after transbronchial injection of indocyanine green. *J Thorac Cardiovasc Surg.* (2012) 143:1330–5. DOI: 10.1016/j.jtcvs.2012.01.079
112. Mun M, Okumura S, Nakao M, Matsuura Y, Nakagawa K. Indocyanine green fluorescence-navigated thoracoscopic anatomical segmentectomy. *J Vis Surg.* (2017) 3:80. DOI: 10.21037/jovs.2017.05.06
113. Guigard S, Triponez F, Bédard B, Vidal-Fortuny J, Licker M, Karenovics W. Usefulness of near-infrared angiography for identifying the intersegmental plane and vascular supply during video-assisted thoracoscopic segmentectomy. *Interact Cardiovasc Thorac Surg.* (2017) 25:703–9. DOI: 10.1093/icvts/ivx225
114. Meacci E, Nachira D, Congedo MT, Chiappetta M, Petracca Ciavarella LP, Margaritora S. Uniportal video-assisted thoracic lung segmentectomy with near infrared/indocyanine green intersegmental plane identification. *J Vis Surg.* (2018) 4:17. DOI: 10.21037/jovs.2017.12.16
115. Pischik VG, Kovalenko A. The role of indocyanine green fluorescence for intersegmental plane identification during video-assisted thoracoscopic surgery segmentectomies. *J Thorac Dis.* (2018) 10(Suppl 31): S3704–11. DOI: 10.21037/jtd.2018.04.84
116. Bédard B, Triponez F, Sadowski SM, Ellenberger C, Licker M, Karenovics W. Impact of near-infrared angiography on the quality of anatomical resection during video-assisted thoracic surgery segmentectomy. *J Thorac Dis.* (2018) 10(Suppl 10): S1229–34. DOI: 10.21037/jtd.2018.01.29
117. Chen R, Ma Y, Li C, Li Y, Yang B, Guo J, et al. A pilot study of pulmonary segmentectomy with indocyanine green near-infrared angiography. *Surg Innov.* (2019) 26:337–43. DOI: 10.1177/1553350618824914

118. Jin Y, Wang M, Xue L, Zhao X. Clinical application of near-infrared thoracoscopy with indocyanine green in video-assisted thoracoscopic anatomical segmentectomy. *Surg Innov.* (2019) 26:473–7. DOI: 10.1177/1553350619848197
119. Motono N, Iwai S, Funasaki A, Sekimura A, Usuda K, Uramoto H. Low-dose indocyanine green fluorescence-navigated segmentectomy: prospective analysis of 20 cases and review of previous reports. *J Thorac Dis.* (2019) 11:702–7. DOI: 10.21037/jtd.2019.02.70
120. Oh S, Suzuki K, Miyasaka Y, Matsunaga T, Tsushima Y, Takamochi K. New technique for lung segmentectomy using indocyanine green injection. *Ann Thorac Surg.* (2013) 95:2188–90. DOI: 10.1016/j.athoracsur.2012.12.068
121. Wada H, Yamamoto T, Morimoto J, Sakairi Y, Suzuki H, Nakajima T, et al. Near-infrared-guided pulmonary segmentectomy after endobronchial indocyanine green injection. *Ann Thorac Surg.* (2020) 109:396–403. DOI: 10.1016/j.athoracsur.2019.08.083
122. Furák J, Németh T, Lantos J, Fabó Cs, Géczi T et al. Perioperative Systemic Inflammation in Lung Cancer Surgery *Front Surg* 2022; 9: 883322. Published online 2022 May 20. DOI: 10.3389/fsurg.2022.883322
123. Szabo Zs, Fabo Cs, Oszlanyi A, Hawchar F, Géczi T et al. Anesthetic (r)evolution from the conventional concept to the minimally invasive techniques in thoracic surgery—narrative review *J Thorac Dis* 2022;14(8):3045-3060 DOI: 10.1200/JCO.2012.45.2052