Functional outcomes of endoscopic arytenoid abduction lateropexy in patients with vocal cord palsy

PhD Thesis

Vera Matievics MD

Szeged

2018

Functional outcomes of endoscopic arytenoid abduction lateropexy in patients with vocal cord palsy

PhD Thesis

Vera Matievics MD
Department of Oto-Rhino-Laryngology, Head and Neck Surgery
University of Szeged

University of Szeged, Faculty of Medicine
Clinical Medical Sciences Doctoral School

PhD Program:
Clinical and Experimental Research for Reconstructive and Organ-sparing Surgery

Program director: György Lázár MD, CSc
Supervisor: László Rovó MD, PhD
Balázs Sztanó MD, PhD

Szeged
2018

PUBLICATIONS related to the PhD Thesis

I. **Matievics V**, Bach A, Sztano B, Bere Zs, Tobias Z, Castellanos PF, Mueller AH, Rovo L

Functional outcomes of endoscopic arytenoid abduction lateropexy for unilateral vocal cord palsy with dyspnea

European Archives of Oto-Rhino-Laryngology 274: (10) pp. 3703-3710. (2017)

IF: 1.660*

II. Matievics V, Bach Á, Sztanó B, Rovó L

Endoszkópos arytenoid abdukciós lateropexia foniátriai eredményei nehézlégzéssel járó féloldali gégebénulás esetén

Fül-Orr-Gégegyógyászat 64 (3): 74–77 (2018)

III. **Matievics V**, Sztanó B, Bach Á, Rovó L

Endoszkópos arytenoid abdukciós lateropexia foniátriai eredményei átmeneti kétoldali gégebénulás esetén

Phoniatric outcomes of endoscopic arytenoid abduction lateropexy for unilateral vocal cord palsy with dyspnea

Orvosi Hetilap 159(29):1188-1192. doi: 10.1556/650.2018.31099 (2018)

IF: 0.340*

IV. Szakacs L, Sztano B, **Matievics V**, Bere Z, Bach A, Castellanos PF, Rovo L

A comparison between transoral glottis-widening techniques for bilateral vocal fold immobility

Laryngoscope 125:(11) pp. 2522-2529. (2015)

IF: 2.272

PUBLICATION not directly related to the PhD thesis:

I. Madani S, Bach A, **Matievics V**, Erdelyi E, Sztano B, Szegesdi I, Castellanos PF, Rovó L

A new solution for neonatal bilateral vocal cord palsy: Endoscopic arytenoid abduction lateropexy

Laryngoscope 127: (7) pp. 1608-1614. (2017)

IF: 2.471*

II. Tóth F, Balogh Norbert, Szakáll Beáta, Dimák B, Nagy R, Szamosközi A, Perényi Á, Jarabin J, **Matievics V**, Jóri J, Rovó L, Kiss J G

Cochlearis implantált betegek hallásának monitorozása hearlab-rendszerrel

Fül-Orr-Gégegyógyászat 63:(3) p. 153. (2017)

III. Palinko D, **Matievics V**, Szegesdi I, Sztano B, Rovo L

Minimally invasive endoscopic treatment for pediatric combined high grade stenosis as a laryngeal manifestation of epidermolysis bullosa

International Journal of Pediatric Otorhinolaryngology 92: pp. 126-129. (2017)

IF: 1.159*

IV. Rovo L , Bach A , Sztano B, **Matievics V**, Szegesdi I, Castellanos PF

Rotational thyrotracheopexy after cricoidectomy for low-grade laryngeal chrondrosarcoma

Laryngoscope 127: (5) pp. 1109-1115. (2017)

IF: 2.471*

V. Bach Á, Csanády M, Bella Zs, **Matievics V**, Rovó L

Kiterjesztett laser chordectomiat követő endolaryngealis hangszalag medialisatio septum nasi porccal

Fül-Orr-Gégegyógyászat 61: (3) pp. 103-106. (2015)

VI. Bach Á, Tóth F**, Matievics V**, Kiss J G, Jóri J, Szakál B, Balogh N, Soós A, Rovó L

Új lehetőség az akusztikusan kiváltott corticalis válaszok mérésére: a HEARLab

Orvosi Hetilap 155: (38) pp. 1524-1529. (2014)

VII. Jarabin J, Matievics V, Tóth F, Rovó L, Kiss J G

A BAHA implantációt megelőző audiometriai és betegelégedettségi tesztek értékelése, és összehasonlítása a hagyományos csontvezetéses hallókészülékekkel elérhető eredményekkel

Fül-Orr-Gégegyógyászat 58: (2) pp. 60-63. (2012)

CITABLE ABSTRACTS

I. Molnár G, Ponyi-Lázár G, Tóth P**, Matievics V**, Kiss JG

Játék-audiometria új lehetősége 3 éves kortól

Fül-Orr-Gégegyógyászat 63:(3) pp. 149-150. (2017)

II. **Matievics V**, Rovó L, Kiss JG

Retrocochlearis léziók diagnosztikájának buktatói

Fül-Orr-Gégegyógyászat 63:(3) p. 149. (2017)

III. **Matievics V**, Bella Zs, Kiss JG, Rovó L

A halláscsökkenés vinpocetin terápiája

Fül-Orr-Gégegyógyászat 62:(3) pp. 122-124. (2016)

IV. Tóth F, Dimák B, Jarabin J, **Matievics V**, Nagy A, Perényi Á, Jóri J, Rovó L, Kiss J

Cortical evoked responses in patients with bilateral Cochlear Implants

Fül-Orr-Gégegyógyászat 62: (Suppl. A) p. A39. (2016)

V. Bach Á, Rovó L, **Matievics V**, Erdélyi E, Sztanó B

Endoscopos arytenoid lipoadductio féloldali hangszalagbénulás esetén

Fül-Orr-Gégegyógyászat 62:(3) p. 84. (2016)

VI. Matievics V, Tóth F, Dimák B, Jarabin J, Perényi Á, Jóri J, Rovó L, Kiss JG

Objective estimation of the bone conduction hearing threshold

Fül-Orr-Gégegyógyászat 62:(Suppl A) p. A31. (2016)

VII. Kiss J, Tóth F, Dimák B, Jarabin J, Matievics V, Nagy A, Perényi Á, Jóri J, Rovó L

Comparison of BAHA Sound Processors With Cortical Evoked Responses

Fül-Orr-Gégegyógyászat 62: (Suppl A) p. A27. (2016)

VIII. Kiss JG, Tóth F, Beöthy-Fehér O, Jarabin J, Matievics V, Csorba G, Perényi Á, Jóri J, Rovó L

Baha beszédprocesszorok teljesítményének összehasonlító vizsgálata

Fül-Orr-Gégegyógyászat 61:(3) p. 114. 1 p. (2015)

IX. Tóth F, Szamosközi A, Csorba G, Perényi Á, Jarabin J, Matievics V, Jóri J, Rovó L, Kiss JG

Beszédprocesszor programozása Nucleus Fitting Software-rel

Fül-Orr-Gégegyógyászat 61: (3) p. 117. 1 p. (2015)

ABBREVIATIONS

AE: Arytenoidectomy

EAAL: Endoscopic arytenoid abduction lateropexy

BVCP: Bilateral vocal cord palsy

BVCI: Bilateral vocal cord immobility

DR: Dynamic range

DSI: Dysphonia Severity Index

ETGI: Endolaryngeal Thread Guide Instrument

FDI: Friedrich's Dysphonia Index

FR: Frequency range in Semitones

F_0: Fundamental frequency (Pitch)

GRB: Global, roughness, breathiness scale

HNR: Harmonics to noise ratio

Jitt%: Jitter %

LMG: Laryngomyography

MPT: Maximum phonation time

MVI: Maximum voice intensity

PIF: Peak Ispiratory Flow

QoL: Quality of Life questionnaire

RLN: Recurrent laryngeal nerve

Shim%: Shimmer %

SLN: Superior laryngeal nerve

TC: Transverse Cordotomy

UVCP: Unilateral vocal cord palsy

VCI: Vocal cord immobility

VHI: Voice Handicap Index

Contents

1. INTRODUCTION

1.1. Vocal cord palsy

Vocal cord palsy occurs secondarily to laryngeal nerve injury, neuropathy, central neurological disorders or it can occur idiopathically. Moderate to severe dyspnea generally requires surgical intervention depending on the functional status, cardiopulmonary reserve, physical load and the general status of the patient. In the past decades several open and endoscopic surgical techniques have been introduced for treatment. Our team has been working on the treatment of vocal cord palsy for more than 20 years.

The aetiology of vocal cord palsy can vary: it can have an iatrogenic cause after thyroid or other neck surgery, mediastinoscopy, spinal surgery of anterior approach, malignant disease such as a thyroid carcinoma or a bronchial carcinoma, neurotropic viral diseases, neurological disorders (multiple sclerosis, apoplexy, polyneuropathy). The most frequent cause is iatrogenic (1). Even today, despite the use of sophisticated operative techniques, recurrent laryngeal nerve (RLN) injury most frequently develops as a complication of thyroid surgery (2). Vocal cord palsy often occurs during reoperations and operations of malignant tumours (3). Risk factors may be malignancy, the type of the operation, reoperations, substernal location, and an anatomical variant of nerve location, or previous irradiation of the neck. Occurrence of laryngeal nerve injury after thyroid surgery highly depends on the surgeons being experienced. The frequency of temporary vocal cord palsy is 0-15%; the occurrence of permanent palsy is 0-4%. (4, 5).

1.2. Patients suffering from unilateral vocal cord palsy (UVCP) with dyspnea

However, in UVCP, the leading symptom is usually voice weakness, which stems from the inappropriate vocal cord closure and difference in the stiffness of the paralyzed and non-paralyzed vocal cord (6, 7, 8).

The therapeutic strategies range from various voice therapies to phonosurgical techniques, which include endolaryngeal injections of different materials, laryngeal framework surgery, arytenoid adduction and laryngeal reinnervation. Laryngeal pacing, which has recently been introduced experimentally for the therapy of bilateral vocal cord palsy, might be an option also for UVCP in the future (9). The aim of these surgical techniques is to achieve a passive or active medialization of the paralyzed vocal cord to improve phonation (10). The predominance of voice symptoms in case of unilateral vocal cord palsy (UVCP)

does not exclude the existence of respiratory problems in these subjects. Dyspnea caused by UVCP is generally not highlighted in the literature although it is a real challenge for a surgeon. The degree of dyspnea depends largely on the position of the paralyzed vocal cord, the cardiopulmonary reserve, and the patient's efforts. The larynx can be considered the ''bottleneck of the airway''. Even a mild obstruction such as single-sided midline position of the vocal cord in UVCP can cause breathing difficulties, especially on exertion. This would likely restrict the patient's active lifestyle (11). In these cases, attempts to improve the voice quality with well-known vocal cord medialization techniques would probably worsen the respiratory symptoms. On the other hand, the classic glottis enlarging surgical procedures are limited only to very severe dyspnea as most such surgical options are considered both destructive and irreversible interventions which further worsen the voice quality (10, 12, 13).

UVCP patients with dyspnea might also benefit from endoscopic arytenoid abduction lateropexy (EAAL) because the range of mobility on the normal side might be sufficient to compensate for the lateralized position of the operated paralyzed side.

1.3. Patients suffering from bilateral vocal cord palsy (BVCP) with partial or total vocal cord movement recovery

In cases of bilateral vocal cord palsy this condition necessitates tracheostomy which has somatic and psychological side effects, and decrease in the patients' quality of life. Tracheostomy can have complications as well and can result in irreversible changes in the laryngeal structure. In many cases recurrent nerve lesion is not transient. Temporary vocal cord palsy is probably due to neuropraxic injury, resulting from intraoperative stretching, compression or ischemia of the recurrent laryngeal nerve (14). The regeneration of the laryngeal nerves may require weeks or months and it is difficult to predict the outcome. Therefore the treatment applied must be reversible: it is very important to preserve the laryngeal structure, and to prevent any permanent alterations. The phoniatric outcome highly depends on the preserved structure of the larynx.

1.4. Surgical intervention

Endoscopic arytenoid abduction lateropexy (EAAL) is a minimally invasive intervention, which is an effective dynamic solution for vocal cord palsy. EAAL as a primary treatment might serve as a minimally invasive, effective, dynamic solution for most cases of BVCP. The endolaryngeal thread guide instrument (ETGI) is a special tool which is able to facilitate this procedure. The EAAL immediately ensures a stable, properly wide glottis by a simple and fast endoscopic insertion of a double loop around the arytenoid cartilage by the ETGI, approximating it to its abducted position. The easily detectable laryngeal function recovery and good long-term results might simplify the management of vocal cord palsy patients (15, 16).

I have been working in the Department of Otorhinology, Head and Neck Surgery, University of Szeged since 2011. I joined the Audiology Department and since then I have participated in phoniatric research under the supervision of Professor László Rovó. I have taken part in the evaluation of phoniatric outcomes before and after different types of airway stenosis operations. Our team has worked out an evaluation panel for important phoniatric aspects of these surgeries. One of my main tasks has been to perform the pre- and postoperative examinations, to examine the voice quality improvement following these surgeries, which is very important in documentation of our newly designed or modified surgical methods of this topic.

2. AIMS OF THE THESIS

The aim of our thesis is to determine the phoniatric and respiratory outcome after EAAL in two patient groups:

1. Patients suffering from unilateral vocal cord palsy (UVCP) with dyspnea.
2. Patients suffering from bilateral vocal cord palsy (BVCP) with partial or total vocal cord movement recovery

Subjective and objective phoniatric and respiratory tests make the evaluation of the functional results of this glottis enlarging procedure possible.

I. Phoniatric tests

1. Objective tests:

-Mean Phonation Time (MPT)

- Fundamental frequency (F_0)

- Jitter (%)

- Shimmer (%)

- Harmonics to Noise Ratio (HNR)

2. Subjective tests:

-Perceptual voice analysis

-Subjective self evaluation (Voice Handicap Index)

3. Complex measurements

- Dysphonia Severity Index (DSI)

- Friedrich's dysphonia index (FDI)

II. Respiratory tests

1. Objective test: Peak Inspiratory Flow (PIF (l/s))
2. Subjective test: Quality of Life questionnaire

3. METHODS AND SUBJECTS

3.1. Surgical procedure

Endoscopic arytenoid abduction lateralization (EAAL) involves the endoscopic creation of suture loop(s) around the arytenoid cartilage in order to reposition the vocal cord relative to the thyroid lamina and cricoid. This repositions it into a physiological, abducted position (15, 16). The endolaryngeal thread guide instrument (ETGI; Mega Kft, Szeged, Hungary) was designed for safe, fast, and accurate suture loop creation (Figs. 1, 2).

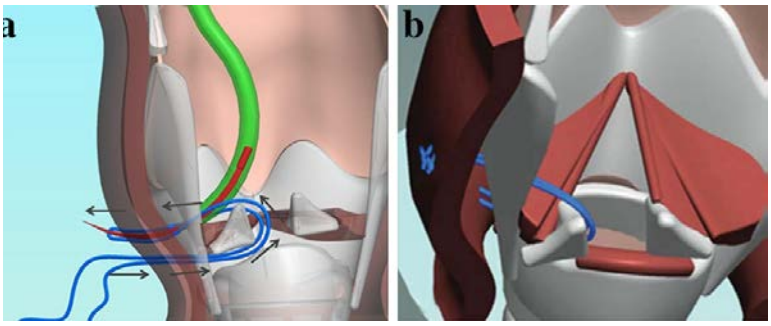

Fig.1 Schematic drawing of endoscopic arytenoid abduction lateralization (EAAL) procedure. Left arytenoid is lateralized by sutures.
a: The built-in, curved blade is pushed through under and above the vocal process with a doubled-over thread.
b: The procedure enables the endoscopic creation of two fixating loops, providing maximal physiological abduction of the arytenoid cartilage



Fig. 2 Endolaryngeal thread guide instrument (ETGI) (a) and different size blades and needles designed for infants, females and males (b)

All of the operations were performed under general anesthesia via total intravenous anesthesia and supraglottic jet ventilation as described in our earlier publications (12, 15, 17). EAAL as a primary treatment might serve as a minimally invasive, effective, dynamic solution for most cases of bilateral vocal cord immobility (BVCI) (15).

The treatment goal in UVCP with airway obstruction was to enlarge the airway without resorting to maximal abduction, which would diminish the voice unnecessarily. Compared to the BVCP surgeries in prior papers this is a significant difference. To accomplish this in UVCP surgeries, the lateralizing suture was placed more posteriorly around the body of the arytenoid cartilage instead of placing one limb of the loop around the vocal process (12, 14, 15, 18, 19, 20). This is to force the arytenoid cartilage into a more posterior location than in normal abduction, which elongates the vocal fold and results in increased tension on the vocal cord. Furthermore, this variation from the original technique diminished the outward rotation of the arytenoid keeping the cord straighter relative to the plane of the membranous cord. The degree of lateralization was adjusted by the surgeon looking into the microscope and tying the knot with endoscopic guidance under optimal tension.

3.2. Patients

3.2.1. Patients suffering from unilateral vocal cord palsy (UVCP) with dyspnea

Between January 2013 and December 2015, ten patients (seven females and three males, mean age 56.6 years, range 38–65 years) were treated in our department because of UVCP caused by thyroid or parathyroid surgery with a significant degree of respiratory problems attributable to their vocal cord pathology. There was no significant cardiorespiratory insufficiency besides UVCP in this patient group. The respiratory impact of the UVCP in this group is as follows: in five women and one man the glottic opening was sufficient for effortless breathing. In these patients respiratory insufficiency was due to their very active lifestyle (e.g., hunting or sport activity). All the patients complained of dyspnea and dysphonia, two described this part of their complaints as mild, but all of them described their dyspnea as a more serious problem than their voice weakness. After receiving accurate information about the possibility of worsening voice quality, all of the patients chose EAAL instead of tracheostomy or the “watch and wait” policy. The study was approved by the

Institutional Review Board of the University of Szeged. They underwent EAAL for a minimum of 6 months after the onset of the palsy (Fig. 3).

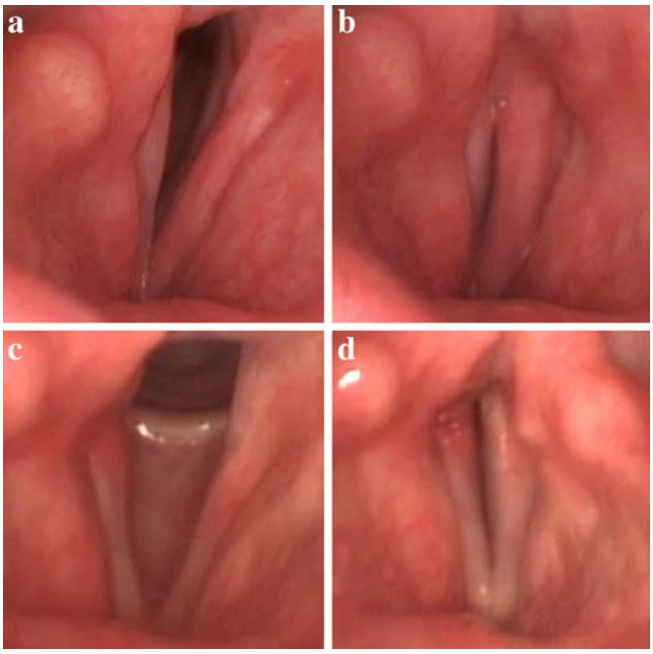

Fig.3 Endoscopic pictures of a 52-year-old male patient with UVCP on the right cord after thyroidectomy. Breathing problems presented only on effort: a, inspiration, b, phonation; 1st postoperative year after right sided EAAL: c, inspiration, d, phonation. After the surgery the lateralized vocal cord is straighter and tense, the airway and the phonatory closure are improved. UVCP unilateral vocal cord palsy, EAAL endoscopic arytenoid abduction lateropexy

3.2.2. Patients suffering from bilateral vocal cord palsy (BVCP) with partial or total vocal cord movement recovery

Between January 2013 and December 2015, eight patients (seven females and one male, mean age 55.2 years, range 25–68 years) were enrolled in this phoniatric study. All these patients suffered from temporal bilateral vocal cord palsy (BVCP) caused by thyroid or parathyroid surgery with a significant degree of respiratory problems attributable to their vocal cord palsy. After a careful review of their options (e.g. no treatment, other glottis enlarging procedure, etc.), they preferred the reversible EAAL surgery to improve their breathing. The study was approved by our Institutional Ethics Committee.

Their moderate to severe dyspnea was treated by endoscopic arytenoid abduction lateropexy (EAAL). Six patients had undergone thyroid surgery 2 days to 6 months before their admission to our clinic, whereas two patients had had it more than 6 months (6 months to 3 years) before admission.

Endoscopy was performed after surgical intervention in every month. Lateralization thread was removed after partial or total vocal cord movement recovery was detected at least on one side. The recovery was detected on average in the seventh month in this patient group (Figs.4, 5).

The time of phoniatric evaluation took place after the removal of the lateralization thread, after partial or complete recovery was detected. 2 patients with malignant thyroid disease were treated with additional radioiodine therapy, without external irradiation, thus the post treatment scarring of the laryngeal tissues was negligible, and therefore the study-group can be considered homogenous from this point of view.

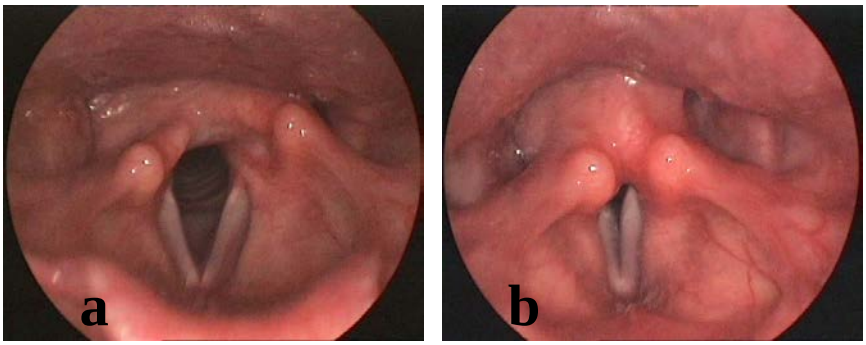

Fig. 4 Endoscopic pictures of a 25-year-old female with BVCP before removal of the lateralization thread on the left side: partial recovery was detected. a, inspiration, b, phonation

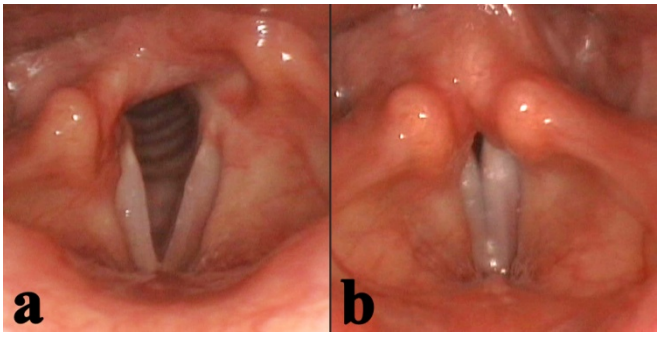

Fig. 5 Endoscopic pictures of a 25-year-old female with BVCP: 1 month after removal of the lateralization thread on the left side, after partial recovery was detected.

a inspiration: right vocal cord is in paramedian position, left vocal cord is in abducted position
b phonation: right vocal cord is in paramedian position, left vocal cord is in adducted position; vocal cord closure is normal.

3.3. Evaluation of the voice quality

3.3.1. Voice Assessment

Voice assessment was performed according to the guideline(s) elaborated by the Committee on Phoniatrics of the European Laryngological Society (21). In order to reach good compliance of the patients who had experienced iatrogenic disorders, the study was designed to be simple and convenient and focused on the data which describe well the vocal cord resonance conditions influenced by the surgical methods and the stage of the palsy.

3.3.1.1. Speech recording

Voice samples were recorded with a high sensitivity (40Hz-16 kHz) condenser head microphone (type: Audio-Technica ATM 73 ac) and digitalized with and stored in a personal computer. The patients were in straight sitting position; the head microphone was at an angle of 45 degrees. The distance between the mouth and the microphone was 5 cm (Fig. 6). The acoustic data were obtained by having three samples of sustained /a:/ voices at (spontaneous) comfortable pitch/loudness, and standardized connected speech in a soundproof room. These voice samples were recorded digitally and transformed to a file with a wav extension. The recording was repeated three times, with a sampling frequency of 96 kHz, 24 bit (Tascam US 122MkII external soundcard).

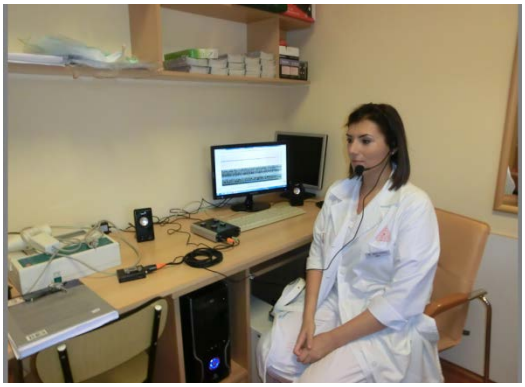

Fig. 6 Normal position of the patients and the microphone during voice analysis

3.3.1.2. Acoustic and Aerodynamic Measurements

Sustained /a:/ voices were analyzed using the segment at 0.50 to 2.00 seconds for each sample. The average of each sample served as the basis for analysis, Jitter %, Shimmer %, Pitch, and from the Voice range measurements (VRM) : (Dynamic Range (DR)=Maximum Intensity - Minimum Intensity, Frequency Range (FR)=Highest Frequency - Lowest Frequency), harmonics to noise ratio (HNR) and Maximum phonation times (MPT) were assessed by using Praat 5.3.37 software www.praat.org (Figs. 7, 8).

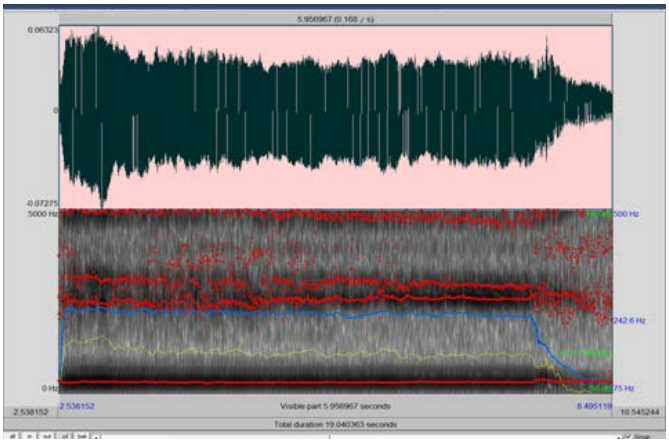

Fig. 7 Graphic visualization of a voice sample. In the lower part of the picture we can see the traditional spectrogram (gray scale) the pitch (blue) formants (red).

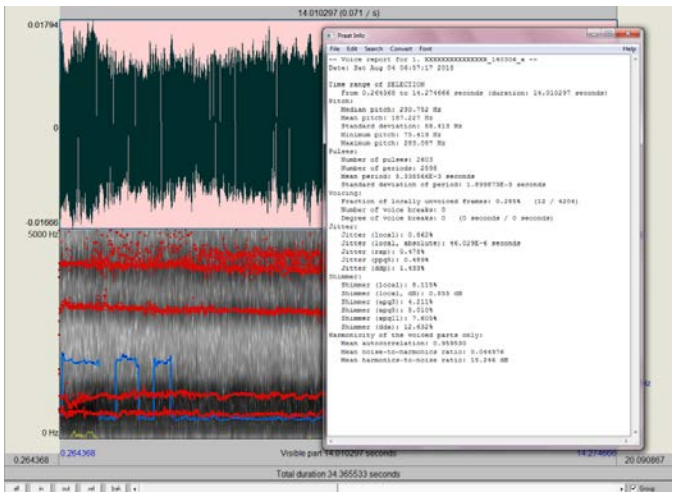

Fig. 8 The numeric values of the examined voice sample (Pitch, Jitter, Shimmer, Harmonics to noise ratio etc.).

3.3.1.3. Perceptual Voice Analysis

Connected speech recordings were perceptually analyzed by a jury of three physicians and one trained speech therapist who had been working with patients suffering from recurrent nerve palsy for several years. Voice recordings were assessed according to the G (global) R (roughness) B (breathiness) criteria (GRB) scale (7, 21). For each criterion and each sample, the jury allocated a score ranging from 0 (normal) to 3 (severe). The samples were presented in a random order and blinded with respect to the patient's identity. After listening, the jury members compared their scores and in case of disagreement re-listened until they reached a consensus.

3.3.1.4. Subjective self evaluation

To assess the patients' voice related to their quality of life, the Hungarian version of the Voice Handicap Index (VHI) (22, 23) was applied. The questionnaire contains 30 items in 3 subscales (functional, emotional, and physical [10 items in 3 subscales], designed to quantify patients' self-assessment of everyday voice handicap. Answers are given in a 5-point scale ranging from 0 (never) to 4 (always). The overall VHI score (raw score) can be used to grade subjective handicap from 0 (no handicap [raw score, 0—14]) to 3 (severe handicap [raw score 51-120])

3.3.1.5. Complex, calculated index for evaluation of dysphonia

The following indexes measure the overall quality of the voicing.

3.3.1.5.1. Dysphonia severity index (DSI)

DSI (24) is designed to establish an objective and quantitative measurement of the perceived voice quality to assess the efficacy of therapy among dysphonic patients. DSI is based on the weighted combination of objective acoustic and aerodynamic parameters, based on objective measures. DSI= (0.13xMPT) + (0.0053xHighest Frequency) – (0.26xMinimum Intensity) – (1.18xJitter %) + 12.4 A normal voice equals +5 and a severely dysphonic voice scores –5. The more negative the DSI, the worse the voice quality is. DSI can reach values under –5 and over +5 as well.

3.3.1.5.2. Friedrich's dysphonia index

Friedrich introduced a dysphonia index to determine the phoniatric status of patients. Friedrich's Dysphonia Index (FDI) (25) uses the average of 5 subscales each ranges from 0 (normal) to 3 (severe handicap). These subscales are MPT, DR, FR, and limitation in communications (subjective scale). The highest the score, the worse the voice quality will be. (Table I.). The subscales are: roughness from GRB scale, maximum phonation time (MPT) was measured how long the patient could sustain the sound "a" after deep inspiration (normally 18-20 seconds). With the aid of Voice range profile measurement the following were measured: minimum and maximum values of habitual speaking pitch (while reading a standard text) voice frequency. Voice pitch range was measured by half tones/semitones (ST) and vocal intensity or dynamic range (DR) was measured in decibel. In the original Friedrich's evaluation Communicative impairment was determined by the patient. We used the VHI test to grade the degree of the person's voice for communication. VHI 0-14 means no limitations (score: 0), VHI 15-24 means slight limited communication only in the case of voice load (score: 1), VHI 25-50 means small degree of constant limitation (score: 2), VHI>50 means constant strong limitation in everyday communication (score: 3).

Values of subscales	Hoarseness G value from GRB scale	Frequency range In semitones	Dynamic Range Decibel	Max. Phon. Time sec	Impairment of communication VHI
0	G0	>24	>45	>15	<15
1	G1	24-18	45-35	15-11	15-24
2	G2	17-12	35-25	10-7	25-50
3	G3	<12	<25	<7	>50

Table I: The values of the different subscales in Friedrich's dysphonia index. The dysphonia index is the mathematical average of the 5 subscales, ranging from 0 (no deviance) - to 3 (severe deviance)

3.4. Respiratory assessment

3.4.1. Peak Inspiratory Flow (PIF)

According to Bernoulli's principle, the most dominant deviation of extrathoracal airway stenoses can be found in inspiratory parameters. The Peak Inspiratory Flow (PIF) is one of the characteristic features and commonly used inspiratory parameters which describe the efficacy of glottis enlarging procedures. PIF (Peak Inspiratory Flow) is the largest expiratory flow achieved during the FVC manoeuvre. The peak inspiratory flow (PIF) is a common test of inspiratory efficiency and can be used to quantify the effectiveness of glottis widening procedures (26, 27, 28, 29). Spirometric measurements were performed using a Thor Spirotube–PC spirometer (THOR Laboratories Kft., Székesfehérvár, Hungary).

3.4.2. Quality of Life Questionnaire

The Quality of Life questionnaire of the Lausanne team (assessing the functional outcomes of the surgery in terms of breathing, voice, swallowing, and overall satisfaction) was used in the self-evaluation of their respiratory function (30).

In 2005 Monnier's team published a simple Lausanne 'Quality of Life' Questionnaire assessing the functional outcomes of the surgery in terms of breathing, voice, swallowing, and overall satisfaction (30). The following items were rated by using the scales as indicated: dyspnea (grade 0 - absent to grade IV at rest); noisy breathing (grade 0 - absent to grade 3 - very noisy breathing even at rest); coughing (grade 0 - absent to grade II -frequent episodes); dysphonia (grade 0 - normal voice to grade III _aphonia); dysphagia (grade 0 -6 absent to grade III - nasogastric tube feeding); and global satisfaction (grade 1 totally satisfied to grade 4 – totally unsatisfied). In all parameters lower grades mean a better condition. 'QoL' Questionnaire was translated, adapted and introduced to our clinical protocol as well. Usually the pre- and postoperative statuses have been evaluated (29).

4. RESULTS

4.1. Patients suffering from unilateral vocal cord palsy (UVCP) with dyspnea

4.1.1. Voice results

Fundamental frequency slightly increased in all patients (Fig. 9a). The value of Jitter decreased in nine cases and increased in one case. The average Jitter value decreasing was 0.38 % (Fig.9b). Shimmer varied minimally, decreasing slightly in seven cases, and increasing in three patients. The average Shimmer rate of change was not significant; the increase rate was 0.26%. Therefore the average Shimmer worsened somewhat (Fig. 9c). The harmonics-to-noise ratio (HNR) increased in six cases and decreased in four cases. The average HNR improvement was 0.82 dB (Fig. 9d). Surprisingly, even the maximum phonation time (MPT) increased in eight cases; however, a mild impairment occurred in two patients. The average MPT improvement was 2.18 s (Fig. 9e), but this did not reach statistical significance.

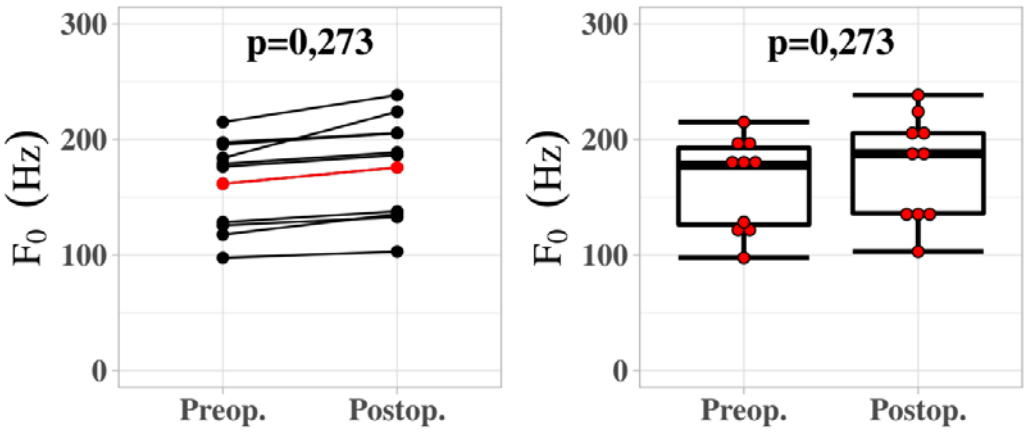

Fig.9a

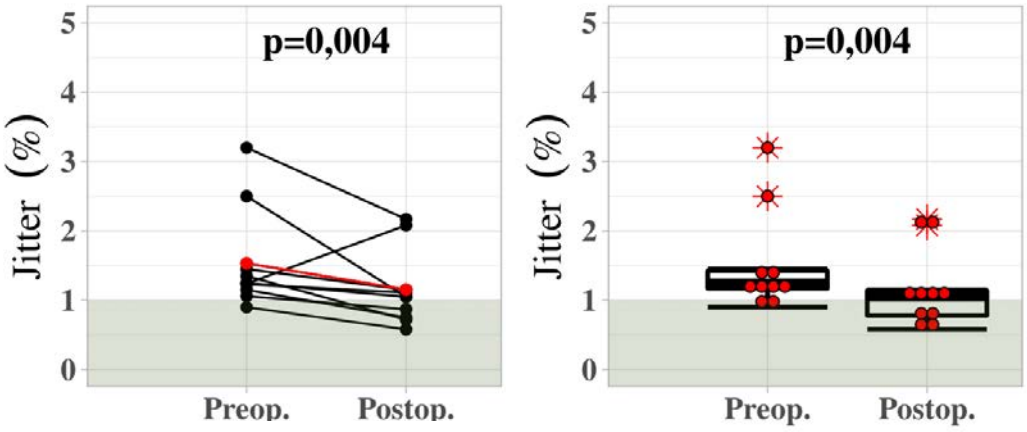

Fig.9b

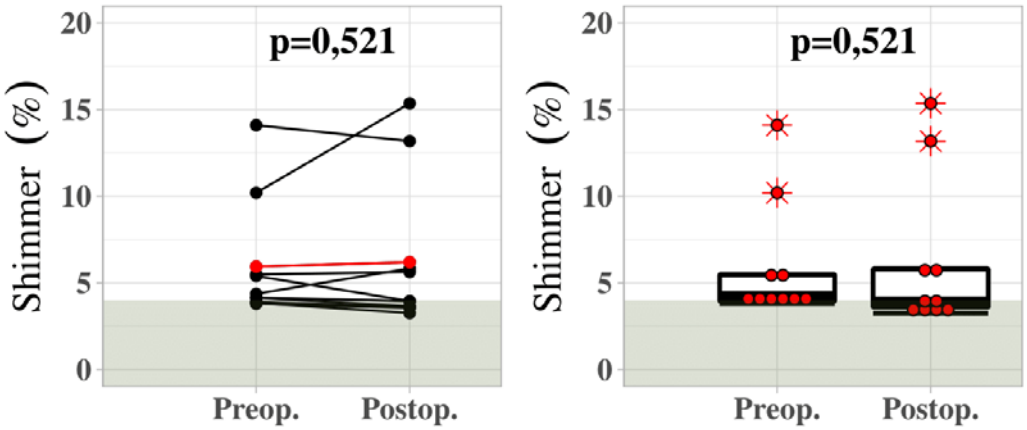

Fig.9c

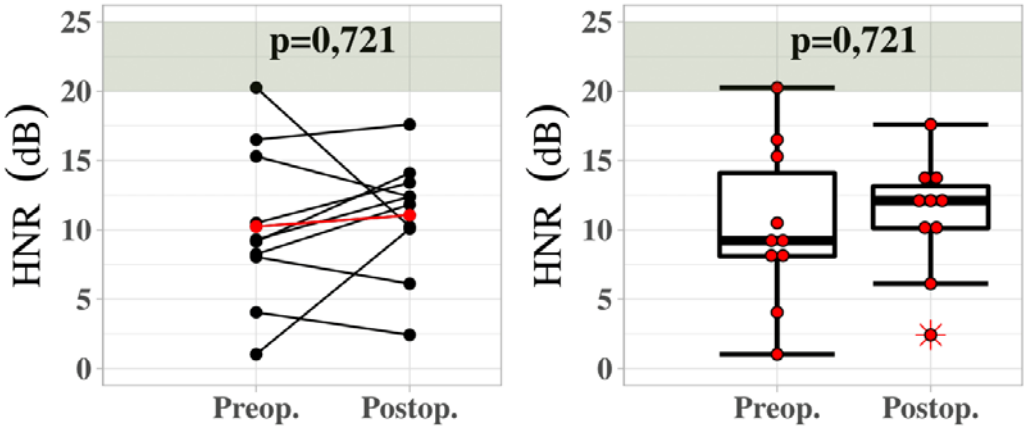

Fig.9d

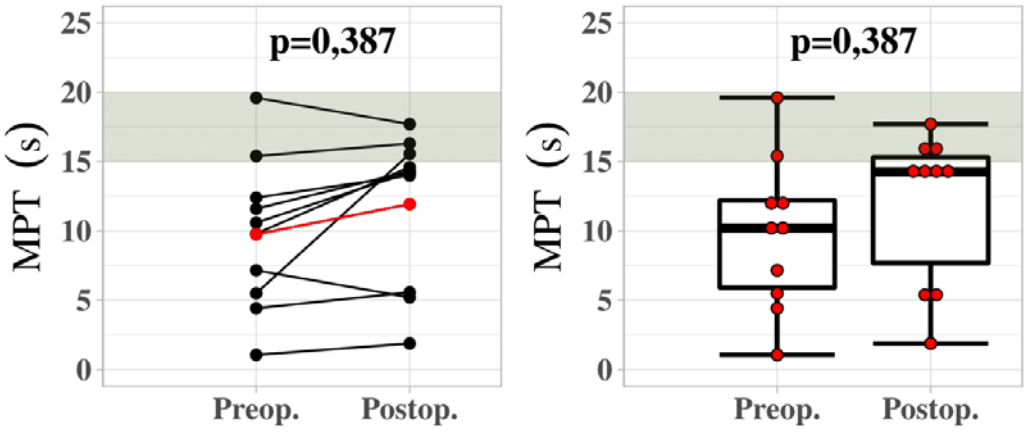

Fig.9e

Fig. 9 Objective voice results before and after endoscopic arytenoid abduction lateropexy in unilateral vocal fold palsy (UVCP) patients. Black lines represent the changing of the individual values; the red lines demonstrate the average of the values. The gray area represents the normal range of values;
a, Fundamental frequency (F0, non-significant change). b, Jitter (%) (significant improvement). c, Shimmer (%) (non-significant change). d, Harmonics-to-noise ratio (HNR, non-significant improvement). e, Maximum phonation time (MPT, non-significant change)

The perceptual voice analysis was performed according to the Global-Roughness-Breathiness (GRB) scale. The scores improved in all cases as well (Fig.10a), average improvement was 2.6. The Hungarian Voice Handicap Index (VHI) demonstrated that patients also considered their voices improved, average VHI score decrease was 16.8 (Fig.10b).

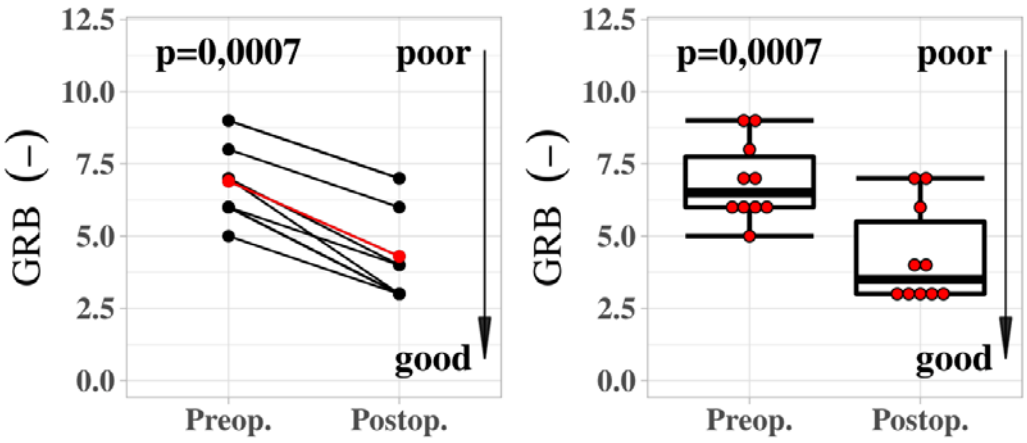

Fig. 10a

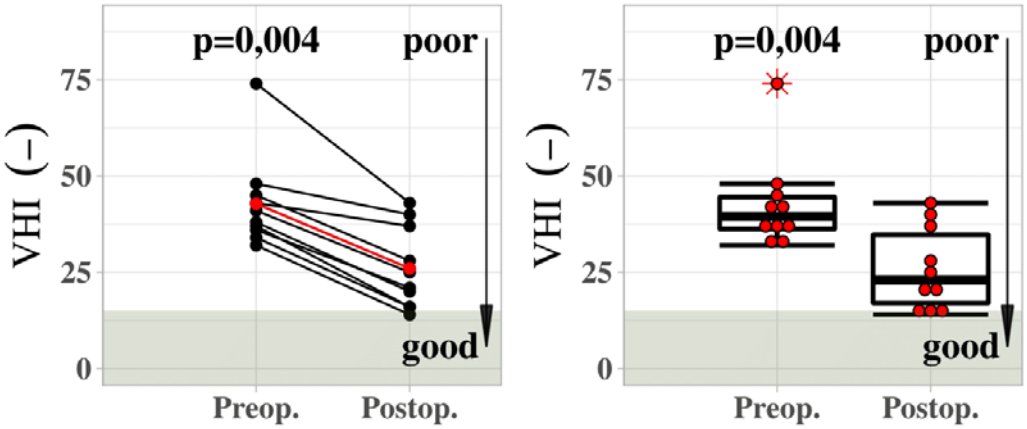

Fig.10 b

Fig. 10 a, perceptual voice analysis according to the Global-Roughness-Breathiness (GRB) scale (significant improvement) and b, Hungarian Voice Handicap Index (VHI) before and after endoscopic arytenoid abduction lateropexy in unilateral vocal fold palsy (UVCP) patients (significant improvement). The black lines represent the changing of the individual values; the red lines demonstrate the average of the values. The gray area represents the normal range of values

The complex voice analyzing panels also demonstrated the improvement of the voice in general. The overall objective voice result, Dysphonia Severity Index (DSI), and Friedrich's dysphonia index improved in all of the patients compared to the preoperative one. The average DSI improvement was 0.64 (Fig.11a), the average FDI improvement was 1.02 (Fig.11b).

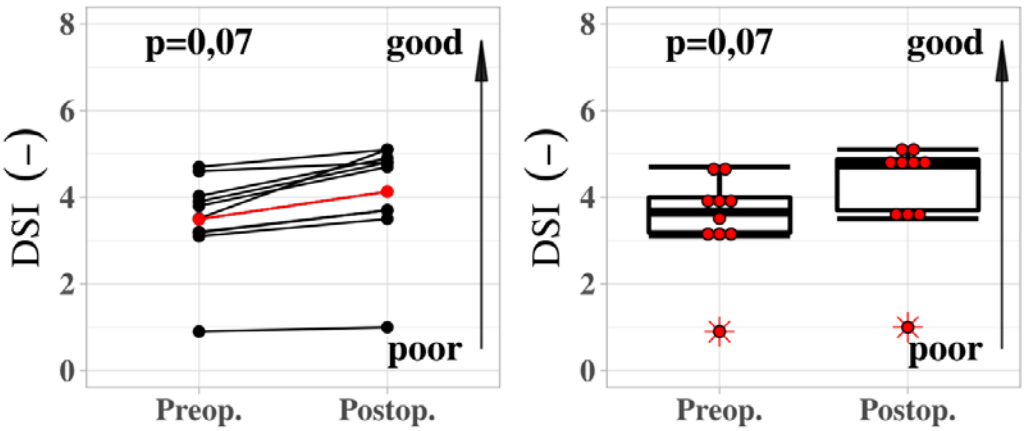

Fig.11a

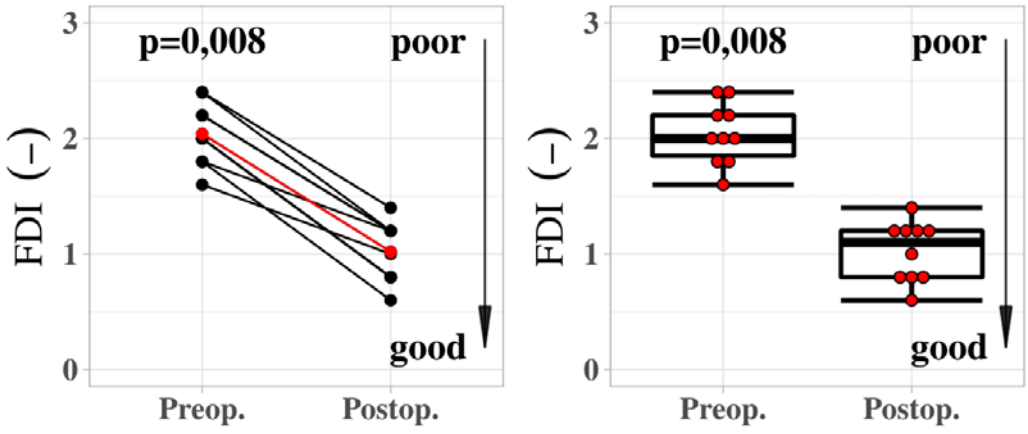

Fig.11b

Fig.11 Results of the complex voice analysis panel before and after endoscopic arytenoid abduction lateropexy in UVCP patients. The black lines represent the changing of the individual values; the red lines demonstrate the average of the values. a, Dysphonia Severity Index (DSI, non-significant improvement), b, Friedrich's dysphonia index(significant improvement)

4.1.2. Respiratory results

All patients showed an objective and stable airway improvement at 12-month follow-up. The average PIF increased significantly from 1.83 to 3.57 l/s (change 1.74 l/ s, 195.1% of baseline) (Fig.12a). The significant improvement of QoL scores by 32.2% also showed the patients' satisfaction with their respiratory function. The average score improved from 11.5 to 7.8 (decrease of 3.7) (Fig.12b).

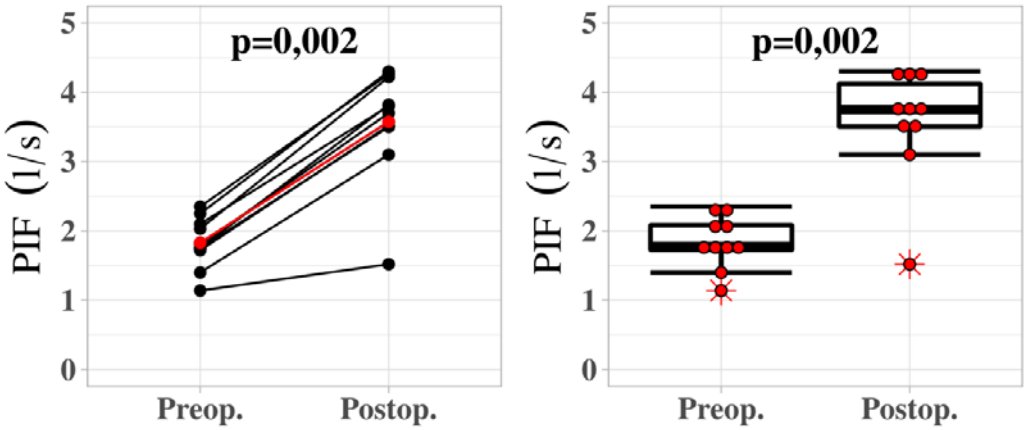

Fig.12a

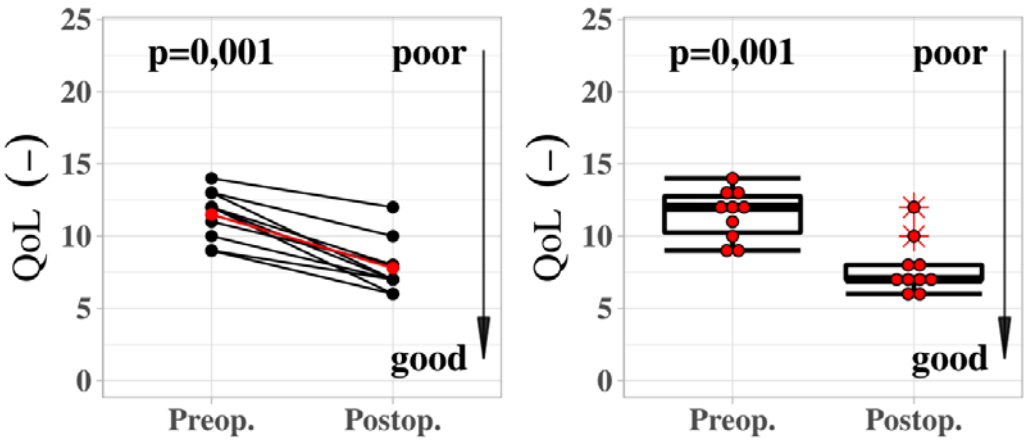

Fig.12b

Fig. 12 Objective and subjective respiratory results before and after endoscopic arytenoid abduction lateropexy in unilateral vocal fold palsy (UVCP) patients. The black lines represent the changing of the individual values; the red lines demonstrate the average of the values. The gray area represents the normal range of values

a, Peak inspiratory flow (PIF, significant improvement). b, Quality of Life' Questionnaire (QoL, significant improvement).

4.1.3. Complications

Mild, self-limited aspiration was noted in three of the ten patients. It spontaneously ceased within the first postoperative week. No other complication occurred in the follow-up period.

4.2. Patients suffering from bilateral vocal cord palsy (BVCP) with partial or total vocal cord movement recovery

Preoperative measurements were performed only in four patients (I. group) but in case of the other four patients preoperative assessment was not possible due to their bad overall condition. Postoperatively objective and subjective voice analysis and respiratory assessment were performed in all of the eight patients in the early period (third month) and after the fixating suture's removal (tenth month).

4.2.1. Voice results

The aerodynamic and acoustic parameters achieved or exceeded the normal low limits and they correlated well both with the perceptual grading and the self evaluation. Preoperative objective and subjective voice analysis could be performed in 4 patients; postoperative objective and subjective voice analysis was performed in all the eight patients in the early (third month) and late postoperative (tenth month) period. Fundamental frequency was in the normal range in all patients in the late postoperative measurements (Fig.13a). The value of Jitter decreased in six cases during the observed period and increased in two cases, but they were in the normal range (Fig 13b). In the first group the average Jitter value was 5.73% preoperatively, 3.71 % in the 3rd month and 0.80 % in the 10 th month, after suture removal; thus the average value was in the normal range. In Group II the average Jitter was 2.23 in the early postoperative period and 0.66 in the late postoperative measurements. In group I. the average value of Shimmer was 18.94 % preoperatively 7.14 % in the 3rd month and 4.06 % in the late postoperative period, after suture removal. In Group II the average Shimmer was 9.4 in the early postoperative period and 5.7 in the late postoperative measurements, thus an improvement could be observed (Fig.13c). The harmonics-to-noise ratio (HNR) increased in all the eight cases. In group I. the average HNR value was 2.12 preoperatively, 9.47 dB in the 3rd month and 16.56 dB in the late postoperative period, after suture removal. The average HNR value in the first group was almost in the normal range after suture removal. In Group II the average HNR was 8.55 dB in the early postoperative period and 15.12 dB in the late postoperative measurements, thus a significant improvement was observed during the observed period and the average value approached the normal range (Fig.13d). The maximum phonation time (MPT) increased in seven cases; however, mild impairment occurred in one patient. In Group I the average MPT improvement was 5 s, from 3.30 s to 8.30 s (251,5% of baseline) according to the measurements of late postoperative period. In Group II. the average MPT was 5.05 s in the late postoperative period, after suture removal (Fig.13e).

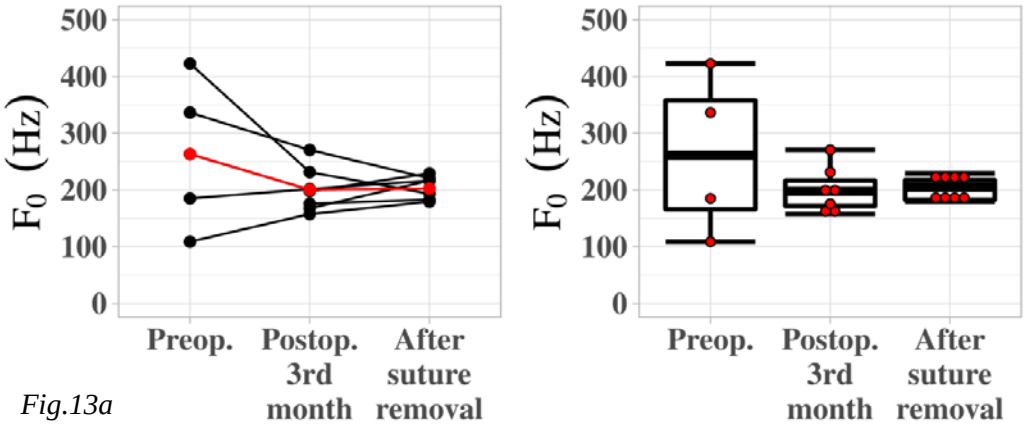

Fig.13a

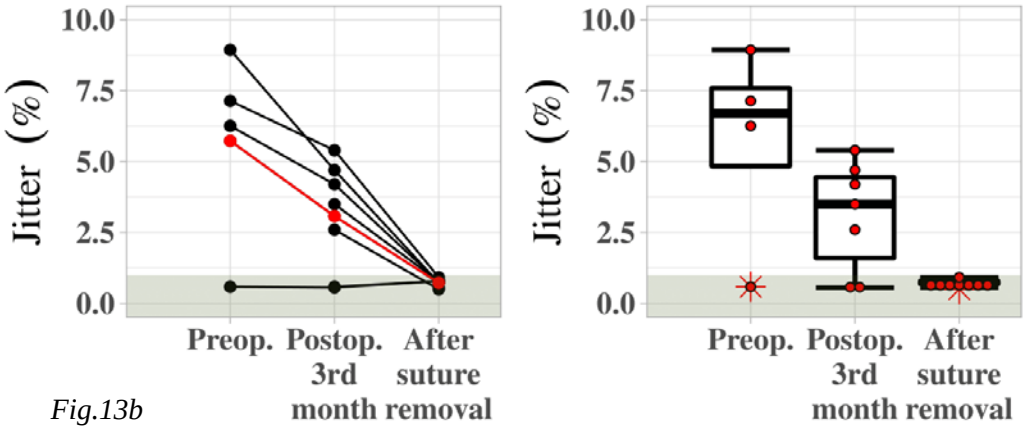

Fig.13b

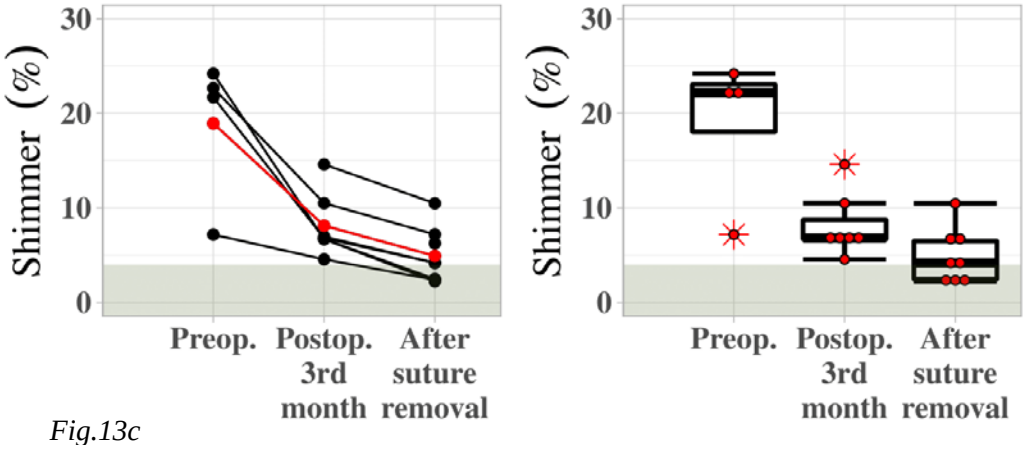

Fig.13c

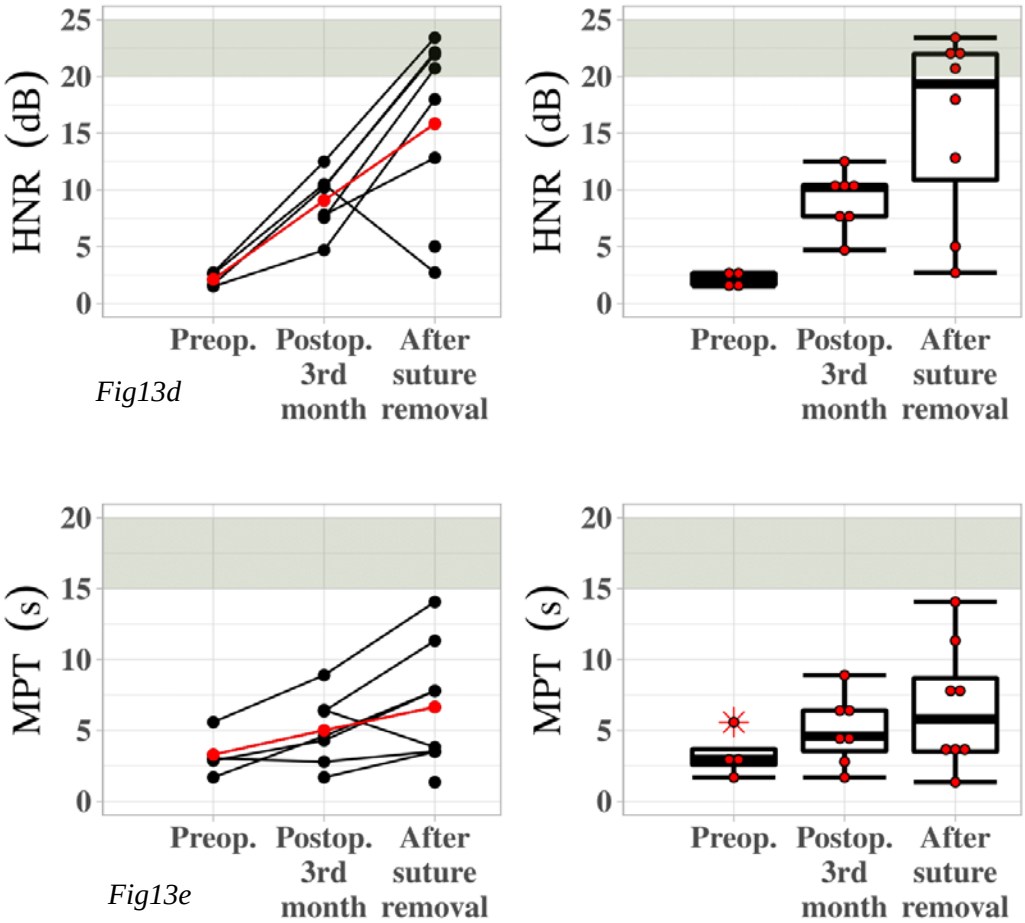

Fig 13 Objective voice results before endoscopic arytenoid abduction lateropexy, in the early period (third month) and after the fixating suture's removal (tenth month) in bilateral vocal fold palsy (BVCP) patients. Black lines represent the changing of the individual values; the red lines demonstrate the average of the values. a, Fundamental frequency (F0,). b, Jitter (%). c, Shimmer (%). d, Harmonics-to-noise ratio (HNR). e, Maximum phonation time (MPT)

Perceptual voice analysis according to the Global-Roughness-Breathiness (GRB) scale was performed. The scores improved in all cases as well. The average GRB score was 1.25 in Group I. and 2.25 in Group II after suture removal (Fig. 14a). The Hungarian Voice Handicap Index (VHI) demonstrated that patients also considered their voices improved. The average VHI score was 11.75 in Group I. and 15 in Group II after suture removal (Fig. 14b).

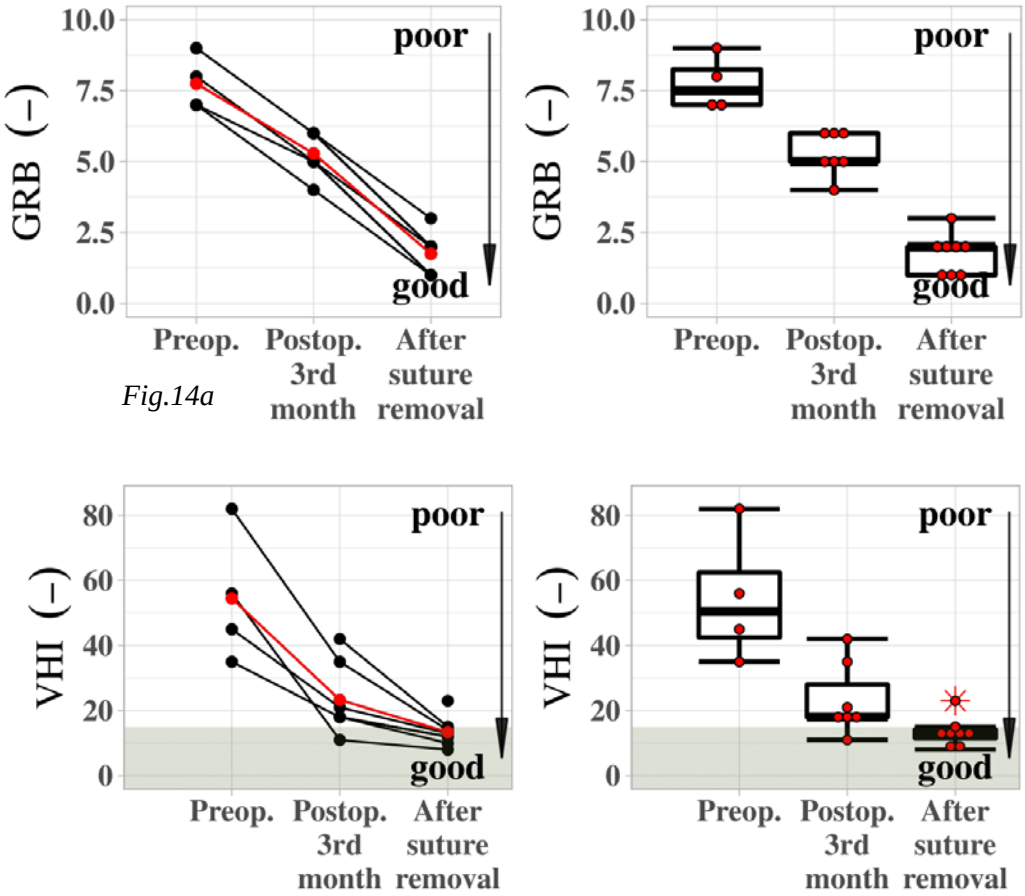

Fig.14a

Fig.14b

Fig.14 GRB, VHI Results of the subjective scale analysis before endoscopic arytenoid abduction lateropexy in bilateral vocal fold palsy (BVCP) patients, in the early period (third month) and after the fixating suture's removal (tenth month). The black lines represent the changes of the individual values; the red lines demonstrate the average of the values. The gray area represents the normal range of a Quality of Life score a ''Global-Roughness-Breathiness'' score (GRB). b Voice Handicap Index score (VHI)

The complex voice analyzing panels also demonstrated the improvement of the patients'voice quality in general. The overall objective voice result, Dysphonia Severity Index (DSI), became better in all of the patients compared to the preoperative one. The average DSI improvement was 2. 9 in Group I, with the average value of 2.42 after suture removal. In Group II the average DSI value was 1.75 in the late postoperative measurement.

The Friedrich's Dysphonia Index (FDI) became better in all of the patients compared to the preoperative one. The average FDI improvement was 1.20 in Group I, with the average value

of 1.30 after suture removal. In Group II the average FDI value was 1.35 in the late postoperative measurement.

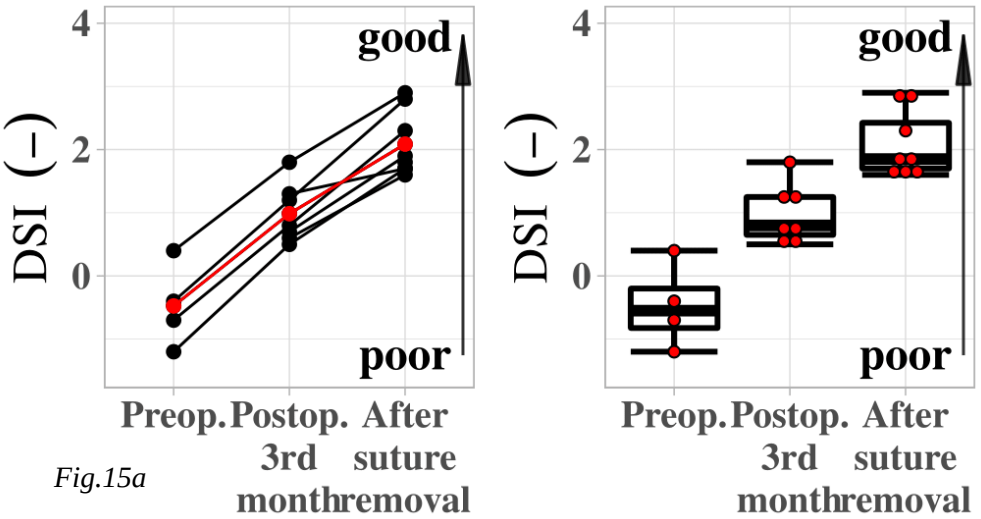

Fig.15a

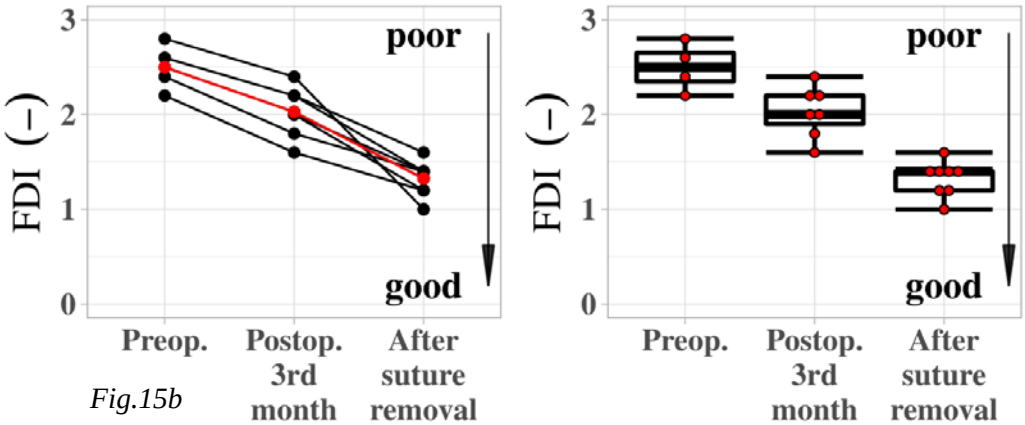

Fig.15b

Fig. 15 Results of the complex voice analysis before endoscopic arytenoid abduction lateropexy in bilateral vocal fold palsy (BVCP) patients, in the early period (third month) and after the fixating suture's removal (tenth month). The black lines represent the changes of the individual values; the red lines demonstrate the average of the values. a, Dysphonia Severity Index (DSI), b, Friedrich's Dysphonia Index (FDI)

4.2.2. Respiratory results

All patients showed an objective and stable airway improvement immediately after the glottis enlarging procedure. In case of group I the preoperative average PIF value was 1.045. The overall average PIF increased significantly from 1.045 to 2.207 l/s (change 1.162 l/ s, 111.1% of baseline) according to the measurements of the late postoperative period (Fig. 16a). The significant improvement of QoL scores also showed the patients' satisfaction with their respiratory function, the average score improved from 13 to 7.25 (decrease of 5.75) in group I. (Fig. 16a)

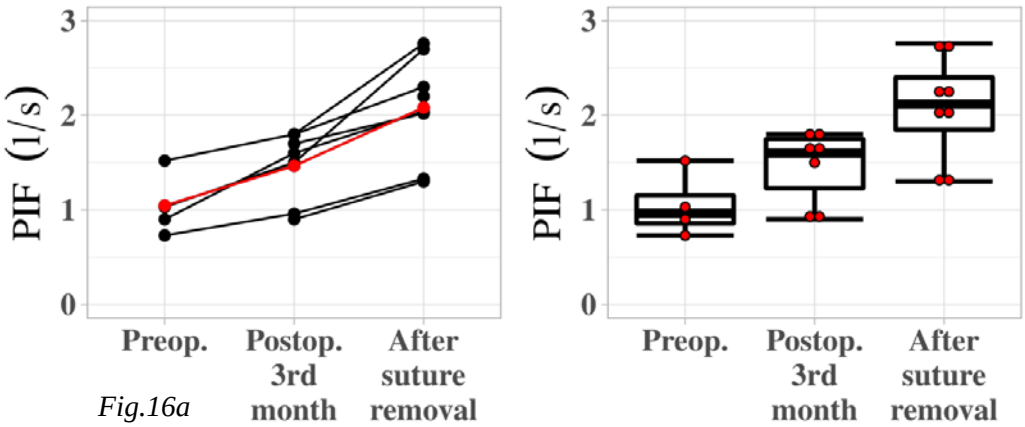

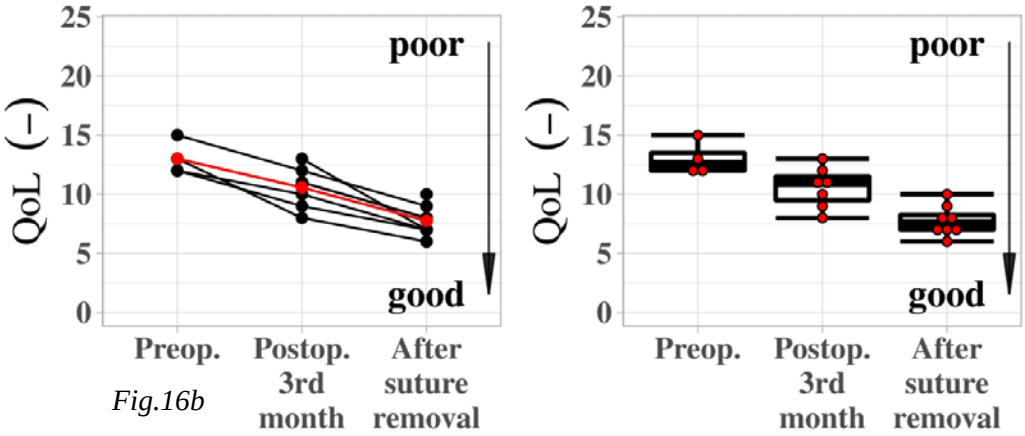

Fig.16 Objective and subjective respiratory results before and after endoscopic arytenoid abduction lateropexy in bilateral vocal fold palsy (BVCP) patients. The black lines represent the changes of the individual values; the red lines demonstrate the average of the values. a, Peak inspiratory flow (PIF). b, Quality of Life' Questionnaire.

In patients where preoperative measurements were not possible (group II.) the average late postoperative PIF value was 1.95 l/s and the postoperative average Qol score was 8.25 in the late postoperative period. These are acceptable results after a serious life threatening condition.

4.2.3. Complications

Mild, self-limited aspiration was noted in two of the eight patients. It spontaneously ceased within the first postoperative week. No other complication occurred in the follow-up period.

5. DISCUSSION

5.1. Patients suffering from unilateral vocal cord palsy (UVCP) with dyspnea

The evaluation of the functional outcome of the UVCP is a complex task because it is not only determined by the applied surgical technique but also by the patients' individual parameters (age, education, overall health condition etc.) and the grade of the regeneration process. Generally, hoarseness is the main complaint in patients experiencing unilateral vocal cord palsy (UVCP). This is effectively treated by the well-established medialization procedures. When UVCP includes airway limitations, the impact on the quality of life is much greater (13, 31). This can result from one or more factors that include: decreased or absent abductory support during inspiration (a flail cord), a medially tipped arytenoid body, synkinesis with adductory activity during inspiration, post- palsy contracture of the cricoarytenoid joint capsule, high flow rate need due to a small larynx, concomitant cardiac or pulmonary insufficiency and obesity (32). Since improving the voice and widening the airway are considered opposing processes, improving the voice may compromise the airway further and could warrant a tracheostomy. Conversely, improving the airway by standard techniques like cordotomy and traditional lateralization will commonly diminish the voice further. Theoretically, dynamic, selective reinnervation procedures which restore the mobility of the vocal cord might be the ideal solution to this problem (33). These irreversible interventions, establishing a selective anastomosis between the adductor and abductor branches of the recurrent laryngeal nerve and the appropriate branches of the phrenic nerve and hypoglossal nerve over a time period of 6 to 9 months, can be applied even in cases of unfortunate synkinetic reinnervation status (17). This rather invasive surgery requires an extensive

exposure of the neck, a properly trained surgeon and a relatively long recovery period; therefore these interventions are performed only in few centres nowadays. In the future a minimally invasive solution with immediate symptom relief in UVCP cases with respiratory problems might be the application of laryngeal pacing devices, which are primarily intended to treat BVCP (9). The use of the simpler, classic glottis enlarging procedures such as partial or total arytenoidectomy, transverse cordotomy, and submucosal cordectomy is to be considered carefully because they irreversibly impair phonation by the destruction of the voicing structures. Isshiki described the length, elasticity, and mass of the vocal cord as the outcome-determining factors during phonosurgery which can be justified by physical principles as well (8, 34). According to Isshiki, apart from the inappropriate closure, these unbalanced vocal cord parameters cause chaotic vibration patterns and hoarseness typical of UVCP. Endoscopic arytenoid abduction lateropexy (EAAL) is based on the lateralization of the arytenoid cartilage with the membranous vocal cord. The entire vocal unit is displaced in a physiological manner without resection of phonatory structures. In our recent publication performed on 100 cadaver larynxes we proved that after this procedure the vocal cords become straighter and tenser than after any other endoscopic glottis enlarging intervention (12). By the enlargement of the glottic area, the airflow velocity between the cords is slowed down to the same volume per second (according to the Bernoulli principles). This in turn reduces the medialization effect of the vacuum that rapid airflow velocity generates (the Venturi phenomenon) on the mass of the vocal cords during inspiration that causes stridor. It also provides a more favorable condition for phonation according to the postulates of Isshiki. Another vocally important factor is the postoperative angle of the vocal cords at the anterior commissure (35). EAAL produces a relatively small angle (12) compared to other interventions. This facilitates better phonation closure. The convex cricoid facet guides the concave arytenoid facet antero-posteriorly during the abduction. There is also some degree of physiological rotation during abduction (16, 36). In cases of UVCP, the goal of EAAL is not to produce maximal airway enlargement. This is because of the intact contralateral side. By placing the lateralizing suture more posteriorly than in case of BVCP, the arytenoid cartilage is moved more posteriorly but not as far laterally, as in full physiological abduction. This manoeuvre improves the tension and the straightness of the vocal cord and diminishes the rotational effect of the suture loops, thus the angle of the anterior commissure. These factors have been shown to improve phonatory closure as seen in these patients (Fig. 3d). The

endoscopic control proved a continuous improvement of the phonation closure which was completed generally after several weeks. This remained stable in the follow-up period as it is demonstrated by the improved voice parameters at the end of the first year. Our functional tests clearly demonstrate the advantages of this concept. The airway significantly improved early after intervention. In spite of this, the objective and the subjective preoperative voice parameters did not worsen; moreover, in many cases, significant improvement was recorded. This voice improvement, together with the more adequate airway, clearly explains the significantly improved quality of life. Aspiration is relatively common with other glottic widening techniques. The preserved arytenoid mucosa probably protects the laryngeal reflex arc, which is enabled by the intact superior laryngeal nerve along with intact adduction of the contralateral side. This seems to decrease the incidence and duration of this complication (15, 20, 37).

5.2. Patients suffering from bilateral vocal cord palsy (BVCP) with partial or total vocal cord movement recovery

The pathophysiology of vocal cord palsy is not completely understood despite the numerous meticulous animal and human studies (32, 38). Intraoperative stretching, thermal damage, etc. often cause only axono- or neuropraxy which explains the frequently reported laryngeal function regeneration (40-86%) (2, 39), nevertheless the exact definition of recovery is rarely cited in these papers. As the studies of this subject describe it, the regeneration mechanism is complex and variable, with most muscles generally regaining more or less innervation following an RLN injury. These “reinnervation” processes may be completed in several months after the onset of palsy and the final result of these regenerations generally range from the complete or almost complete recovery of the vocal cords to different types of synkinesises which determines the retained voice. Hence, Crumley suggested using the term “laryngeal vocal cord mobility impairment” instead of “vocal cord palsy” (38). This also points out that the phoniatric assessment of glottis enlarging procedures is a complex task. EAAL preserves the reversibility of the laryngeal structures to a large extent. Furthermore, damage and scarring to the membranous part of the vocal cord, which is involved in cord vibration and may compromise voice, can also be avoided in this way. During abduction, the lateral sliding motion of the vocal process is accompanied by an upward and occasionally slightly posterior movement, with the arytenoid cartilage turning laterally and upward on the

cricoid cartilage facet. This is the key to a really effective simple suture lateralization procedure, because it is obvious that the lower resistance against the fixating sutures arises if the joint is moved in its natural way. This position provided a more significant glottic enlargement (þ55%, P <.00002) than the regular double-loop vocal cord lateralization in our objective morphometric study (12). Additionally, this position allows loops to stay on the stable surface of cartilage and does not let them slip to and cut through the vocal cord. This more posterior loop creating, however, is a challenge for the earlier methods. Moreover, the ETGI ensures continuous suture guiding; there is no need for repeated external recharge of the instrument compared to Lichtenberger's device (15). Considering these facts, the accurate loop creation for EAL is safer and quicker by ETGI. Further advantages of this compact technique are the following: 1) it can be applied easily in case of difficulties of direct laryngoscopy (use of Macintosh laryngoscope); 2) the double loop creation with one maneuver, aside from the increased efficiency, diminishes the risk of vocal cord remedialization (e.g., a rupture of one of the sutures); and 3) the thread moves within the disinfected laryngeal cavity and the skin, therefore drug administration (to avoid the edema and perichondritis) can be diminished. The method utilizes the normal mechanism of abduction, thus the possible contraindications are limited. An airway infection might be a contraindication. The EAAL ensures a stable, properly wide glottis by a simple and fast endoscopic insertion of a double loop around the arytenoid cartilage by the ETGI, approximating it to its abducted position (15).

Dyspnea caused by the developed bilateral vocal cord palsy (BVCP) mainly depends on the position of the vocal cords and on the cardiopulmonary reserve. Life threatening conditions unequivocally require surgical intervention to prevent acute asphyxiation, however, even moderate dyspnea may restrict the patient's daily activities which necessitates restoring the airway patency too (10). Tracheotomy used to be the golden standard procedure for centuries, but it may have severe somatic and psychological side effects. Owing to the continuous development of anaesthesia and the improvement of diagnostic and surgical instruments in the last decades, avoiding this inconvenient procedure has become possible. Most types of surgical interventions include the resection of glottic structures (complete or partial vocal cord resection, and/or arytenoidectomy (37, 40) leading to significant voice

impairment (7, 10, 21). Therefore their indication is commonly considered when permanent palsy is confirmed by laryngomyography (41)

In our series complete vocal cord recovery was found in 4 cases and 4 of them were unilateral recoveries with good phonatory closure. However, when vocal cord functions were regained within a few months' time after the fixating suture's removal, the previously lateralized arytenoid generally moved a bit loosely compared to the other side. In such cases it must be considered that the EAAL was performed always on the side where the nerve damage was presumed more severe (15). The phoniatric parameters and the motion recovery on the lateralized side were slightly impaired, but these parameters were found similarly impaired even after uneventful strumectomies (42). In these cases the fine tuning mechanism probably did not regenerate perfectly well after the recurrent nerve injury. In the 4 patients with unilateral vocal cord recovery the previously lateralized vocal cords re-medialized after the removal of the suture and their phoniatric parameters correlated well with the result of the group with untreated unilateral vocal cord palsy (25). These data support the presumption that EAAL preserves the reversibility of the laryngeal structures to a large extent. Furthermore, damage and scarring to the membranous part of the vocal cord, which is involved in cord vibration and may compromise voice, can also be avoided in this way as demonstrated in the Figures.

The EAAL ensures a stable, properly wide glottis this way by a simple and fast endoscopic insertion of a double loop around the arytenoid cartilage by the ETGI (15), approximating it to its abducted position (16). In contrast, the postoperative, residual ability to phonate in permanent palsy is generally considered to be weak; inversely proportional to the adequacy of the airway achieved by the ordinary glottis widening procedures as arytenoidectomy, transverse cordotomy, and medial arytenoidectomy, which more or less aggravate the fine anatomical structures of the larynges (45,46).

In our experience (as it is demonstrated in the figures), even after the onset of the BVCP, voice suffers notable impairment thus the quality of voice cannot provide an appropriate basis for postoperative voice evaluation either. But comparing our data to the few studies presented in the international literature (47) about the phoniatric outcome in transverse cordotomy, which is considered to be one of the best voice preserving glottis enlarging

procedures, significant postoperative voice deterioration can be noticed compared to normal voicing (48). Moreover, these studies do not distinguish between the different regeneration levels, which were found in the present study. Comparing the average results of those studies to ours, EAAL provides a more favourable vocal outcome for all patients than transverse cordotomy.

6. CONCLUSIONS AND NEW RESULTS

6.1. Conclusion- Patients suffering from unilateral vocal cord palsy (UVCP) with dyspnea

In case of unilateral vocal cord palsy (UVCP) with hoarseness and breathing impairment, airway improvement can be achieved without a loss of voice quality by the modified endoscopic arytenoid abduction lateropexy (EAAL) procedure in the majority of cases. In a vibrating system 3 main factors determine vibration: weight, tension and flexibility. Therefore the same factors are also important in the functioning of the vocal cords. In our experience a lateralized, that is tense paralysed vocal cord can give a better phoniatric result than the loose paralysed vocal cord in medial position. Thus improving respiratory function is not necessarily associated with the deterioration of voice quality. This can mean a new approach to the surgical treatment of unilateral vocal cord palsy. The recent phoniatric results of EAAL justify that this procedure provides excellent outcomes in temporary UVCP, and a good or acceptable voice with a stable adequate airway can be achieved even in most cases of permanent palsy. To sum it up, this intervention may be a reliable alternative to UVCP patients suffering from effort dyspnea. Self- evaluation tests have shown the satisfaction of our patients, indicating a better quality of life due to the improved respiratory function and acceptable voice quality. This intervention is non-destructive, reversible, and minimally invasive.

6.2. Conclusion- Patients suffering from bilateral vocal cord palsy (BVCP) with partial or total vocal cord movement recovery

Bilateral vocal cord impairment is not a static condition, and its outcome appears within several months after the onset of RLN injury. The recent phoniatric results of EAAL justify that this procedure provides excellent outcomes in temporary BVCP. Objective and subjective phoniatric results have proved the reversibility of the procedure. This non-

destructive, reversible, and minimally invasive intervention may be a reliable alternative to the popular endoscopic glottis widening.

7. ACKNOWLEDGEMENTS

Without the help, support, and encouragement from several persons, I would never have been able to complete this work. First of all, I would like to express my gratitude and thanks to my program director Professor Dr. László Rovó for encouraging and supporting my work from the very beginning. I wish to express my gratitude to Dr. Balázs Sztanó, my supervisor. I would like to express my gratitude to Professor Jóri József, the former Head of Department of Oto-Rhino-Laryngology and to Dr. József Géza Kiss, the Head of Audiology Department. I would like to express my gratitude to Dr. Zsófia Bere for her valuable help in statistical analysis, to Dr. Ádám Bach, Dr. László Szakács, and Alice Szamosközi for their professional cooperation, Roland Nagy and Benedek Forrai for their technical help.

I am deeply indepted to my colleagues, the members of our upper airway stenosis workgroup, especially to Professor Dr. László Rovó, Dr. Balázs Sztanó and Ádám Bach for their cooperation. Thanks to my colleagues at the Department of Oto-Rhino-Laryngology, Head and Neck Surgery.

Last but not least, I wish to thank my family and friends for their constant support and encouragement.

8. REFERENCES

(1) Reiter R, Hoffmann TK, Rotter N, et al. Etiology, diagnosis, differential diagnosis and therapy of vocal fold paralysis. Laryngorhinootologie. 2014 Mar; 93(3):161-73.

(2) Rosenthal LH, Benninger MS, Deeb RH. Vocal fold immobility: a longitudinal analysis of etiology over 20 years. Laryngoscope. 2007 Oct; 117(10):1864-1870.

(3) Jori J, Rovo L, Czigner J. Vocal cord laterofixation as early treatment for acute bilateral abductor paralysis after thyroid surgery. Eur Arch Otorhinolaryngol. 1998;255(7):375-378

(4) J Gaëtan-Romain, V Guarnero, N Demartines, V Schweizer, M Matter Recurrent laryngeal nerve injury after thyroid and parathyroid surgery: Incidence and postoperative evolution assessment. Medicine (Baltimore) 2017 Apr; 96 (17)

(5) Hayward NJ, Grodski S, Yeung M, et al. Recurrent laryngeal nerve injury in thyroid surgery: a review. ANZ J Surg 2013; 83:15–21.

(6) Belafsky PC. Bilateral vocal fold immobility. Curr Opin Otolaryngol Head Neck Surg 2011 19:415

(7) Hirano M. Clinical examination of voice. 1981 Springer, Wien

(8) Isshiki N. Progress in laryngeal framework surgery. Acta Otolaryngol 2000 120:120–127

(9) Mueller AH, Hagen R, Foerster G, Grossmann W, Baumbusch K,Pototschnig C Laryngeal pacing via an implantable stimulator for the rehabilitation of subjects suffering from bilateral vocal fold paralysis: a prospective first-in-human study. Laryngoscope 2016 Dec 126:1810–1816

(10) Harnisch W, Brosch S, Schmidt M, Hagen R. Breathing and voice quality after surgical treatment for bilateral vocal cord paralysis. Arch Otolaryngol Head Neck Surg 2008 134:278–284

(11) Røksund OD, Maat RC, Heimdal JH, Olofsson J. Exercise induced dyspnea in the young. Larynx as the bottleneck of the airways. Respir Med 2009 103:1911–1918

(12) Szakács L, Sztanó B, Matievics V, Bere Z, Bach A, Castellanos PF, Rovó L A comparison between transoral glottiswidening techniques for bilateral vocal fold immobility. Laryngoscope 2015 125:2522–2529. doi:10.1002/lary.25401

(13) Siu J, Tam S, Fung K. A comparison of outcomes in interventions for unilateral vocal fold paralysis: a systematic review. Laryngoscope 2016 126:1616–1624

(14) Jóri J, Rovó L, Czigner J. Vocal cord laterofixation as early treatment for acute bilateral abductor paralysis after thyroid surgery. Eur Arch Otorhinolaryngol. 1998;255(7): 375-378.

(15) László Rovó , Shahram Madani , Balázs Sztanó, Valéria Majoros, György Smehák, László Szakács, József Jóri. A new thread guide instrument for endoscopic arytenoid lateropexy. Laryngoscope 2010 Oct;

(16) Wang RC. Three-dimensional analysis of cricoarytenoid joint motion. Laryngoscope. 1998 Apr;108(4 Pt 2 Suppl 86):1-17

(17) Sandhu GS, Nouraei SAR, Rovo´ L, Marie JP, Mueller AH, Castellanos PF. Bilateral impaired vocal cord mobility. In: Sandhu GS, Nouraei SAR (eds) Laryngeal and tracheobronchial stenosis. Plural Publishing, San Diego, 2016 pp 195–227

(18) Lichtenberger G. Reversible lateralization of the paralyzed vocal cord without tracheostomy. Ann Otol Rhinol Laryngol 2002 111:21–26

(19) Lichtenberger G. Laryngeal microsurgical laterofixation of paralyzed vocal cords using a new suture instrument. Laryngorhinootologie 1989 68:678–682

(20) Rovó L, Jóri J, Brzozka M, Czigner J Airway complication after thyroid surgery: minimally invasive management of bilateral recurrent nerve injury. Laryngoscope 2000 110:140–144

(21) Dejonckere PH, Bradley P, Clemente P, et al. A basic protocol for functional assessment of voice pathology, especially for investigating the efficacy of (phonosurgical) treatments and evaluating new assessment techniques. Guideline elaborated by the Committee on Phoniatrics of the European Laryngological Society (ELS). Eur Arch Otorhinolaryngol. 2001 Feb;258 (2):77-82.

(22) Jacobcon BH, Johnson A, Grywalski C, et al. The Voice Handicap Index (VHI) development and validation. Am J Speech Lang Pathol. 1997;6:66-70.

(23) Machulla R, Hacki T, Hoppe U, Rosanowski F. Voice Handicap Index (VHI) in inpatient voice rehabilitation medicine. HNO. 2006 Jan;54 (1):52-8. German

(24) Wuyts FL, De Bodt MS, Molenberghs G, et al. The dysphonia severity index: an objective measure of vocal quality based on a multiparameter approach. J Speech Lang Hear Res. 2000 Jun;43(3):796-809.

(25) Friedrich G. [External vocal cord medialization: functional outcome]. Laryngorhinootologie. 1998 Jan;77(1):18-26.

(26) Hacki T. Comparative speaking, shouting and singing voice range profile measurement: physiological and pathological aspects. Logoped Phoniatr Vocol. 1996;21(3-4):123-9. doi: 10.3109/14015439609098879. PMID: 21275582

(27) Cantarella G, Fasano V, Bucchioni E, Domenichini E, Cesana BM. Spirometric and plethysmographic assessment of upper airway obstruction in laryngeal hemiplegia. Ann OtolRhinol Laryngol 2003 112:1014–1020

(28) Kashima HK Documentation of upper airway obstruction in unilateral vocal cord paralysis: flow-volume loop studies in 43 subjects. Laryngoscope 1984 94:923–937

(29) Sztanó B Morphometric studies and a complex airway evaluation panel for objective and reliable assessment of laryngotracheal stenosis surgery. Ph.D. Thesis, University of Szeged, 2013

(30) Jaquet Y, Lang F, Pilloud R, Savary M, Monnier P. Partial cricotracheal resection for pediatric subglottic stenosis: long-term outcome in 57 patients. Thorac Cardiovasc Surg 2005 130:726–732

(31) Hess MM, Fleischer S. Laryngeal framework surgery: current strategies. Curr Opin Otolaryngol Head Neck Surg 2016 24:505–509

(32) Crumley RL Laryngeal synkinesis revisited. Ann Otol Rhinol Laryngol 2000 109:365–371

(33) Marina MB, Marie JP, Birchall MA Laryngeal reinnervation for bilateral vocal fold paralysis. Curr Opin Otolaryngol Head Neck Surg 2011 19:434–438

(34) Landau LD, Lifshitz EM (1986) Theory of elasticity. Pergamon Press, Oxford

(35) Woodson GE Configuration of the glottis in laryngeal paralysis I: clinical study. Laryngoscope 1993 103:1227–1234

(36) von Leden More P The mechanics of the cricoarytenoid joint. Arch Otolaryngol 1961 73:541–550

(37) Crumley RL (1993) Endoscopic laser medial arytenoidectomy for airway management in bilateral laryngeal paralysis. Ann Otol Rhinol Laryngol 102:81–84

(38) Woodson GE. Spontaneous laryngeal reinnervation after recurrent laryngeal or vagus nerve injury. Ann Otol Rhinol Laryngol. 2007 Jan; 116(1):57-65.

(39) Werner JA, Lippert BM. [Lateral fixation of the vocal cord instead of tracheotomy in acute bilateral vocal cord paralysis]. Dtsch Med Wochenschr. 2002 Apr 26;127(17):917-922.

(40) Kashima HK. Bilateral vocal fold motion impairment: pathophysiology and management by transverse cordotomy. Ann Otol Rhinol Laryngol. 1991 Sep;100 (9 Pt 1):717-721.

(41) Sittel C, Stennert E, Thumfart WF, Dapunt U, Eckel HE. Prognostic value of laryngeal electromyography in vocal fold paralysis. Arch Otolaryngol Head Neck Surg. 2001 Feb;127(2):155-160.

(42) Van LK, D'haeseleer E, Wuyts FL, Baudonck N, Bernaert L, Vermeersch H. Impact of thyroidectomy without laryngeal nerve injury on vocal quality characteristics: an objective multiparameter approach. Laryngoscope. 2010 Feb;120(2):338-345.

(43) Hans S, Vaissiere J, Crevier-Buchman L, Laccourreye O, Brasnu D. Aerodynamic and acoustic parameters in CO2 laser posterior transverse cordotomy for bilateral vocal fold paralysis. Acta Otolaryngol. 2000 Mar;120(2):330-335.

(44) Wani MK, Yarber R, Hengesteg A, Rosen C, Woodson GE. Endoscopic laser medial arytenoidectomy versus total arytenoidectomy in the management of bilateral vocal fold paralysis. Ann Otol Rhinol Laryngol. 1996 Nov;105(11):857-862.

(45) Friedrich G, Kainz J, Freidl W. [Functional structure of the human vocal cord]. Laryngorhinootologie. 1993 May;72 (5):215-224.

(46) Isshiki N. Vocal mechanics as the basis for phonosurgery. Laryngoscope. 1998 Dec;108(12):1761-1766.

(47) Pruszewicz M, Szmeja Z, Pruszewicz A, Pospiech I. [Voice and spirometric examinations in patients after laser arytenoidectomy]. Otolaryngol Pol. 1995;49 (1):23-26.

(48) Smehák G: Complex voice measurement panel for the assessment of the functional evaluation of the laryngeal surgical interventions. PhD Thesis, Szeged 2010

9. APPENDIX

Kérdőív

Név:
Cím:
Telefonsz.:
Dátum:
Foglalkozás:
Diagnózis:

Jelölje meg azt a választ, amely megmutatja milyen gyakran fordulnak elő a következő állítások Önnel! Válaszok: 0 = soha, 1 = elvétve, 2 = néha, 3 = gyakran, 4 = mindig

F1	A hangomat nehezen hallják meg mások.	0	1	2	3	4
P2	Ha beszélek, kifulladok.	0	1	2	3	4
F3	Az embereknek nehéz megérteni engem egy hangos teremben.	0	1	2	3	4
P4	A hangszínem változik a nap folyamán.	0	1	2	3	4
F5	A családomnak nehézséget okoz meghallani, ha a házban/ lakásban hívom őket.	0	1	2	3	4
F6	Kevesebbszer használom a telefont, mint szeretném.	0	1	2	3	4
E7	Feszült leszek a hangom miatt, ha másokkal beszélek.	0	1	2	3	4
F8	A hangom miatt hajlamos vagyok arra, hogy a nagyobb társaságokat elkerüljem	0	1	2	3	4
E9	Az emberek felfigyelnek a hangomra, mert zavaró.	0	1	2	3	4
P10	Az emberek megkérdezik: „Mi történt a hangoddal?”	0	1	2	3	4
F11	A hangom miatt ritkábban beszélek barátokkal, szomszédokkal, rokonokkal.	0	1	2	3	4
F12	Az emberek megkérnek, hogy ismételjem meg azt, amit mondtam.	0	1	2	3	4
P13	A hangom érdes és fakó.	0	1	2	3	4
P14	Úgy érzem, meg kell erőltetnem magam, ha a hangomat használom.	0	1	2	3	4
E15	Úgy érzem, mások nem értik meg a problémámat a hangommal.	0	1	2	3	4
F16	A nehézségeim a hangommal korlátoznak a magán, és üzleti életben.	0	1	2	3	4
P17	A hangom érthetősége kiszámíthatatlan.	0	1	2	3	4
P18	Megpróbálom a hangom megváltoztatni, hogy másképpen csengjen.	0	1	2	3	4
F19	Társaságban kirekesztettnek érzem magam a hangom miatt.	0	1	2	3	4
P20	Nagy erőfeszítésembe kerül, hogy beszéljek.	0	1	2	3	4
P21	A hangom esténként rosszabb.	0	1	2	3	4
F22	A hangproblémáim miatt kevesebbet keresek.	0	1	2	3	4
E23	A hangproblémám bosszant.	0	1	2	3	4
E24	A hangom problémái miatt kevésbé jövök ki magammal.	0	1	2	3	4
E25	A hangom miatt gátoltnak érzem magam.	0	1	2	3	4
P26	A hangom „elhagy” beszéd közben.	0	1	2	3	4
E27	Bosszant, ha megkérnek, hogy ismételjem meg amit mondtam.	0	1	2	3	4
E28	Zavarba jövök, ha megkérnek, hogy ismételjem meg amit mondtam.	0	1	2	3	4
E29	A hangom miatt úgy érzem, tehetetlen vagyok.	0	1	2	3	4
E30	Szégyellem magam a hangom miatt.	0	1	2	3	4
	Hogyan jellemezné a hangját ma?	0	1	2	3	4

0 = normális, 1 = kissé hibás, 2 = közepesen hibás, 3 = nagymértékben hibás

’Quality of life’ kérdőív
felső légúti szűkületes betegek számára

Név:

Dg.:

- **Nehézlégzés**
  1. Nincs
  2. Nehéz munkavégzés esetén
  3. Enyhe fizikai megerőltetés esetén is
  4. Nyugalomban
  5. Tracheotomia

- **Hangos légzés**
  1. Nincs, a légzés hangtalan
  2. Nehéz munkavégzés eseten hangossá váló légzés
  3. Enyhe fizikai megerőltetés esetén is hangos
  4. Nyugalomban
  5. Tracheotomia

- **Köhögés**
  1. Nincs köhögés
  2. Enyhe köhögés
  3. Erős köhögés
  4. Tracheotomia

- **Hangképzési panasz**
  1. Normális
  2. Kis fokú beszédzavar (hangos környezetben nehezebben érthető)
  3. Súlyos beszédzavar
  4. Aphonia

- **Nyelési panasz**
  1. Normális
  2. Kisebb nehézségek, időnkénti félrenyelés
  3. Súlyos nyelészavar

- **Elégedettség az állapottal**
  1. Teljesen elégedett
  2. Nagyrészt elégedett
  3. Kissé elégedetlen
  4. Elégedetlen