Department of Traumatology, Albert Szent-Györgyi Medical and
Pharmaceutical Centre, University of Szeged, Hungary
and
Department of Traumatology, Division of Surgery, John Hunter Hospital,
Newcastle, NSW, Australia

PhD thesis

Acute management of high-energy pelvic ring injuries

Laszlo Toth MD

Supervisor:
Prof. Zsolt J. Balogh, MD, PhD, FRACS (Ortho)
Trauma/Orthopaedic Surgeon, John Hunter Hospital
Director of Trauma Services, Hunter New England Area Health Service
Discipline Head of Traumatology, University of Newcastle

Szeged, Hungary
2012

Peer reviewed scientific publications related to this thesis

Papers

I. **Toth L**, McGrath B, King K, Balogh Z: Efficacy and safety of emergency non-invasive stabilization of the pelvic ring. *Injury*, 2012 (43) 1330-1334
IF 1.975

II. **Toth L**, Balogh Zs. Unilateral dislocation of sacroiliac joint with intact anterior pelvic ring: report of 2 cases. *J of Trauma*, March 2010 (68) E83-E86
IF 3.129

III. Enninghorst N, **Toth L**, King KL, McDougall D, Mackenzie S, Balogh ZJ. Acute definitive internal fixation of pelvic ring fractures in polytrauma patients: a feasible option. *J of Trauma*. 2010 (68) 935-941
IF 3.129

IV. **Toth L**, King KL, McGrath B, Balogh ZJ. Early prediction of pelvic fracture related arterial bleeding during trauma resuscitation: a prospective clinical study. Submitted for publication to *J Orthop Trauma*. Oct 2012

Abstracts

1. **Toth L**, Mackay P, Smith S, Deane S, Balogh Zs. Rectal injuries in association with pelvic ring disruptions. *9th European Congress of Trauma and Emergency Surgery*, Budapest, 2008. (oral presentation)

2. **Toth L**, King K, McGrath B, Balogh ZJ. Safety and efficacy of emergency non-invasive pelvic ring stabilization. *10th European Congress of Trauma and Emergency Surgery*, Antalya, Turkey, 2009. (oral presentation)

3. **Toth L**, McGrath B, King K, Balogh Z. Prediction of pelvic fracture related arterial bleeding: a prospective clinical study. *11th European Congress of Trauma and Emergency Surgery*, Brusseles, Belgium, 2010. (oral presentation)

Acknowledgements

Professor Zsolt J Balogh gave me great inspiration with his commitment and enthusiasm to both clinical trauma care and scientific research. Since the beginning of my surgical training he trusted in my work more than anybody. He was daring to put the load on my shoulders. He showed the fine example of the state of the art trauma surgeon, great leadership and mentoring. He gave me all his support in planning and conducting the studies related to this thesis, and plenty of opportunity to improve my knowledge and skills. During the preparation of the thesis, when we had 15.690 km between, he could still help and supervise just like when working in the same team in Newcastle. Besides being teacher, leader and mentor he was also a good friend.

Under Dr Balogh's leadership the Trauma Department at the John Hunter Hospital was full of great opportunities in an inspirational and friendly atmosphere. Kate King started and continued the demanding and endless work of collection of data for the studies related to this thesis. Julie Evans, Deb McDougall and Peter MacKay were always keen to help with all different tasks related to the studies and everyday work. Professor Balogh's secretary, Anne Louise Abel was always available and very quick to help. Other trauma fellows, Karlijn van Wessem and Tim Pollit, sheared lot of clinical duties to save time for research. Natalie Enninghorst continued my work and helped to finalize the studies.

Ben McGrath from the Orthopaedic Department at the Royal Newcastle Centre, worked hard on data collection and preparation for the studies.

I had received great amount of support from Professor János Aurél Simonka at the Department of Traumatology at Szeged. He was always open to my ideas related to research and patient care. Nothing was impossible if it was for the better care of the patients.

Professor Endre Varga shared his passion about pelvic fractures with me since the early days of my training. He was also mentoring and supervising my surgical training, clinical work and research activity. He gave me the chance to be active member of ATLS Hungary and AO Trauma.

At the very beginning of my surgical training at The Department of Traumatology, University of Szeged, I had a fantastic team together with László Török and János Tomka. Under their supervision I learned the principles of team work. It is 'their fault' that I got infected with this profession and proceeded towards surgical career.

I am grateful to all consultants and fellow workers at the Department of Traumatology, University of Szeged, who gave me the chances to improve my skills in patient care and shared the load of duties to save time for scientific work.

Finally, I thank my family, especially my wife Réka Viola for all her support. In the busy work of running our family, she takes the most. She is the stable background to rely on. Being an active researcher herself and PhD, she helped a lot in the statistic analysis of data in the studies. She does it all with her lovely style.

Table of Contents

List of abbreviations

AIS	Abbreviated Injury Scale
AO	Arbeitgemeinschaft fur Osteosynthesefragen
ATLS	Advanced Trauma Life Support
BD	Base Deficit
BP	Blood Pressure
CT	Computed Tomography
DPA/DPL	Diagnostic Peritoneal Aspiration/ Lavage
ED	Emergency Department
FAST	Focused Abdominal Sonography on Trauma
HE-PRI	High-Energy Pelvic Ring Injury
ICU	Intensive Care Unit
ISS	Injury Severity Score
ITIM	Institute of Trauma and Injury Management
NSW	New South Wales
OTA	Orthopedic Trauma Association
PFRAB	Pelvic Fracture Related Arterial Bleeding
PB	Pelvic Binding
PR	Per Rectum
PRBC	Packed Red Blood Cells
ROC	Receiver Operator Characteristics
SIJ	Sacro-Iliac Joint

Introduction

High-energy pelvic ring injuries have significant mortality and morbidity associated. They represent great challenge to the managing team even in the well prepared, high volume trauma centres. [1, 2, 3, 4, 5, 6, 7, 8] The John Hunter Hospital is a state designated peer-verified level 1 trauma centre in NSW, Australia, a primary referral centre for a population of 1.100.000 and area of 130.000km². All severely injured patients, including all *high-energy pelvic ring injuries* (HE-PRI), are brought to this centre either directly from the accident scene or through referring hospitals. This is the busiest trauma centre in the state of NSW with 4500 trauma admissions per year including >400 patients with ISS>15. Earlier prospective clinical study from the same institute [9] described the population based epidemiology of pelvic ring fractures, and identified areas with potential for improvement. Despite all great efforts on bleeding control, these severe injuries still can cause exsanguination, which is the main cause of early mortality [9, 10, 11].

Bleeding control is achieved with combination of procedures. Different management strategies exist, but all include haemostatic resuscitation with fluids, detection and control or exclusion of extra-pelvic bleeding, and some sort of pelvic ring stabilization (either non-invasively or invasively). There are several studies showing benefits of emergency non-invasive pelvic ring stabilization [12, 13, 14], but very little data is available so far on the efficacy and safety of the method [15]. Since emergency non-invasive pelvis stabilization was recommended by ATLS [16] and ITIM NSW [17, 18], and is widely used, concerns about safety arouse.

Bleeding associated with pelvic fractures comes from the broken bone, the pelvic venous plexus and from named arteries and branches [1, 19, 20, 21, 22]. Pelvic fracture related arterial bleeding (PFRAB) requires special attention. The high-pressure arterial bleeding is usually not self limiting like some of the low-pressure venous bleeders. Using angiography for diagnosis and treatment of PFRAB is widely used [17, 18, 23, 24, 25, 26]. There is general agreement that it is the best option to control PFRAB however

timing of the procedure is less uniform. Early identification of best candidates for therapeutic angiogram is much needed.

The pelvic ring injury is managed in stages (acute temporary fixation followed by definitive surgery) usually, but selected patients may benefit from acute definitive pelvic fixation. The role, safety and feasibility of acute definitive pelvic ring fixation need to be determined.

Survivors of shock may have potentially significant associated injuries responsible for later complications and sometimes suboptimal outcomes [1, 3, 4, 6, 27]. Rectum injuries have known association with pelvic ring injuries [28, 29]. Late diagnosis carries risks of morbidity and mortality [30, 31, 32]. The first step to recognize these associated injuries is to understand the injury patterns they occur.

Based on clinical needs described above, we set up our primary aims for our clinical research projects on the acute management of HE-PRI:

1. Determine the safety and efficacy of non-invasive emergency pelvic ring fixation.
2. Determine predictors of PFRAB from measures available early in the Emergency Department (ED).
3. Determine the role of acute definitive pelvic ring stabilization in patients with multiple injuries.
4. Identify patterns of pelvic ring injuries with associated rectum tears.

Four different clinical studies were carried out to achieve our goals. On the sideways of understanding these complex injuries we identified injury patterns with less focus on in previous studies. We described rare cases of unilateral sacro-iliac joint (SIJ) disruption, with intact anterior pelvic ring, as a result of high-energy injury.

1. Safety and efficacy of non-invasive emergency pelvic ring stabilization

Background

Emergency evaluation of patients with HE-PRI focuses on quick evaluation of the physiology with measures of vital signs and acid/base status. If signs of shock are present, always major bleeding is expected to be the cause. It is crucial to determine or exclude all other potential bleeding sources (chest, abdomen, long bone fractures and external). During the primary survey external bleeding and long bone fractures are recognized by physical examination and are controlled by manual pressure on wounds, application of bandages, sutures and splinting of long bone fractures. To assess internal bleeding AP chest and pelvis radiographs are taken and the abdomen is assessed by physical examination and Focused Abdominal Ultrasound on Trauma (FAST) or Diagnostic Peritoneal Aspiration/Lavage (DPA/DPL). Pelvic bleeding may be self limiting in some cases, but most of the time requires a well organized effort to achieve haemostasis. There is no single effective method, but multiple steps to succeed. There is no general agreement in the way these haemostatic efforts are carried out and no agreement in the best sequence. Local resources and team training play important role in the development of institutional guidelines to manage these challenging situations [17, 18, 23, 24, 25, 26]. Beside haemostatic resuscitation with blood products and fluids, all guidelines include some sort of emergency pelvic ring stabilization: either non-invasively with application of sheet wrapping or custom made orthesis or invasively with an external fixator [33] or the pelvic C-clamp [34].

Emergency non-invasive pelvic ring immobilization is recommended by ATLS [16] and also by state level (ITIM) evidence-based guidelines [17, 18]. The technique of Pelvic Binding (PB) is described and recommended to use immediately when pelvic ring injury is recognized or highly suspected. Ambulance personnel are also encouraged to use PB at the accident scene without any possibility to perform imaging. Since the introduction of the institutional guidelines, application of pelvic binding became very frequent. There is little known about the efficacy of the method. A recent systematic

literature review by Spanjersberg et al [15] concluded that publications so far reported the method being effective in reducing fractures and associated haemorrhaging. They also concluded that the nature, severity and rates of related complications are not known. Anecdotal reports recorded potential adverse events related, such as skin necrosis due to pressure [35, 36], pierced bladder by bone fragments and neurologic deficit due to compressed nerve roots, and concerns about safety of PB arouse. We aimed to test adherence to our guidelines and to test safety and efficacy of emergency non-invasive pelvic ring stabilization in a clinical study. We hypothesized that the adherence to PB guidelines in our institution is good and the PB improves the position of the pelvic ring without major complications.

Patients and methods

All patients admitted to the John Hunter Hospital with HE-PRI were entered into an electronic data base starting in March 2005. Data collection included demographics (age, gender), mechanisms of injury, associated injuries, physiological parameters (blood pressure, BP, heart rate, HR, temperature, T, Ph, base deficit, BD, lactate), trauma scores (ISS, AIS pelvis), fracture types (according to AO/OTA [37, 38] and Young-Burgess classification systems [39]) resuscitation fluids (blood products) procedures (application of PB, angiography/embolization, temporary and definitive pelvic ring fixation, laparotomy findings), complications and outcomes (mortality, length of ICU and hospital stay).

In this study 41 months of data were assessed (May 2005-August 2008). All patients with HE-PRI were included. Patients with stable pelvic rings (AO/OTA 61 A type injuries) and those with acetabulum fractures with intact pelvic ring were not considered. Patients who were demonstrated no signs of life on arrival or died before imaging at the Emergency Department (ED) were also excluded. Haemorrhagic shock on presentation was defined as a need for transfusion in the ED or presence of significant acidosis with base deficit (BD) >6 mmol/L. According to the institutional protocols all patients in haemorrhagic shock with a pelvic fracture (regardless the fracture pattern) should have PB applied immediately. The technique of PB consists of application of a

bed sheet around the pelvis at the level of the greater trochanters followed by crossing the sheet and clamping it at four points. In some cases a special orthesis (pelvic circumferential compression device) was used at the scene by ambulance personnel. In all cases knees were also bound together with a sheet or bandage, as per protocol. As a standard procedure in all cases of vertical displacement, manual traction was applied on the shortened lower limb to reduce the cranial displacement before the binding was tightened. Binding was either removed in the operating theatre at the time of pelvic ring fixation or removed/loosened on the ward by the trauma team after 24h, whichever happened earlier.

This study examined the adherence to the in-hospital guidelines exclusively. After this study period the prehospital application of pelvic binding protocol was implemented. No patients are included in this study from the time period after implementation of the prehospital protocol.

Pelvic radiographs (AP pelvic radiograph and/or CT scans) before and after the application of PB was reviewed. Pre- and post-binding images were compared when possible. The effect of PB was categorized as `Perfect` if near anatomic alignment of the pelvic ring was achieved, `Improved` if the alignment had improved, but still significant displacement was present, `not changed` if the alignment had not changed and `worse` if the deformity or displacement had increased.

All patients identified with local complications, such as associated femoral vessel, rectum and bladder injuries, were assessed individually by independent experts to find out if there was any possible relationship between the injury and PB.

Results

There were 115 patients included in this study with AO/OTA B and C type unstable high-energy pelvic ring injuries including 102 primary admissions and 13 transfers from the referring area. Patients had age 43.5±19.7 years, 80 were male (70%) and 35 female (30%), with ISS of 26±14.

There were 43 patients who had PB applied. The utilization of PB was 43/115 (37%) of the unstable HE-PRI. Regarding the specific fracture types the following

utilization was found: B1 13/16 (81%), B2 8/57 (14%), B3 5/12 (42%), C1 10/19 (53%), C2 6/8 (75%), C3 1/3 (33%). (Figure 1)

Figure 1 Utilization of PB by fracture pattern (AO/OTA)

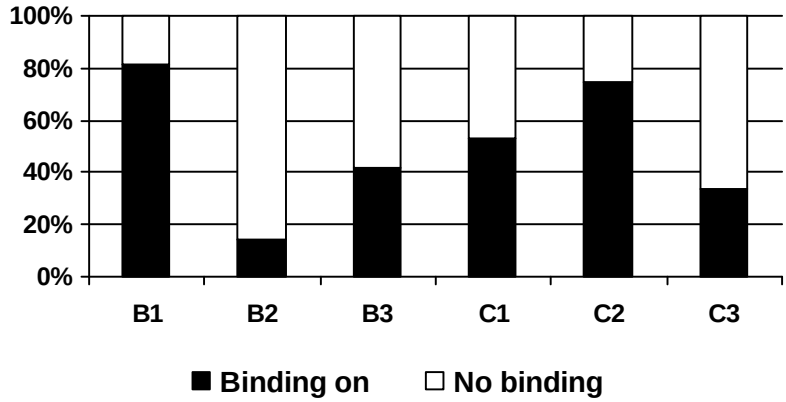

There were 36/115 (31%) patients who had significant blood loss resulting in haemorrhagic shock. The utilization of PB in shocked patients, giving the adherence to the guidelines, was 18/36 (50%). There was good adherence to the guidelines in cases of B1 type 4/5 (80%) and C type 11/16 (68%) fractures. Adherence was poor in cases of B2 type 2/10 and B3 type 1/5 fractures (both 20%). (Figure 2)

Figure 2 Utilization of PB in shocked patients by fracture pattern

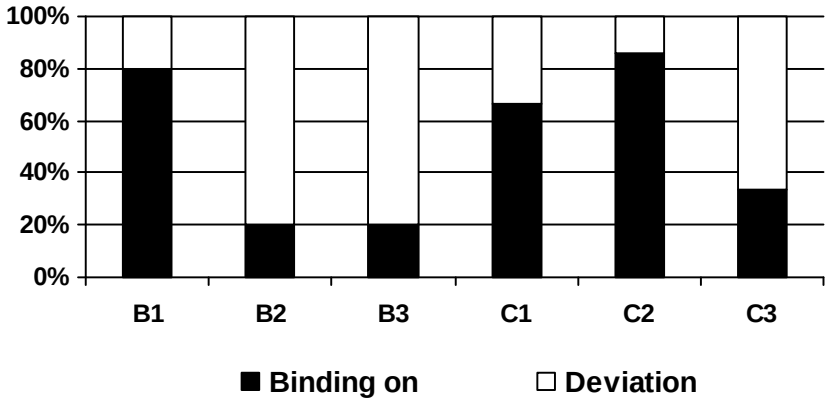

Application of PB was performed in the ED after AP pelvic radiographs in 23 (53%) and before imaging in 3 (7%) cases. Binding was applied at the scene in 12 (28%) cases and at the referring hospital ED in 5 (12%) cases.

Binding was removed in the ED in 5 (12%) cases, in the operating room at the time of acute pelvic stabilization (<24h) in 23 (53%) cases, and at the time of planned operative pelvic fixation (>24h) in 10 (23%) cases. In all cases when PB was left on longer than 24h, it was loosened to prevent pressure area development. In one case PB was changed for a pelvic orthesis that was used for non-operative management.

The efficacy of PB in terms of reducing the pelvic ring was checked on post binding radiographs in 23 cases (53%) and also on post binding CT scans in 28 cases (65%). In 29 cases (67%) comparison of the pre PB and post PB images was performed. “Perfect” pelvic ring alignment was achieved in 18 cases (42%), alignment had “Improved” in 11 cases (26%), had not changed in 9 cases (21%) and was “Worse” in 5 cases (11%). (Figure 3)

Figure 3 Efficacy of PB demonstrated on imaging

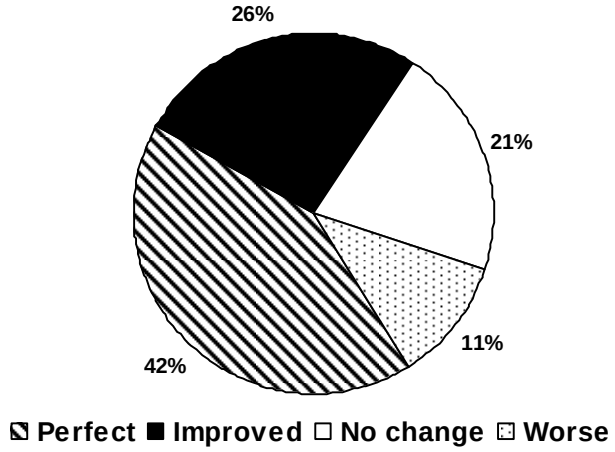

Analysing the specific fracture types, good effect was demonstrated (“Perfect” or “Improved” alignment) with all the B1 13/13 (100%), and most of the C type fractures 14/17 (82%). In 5 cases we noticed increased deformity after PB application: B2 types 3/8 (37%) and B3 types 2/5 (40%). (Figure 4)

Figure 4 Efficacy of PB by fracture patterns

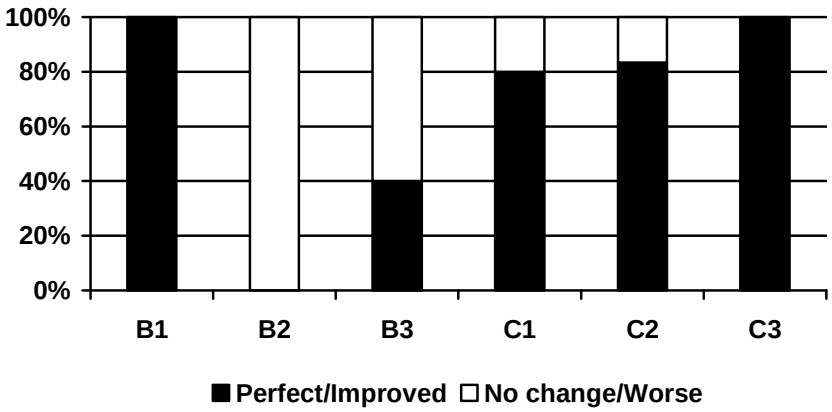

The mortality of the cohort was 10/115 (7.8%). Four patients died within a few hours after arrival due to uncontrolled major bleeding, with the pelvis identified as the main source of blood loss. Two of them had PB applied in the ED in a timely fashion. Two cases were identified as cases with potential for improvement, as they had either no PB applied or not in a timely fashion (>1 hour of arrival).

Safety analysis was performed in each case with associated femoral vessel, bladder and rectum injury. There was one patient with common femoral artery injury diagnosed by angiography. There was no sign of limb ischaemia due to the arterial injury. The patient had combination of a both column acetabulum fracture and a type B3.1 pelvic ring injury. Binding was applied in the ED after AP pelvis radiograph and was removed 4 hours later in the operating theatre. The patient had operative stabilization of the acetabulum and open reduction of his locked pubic symphysis on day 3 after his accident. During surgery a sharp bone fragment was found close to the femoral vessels, but penetrating injury was excluded. (Radiograph 1A, B, Appendix)

There were three patients with rectum tears associated with pelvic ring injuries. All patients had PB applied. All pelvic ring injuries were pure ligamentous disruptions (B1.1 type with diastasis of the pubic symphysis) and penetration of a bone fragment could be excluded.

There were 10 patients with bladder injuries, all extraperitoneal; four of them had PB applied. In one case there was no bone fragment nearby (B3.2 type injury with locked

pubic symphysis). In the other 3 cases there was at least one sharp bone fragment close to the bladder very likely to cause the injury. Application of the binding as a cause of the bladder injury in these cases was not likely, but could not be excluded. (Radiograph 2A, B, Appendix)

There was no case of neurologic deficit as a result of sacral nerve root damage or nerve compression in any of the patients. No skin pressure area or necrosis developed around the pelvis in any of the patients.

Discussion

Non-invasive emergency pelvic ring stabilization of the trauma victim, demonstrating signs of haemorrhagic shock, is recommended by numerous guidelines, protocols and experts [26, 23, 24, 40, 41, 42], including the ATLS [16] and NSW state guidelines [17, 18]. The utilization of PB have increased, however little data is available on the safety and efficacy of the technique. Application of PB is performed by the first care providers who are usually not experts on pelvic fractures and may have limited resources for imaging. Our study showed that application of PB by the first care providers is safe, even without any imaging available. We had surprisingly low adherence to the guidelines, particularly in type B2 and B3 fractures (both 20%), which is concerning. We cannot determine the causes behind this in retrospect. Further education and early involvement of senior staff should result in improved care.

There has been only one previous clinical study assessing the efficacy of PB on various fracture patterns. A clinical trial by Krieg et al [15] demonstrated significant improvement of the pelvis alignment both in coronal and vertical planes in external rotation (B1, C1, C2) type fractures. Internal rotation fractures (B2, B3 types) also had decreased pelvic width, which in these cases may mean over compression. Our results supported Krieg et al's findings with perfect or improved alignment in all B1 type fractures and the majority of C type fractures. The alignment had not changed in most B2 types. 'Worse' alignment was noticed in some B2 and B3 types. A biomechanical study on human cadavers by Bottlang et al [43] demonstrated that application of circumferential compression with a pelvic strap was effective in reducing external

rotation-type pelvic fractures. The same research group in another human cadaver study [44] determined the optimal application parameters for circumferential compression of open-book (B1 type) pelvic fractures. In their safety analysis they modelled a worst case scenario of an unstable lateral compression (internal-rotation) fracture and found no significant over reduction. They found the non-invasive pelvic sling to be effective and safe method for reducing and stabilizing open-book pelvic fractures even at the accident scene.

Too early removal of PB risks re-displacement of the pelvis, dislodging of clots resulting in increased bleeding and worsening of haemodynamics. Too late removal risks skin integrity as pressure areas may develop. Although we have not recognized any problems with leaving the binding on for up to 24 hours, we cannot recommend leaving it on any longer than that. In high risk cases when PB is applied in presence of local soft tissue compromise due to the injury, removal should be as soon as possible. In a study on healthy individuals with PB applied sites of potential risk for pressure areas were identified [45]. If the fracture pattern is not likely to benefit from further lateral compression (B2 and some of the B3 types) we consider loosening or removal of the binding immediately based on decision of the attending orthopaedic trauma consultant. We could not find any evidence of complications associated with binding of these fractures. We have found PB to offer less potential benefit for type B2 and some B3 fractures; however we think inclusion of any fracture classification system in the guidelines would create confusion, because the first trauma care providers have no training in the definitive management of pelvic ring injuries and have limited diagnostics.

Assessment of PB effect on haemodynamics was outside the focus of this study. Comparison of those shocked patients who had PB applied and those who did not (50% each) might seem a reasonable idea. Such comparison would be misleading due to possible selection bias, because we did not do randomization. A clinical study by Croce et al [46] demonstrated superior effect of PB on haemodynamics compared to external fixation such as less transfusion requirements, decreased mortality and shorter hospital stay. Another study by Ghaemmaghami et al [47] showed no difference in transfusion

requirement or mortality with use of PB compared to historical control group in their retrospective study.

We had some pelvic fracture cases with associated internal organ damage. The relationship between the PB and the associated organ damage could be excluded in all cases of rectum and femoral vessel injuries. Bladder injuries were also most likely the result of the accident, but exclusion of a possible iatrogenic injury is more difficult in these cases. There are other possible complications reported in the literature such as skin breakdown or necrosis [35, 36] and peroneal nerve palsy [48] as a result of a second sheet applied around the knees. We did not find any of these complications.

Another potential `disadvantage` of PB is the restoration of the anatomy of the pelvic ring, resulting in underestimation of the severity of the injury. If near anatomic or anatomic alignment appears on static imaging but there are concerns about a possible unstable injury, stability should be tested under image intensification preferably in the OR by an expert surgeon to decide if the pelvis requires operative stabilization.

We have realized some limitations of the study. Having no control group is a limitation and probably a missed opportunity as pelvic binders are now commonly applied in the prehospital phase following the introduction of a new protocol for the ambulance service of NSW in 2009. This has limited our ability to demonstrate cause and effect with the use of PB.

2. Early prediction of pelvic fracture related arterial bleeding

Background

Major bleeding associated with HE-PRI is the main cause of early mortality associated [9, 10]. Pelvic bleeding may originate from the broken bones, pelvic venous plexus, and named vessels and branches [1, 19, 20, 21, 22]. Major bleeding is a combination of these with the proportions impossible to determine, most likely variable in each case. Bleeding from the bones can be controlled with emergency stabilization either non-invasively or invasively with application of external fixator [33] or pelvic clamp [34]. Acute definitive pelvic ring fixation plays important role as well (see next study). Venous bleeding might be self-limiting with haemostatic resuscitation and stabilization of the pelvis. The role of pelvic packing was investigated and reported in a number of studies [49, 50, 51, 52]. The arterial component of pelvic bleeding (PFRAB) requires different therapeutic interventions. Some arterial bleeders in younger individuals might be self limiting; however there is no hard evidence to support it. Elderly people have sclerotic changes in their arteries making them more vulnerable for injuries and less able to limit bleeding with spasm [53, 54]. Angiography and embolization for control of PFRAB is reported to be effective in many studies [19, 54, 55, 56, 57, 58, 59, 60]. Using angiography as a screening tool for PFRAB however is not feasible due to logistics. Performing pelvic angiography requires patient transfer to a fully equipped angiography suite with an experienced interventional radiologist available. Resuscitation of the trauma victim has to continue in the angiography suite. The procedure offers therapeutic option to control bleeding with very good effect. On the other hand, a non-therapeutic study takes valuable time while other potentially life saving efforts are delayed. It is crucial to identify those candidates who have best chances for a therapeutic intervention. Predictors of PFRAB were identified in previous studies [2, 3, 53, 54, 61, 62, 63, 64, 65, 66, 67, 68, 69, 70, 71, 72, 73, 74, 75, 76], but most have limited clinical value due to poor/no availability in the ED. We aimed to identify those predictors of PFRAB that are available within 30-60 minutes after patient arrival to ED. We hypothesized that PFRAB is predictable from information available in the ED within 30-60 minutes of arrival.

Patients and methods

Consecutive trauma patients admitted to the level-1 trauma centre with HE-PRI were included in this study for 46 months period (March 2005-Dec 2008). Patients younger than 18 years, demonstrating no vital functions on arrival and transfers from another hospital with more than 4 hours of delay were excluded.

Initial management in ED was based on ATLS and New South Wales trauma guidelines. Resuscitation bay diagnostics included antero-posterior chest and pelvis radiographs, serial observations of vital parameters including blood pressure, heart rate, respiratory rate measurements, pulse-oxymetry, serial arterial blood gas analysis and FAST and/or DPL/DPA. External bleeding was immediately controlled by direct pressure or sutures. Emergency non-invasive pelvic ring stabilization (PB) was performed either in the prehospital phase or in the ED within a few minutes of arrival. Decision for early blood transfusion was made by the trauma team leader (ED physician or trauma surgeon/fellow) individually in each case considering vital parameters, response to initial fluid resuscitation and estimated blood loss. The initial FAST (and/or DPL/DPA) exam was used to triage shocked patients; those with positive results were taken to the operating theatre for laparotomy immediately. Patients with negative initial FAST results or positive results but no signs of shock were further assessed with CT scans and/or pelvic angiogram. Pelvic angiogram was indicated based on the discretion of the attending surgeon. The time to angiography was 30-240 minutes after arrival in ED in all cases. Pelvic fracture-related arterial bleeding (PFRAB) was defined if identified on pelvic angiography (extravasation of contrast material), or on CT angiogram (contrast blush into the pelvic haematoma) or during laparotomy (rapidly expanding pelvic haematoma). Those patients who were identified as candidates for angiography (either on pelvic CT angiogram or laparotomy finding) but died before it could be carried out (4 cases) were categorized as having PFRAB.

For details of data collection please see methods of study 1. Potential predictors were analysed using standard statistical tests (SPSS for Windows version 13.0). Univariate analysis (student's t test and Fisher's exact test) was performed for each

variable. After testing normality of categorical variables (one-sample Kolmogorov-Smirnov test) the association between PFRAB and all variables were measured by Pearson correlation. Receiver-operator characteristics (ROC) were analysed for all continuous variables. Area under the curve was assessed and cut-off value was determined. Decision tree analysis was also performed for all variables and cut-off values were determined. Data is presented as mean ± SD or percentages, $p<0.05$ was considered significant.

Results

There were 182 patients admitted with HE-PRI during the study period. After exclusion of patients with age <18 years (15 patients), dead on arrival (5 patients) and admitted >4 hours after the accident (19 patients), 143 patients were included in the study. There were 15 (10%) patients identified as having PFRAB: 11 on pelvic angiography, one on CT angiogram and three on laparotomy findings. There were no complications or adverse events associated with angiography/embolization.

Univariate analysis showed that patients with PFRAB were significantly older; more severely injured (both ISS and AIS pelvis), had lower blood pressures (SBP 1st, SBP worst and MAP), were more acidotic (pH and BD worst), required more often transfusions in ED and required more units of transfusions in the first day than non-PFRAB patients. They also had a higher mortality rate. (Table 1A, 1B)

Table 1A 1B Univariate analysis of continuous and categorical variables

	Total *N= 143*	**PFRAB** *N=15*	**Non-PFRAB** *N=128*	
	Mean (±SD)	**Mean (±SD)**	**Mean (±SD)**	***P****
Age	43.87 (±19.29)	54.93 (±20.11)	42.57 (±18.85)	0.018
ISS	23.88 (±14.30)	42.33 (±16.53)	21.71 (±12.39)	0.000
AIS	3.0 (±1.01)	4.2 (±1.15)	2.86 (±0.91)	0.000
pH 1st	7.29 (±0.10)	7.31 (±0.09)	7.21 (±0.13)	0.014
pH worst	7.26 (±0.14)	7.10 (±0.21)	7.28(±0.10)	0.000
BD 1st	4.11 (±5.64)	6.09 (±9.84)	3.74 (±4.47)	0.378
BD worst	5.58 (±6.73)	11.38 (±11.29)	4.51 (±4.90)	0.035
dBD	1.58 (±3.43)	5.76 (±6.06)	0.79 (±1.86)	0.007
SBP worst	104.15 (±22.17)	82.13 (±27.89)	106.72 (±19.99)	0.000
SBP 1st	119.59 (±24.07)	101.6 (±24.17)	121.64 (±23.26)	0.002
MAP	89.67 (±18.93)	79.38 (±23.21)	90.88 (±18.09)	0.025
Temperature	36.07 (±1.04)	36.02 (±0.72)	36.07 (±1.07)	0.849
LOS (days)	26.46 (±30.17)	24.07 (±33.11)	26.74 (±29.94)	0.850
Transfusion <24h (Units)	2.90 (±5.69)	13.53 (±9.55)	1.66 (±3.36)	0.000

		Total		**PFRAB**		**Non-PFRAB**		
		N	**%**	***N***	**%**	***N***	**%**	***P****
Mechanism of Injury	MVA driver	48	33.3	4	26.7	44	34.4	0.566
	MVA passenger	12	8.4	1	6.7	11	8.6	
	Motorbike rider	28	19.6	4	26.7	24	18.8	
	Pedestrian hit by car	22	15.4	2	13.3	20	15.6	
	High fall	13	9.1	2	13.3	11	8.6	
	Severe compression	5	3.5	0	0	5	3.9	
	Horse rider	6	4.2	0	0	6	4.7	
	Bicycle rider	9	6.3	2	13.3	7	5.5	
Young-Burgess	APC1	4	2.8	0	0	4	3.1	0.290
	APC2	13	9.1	3	20	10	7.8	
	APC3	5	3.5	3	20	2	1.6	
	LC1	73	50.3	3	20	69	53.9	
	LC2	20	14.0	0	0	20	15.6	
	LC3	3	2.1	0	0	3	2.3	
	VS	9	6.3	0	0	9	7.0	
	CM	17	11.9	6	60	11	8.6	
AO/OTA	A1, 2, 3	33	23.1	0	0	33	25.8	0.000
	B1	15	10.5	3	20	12	9.4	
	B2	62	42.7	3	20	58	45.3	
	B3	10	7.0	1	6.7	9	7.0	
	C1	14	9.8	2	13.3	12	9.4	
	C2	8	5.6	5	33.3	3	2.3	
	C3	2	1.4	1	6.7	1	0.8	
Transfusion in ED	Yes	38	26.6	13	86.7	25	19.4	0.000
	No	105	73.4	2	13.3	104	80.6	
Mortality	Survived	133	93.0	10	66.7	125	97.7	0.000
	Died	10	7.0	5	33.3	3	2.3	
FAST	Negative	133	93.0	9	60.0	124	96.9	0.000
	Positive	10	7.0	6	40.0	4	3.1	

All variables were tested for correlation with arterial bleeding using the Pearson correlation test. Correlation with PFRAB (r>0.3) was found with the need for transfusion in ED, ISS, AIS pelvis, AO/OTA class, positive FAST in ED, pH worst, BD worst , dBD (difference between BD first and BD worst) and SBP worst. (Table 2)

Table 2 Pearson correlation test for all variables

	Correlation coefficient (r)
Age	0.19*
Sex	-0.05
ISS	0.44**
AIS pelvis	0.40**
MOI	0.05
Young-Burgess	0.08
OTA	0.34**
Transfusion in ED	0.46**
FAST	0.44**
Pelvic binding	0.26**
pH 1st	-0.34**
pH worst	-0.47**
BD 1st	0.15
BD worst	0.37**
dBD	0.53**
SBP worst	-0.34**
SBP 1st	-0.25**
MAP	-0.19*
Temperature	-0.01

**correlation is significant at the 0.05 level (2-tailed)*
***correlation is significant at the 0.01 level (2-tailed)*

Trauma scores (ISS, AIS pelvis) have prediction value, but are difficult or impossible to determine early, therefore are less useful for clinical decision making and were not assessed further. FAST was used as a clinical triage tool to select those patients who need immediate laparotomy, so a positive result cannot be used to triage for another treatment modality. Regarding the fracture pattern the Young-Burgess classification system had poor correlation (r=0.08). The AO/OTA classification system had better correlation (r=0.34).

Those potential predictors that are easy to determine early within a few minutes after arrival in ED such as physiological (SBP 1st, SBP worst, MAP), and resuscitation parameters (transfusion needed in ED (yes/no)) and acid/base status (pH 1st, pH worst, BD 1st, BD worst and dBD) were further focused. For continuous variables Receiver-

operator characteristics (ROC) curves were determined. BD worst had the most favourable ROC curve pattern: the area under the curve was 0.77. (Figure 5)

Figure 5 ROC curve of BD worst

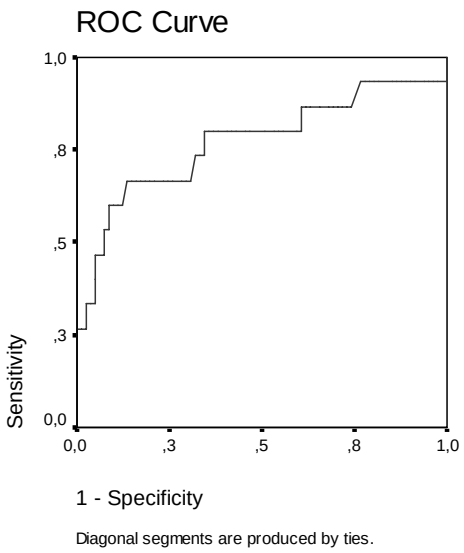

Cut off value was determined by expert opinion. At BD=6mmol/L there was sensitivity=0.73 and 1-specificity=0.33. (Table 3)

Table 3 Sensitivity and 1-specificity values of BD worst

BD worst	***Sensitivity***	***1-specificity***
3.15	0.80	0.60
4.15	0.80	0.50
5.15	0.80	0.38
6.05	0.73	0.33
7.00	0.66	0.26
8.05	0.66	0.19
9.25	0.66	0.15
10.10	0.66	0.12

Patients with BD>=6mmol/L had significantly larger proportion of arterial bleeders than those with BD<6mmol/L as demonstrated on the Chi² test. (Table 4)

Table 4 Chi² test on the determined BD cut off value

	PFRAB N (%)	**Non-PFRAB** N /(%)
BD <6mmol/L	3 (20)	55 (69)
BD ≥6mmol/l	12 (80)	27 (31)

Chi-Square test: p= 0.000

Decision tree analysis showed worst SBP to be the only useful predictor with cut-off value at 104mmHg. (Table 5) For other predictors no such value could be determined with this test.

TABLE 5 Decision tree analysis for SBP worst

	PFRAB N (%)	**Non-PFRAB** N (%)
SBP<=104mmHg	14 (93.3)	55 (43)
SBP> 104mmHg	1 (6.6)	73 (57)

Discussion

Previous studies reported on the role of pelvic angiography and embolization in the management of PFRAB [1, 19, 55, 56, 57, 58, 59, 77]. The incidence of PFRAB varies with the patient group assessed and with the timing when angiography was performed in wide range of 10-92% [3, 19, 20, 21, 56, 59]. We have found the presence of PFRAB was 10% of all HE-PRI patients.

There are two fundamentally different approaches to the use of angiography in the management of pelvic fractures. Proponents of early use [8, 17, 18, 20, 23, 24, 25, 26, 55, 57, 58, 78], including us, advocate it immediately after non-invasive pelvis fixation and exclusion of extra-pelvic bleeding. Only associated major intra-abdominal or intrathoracic bleeding has higher priority. The aim is to interrupt the pathologic cascade of shock, acidosis and coagulopathy with early haemorrhage control. Acute management continues with acute invasive (temporary or definitive) pelvic fixation if required (see study 3). Other, mostly European authors [49, 50, 51, 52, 59, 79] recommend immediate pelvic ring reduction and fixation with an external fixator or a pelvic clamp and extra-peritoneal pelvic packing performed in the operating theatre. They reserve angiography for those who remain haemodynamically unstable after these procedures. In both approaches there is much emphasis on organized team work, avoidance of delays and implementation of institutional guidelines based on local resources and expertise. Interpretation of results of different studies warrants attention to details on the management algorhytm, including the timing of angiography. There is only one paper so far to compare outcomes of these two different management protocols [79] by data from two different periods of management protocols of the same institution. This non-

randomized retrospective study shows comparable results in efficacy with favour to pelvic packing in terms of reduced need for angiography and transfusion and less mortality related to pelvic haemorrhage. The fact that not only the management options but other resuscitation parameters have changed between the two periods of the study makes interpretation of results difficult.

There are only a few studies in the literature with prospective design on the role of angiography in the management of PFRAB [2, 54, 71, 75]. Studies of retrospective design may have limitations due to lack of strict indications for angiography and potential for selection bias. There are numerous (20) previous studies in the literature reporting on predictors of PFRAB [2, 3, 53, 54, 61, 62, 63, 64, 65, 66, 67, 68, 69, 70, 71, 72, 73, 74, 75, 76]. Some predictors are identified but most of them have limited clinical value due to poor/no availability in the early phase of the management.

We believe that, the decision for angiography should be made early in the ED, before severe shock, acidosis and coagulopathy develops. We identified those predictors that are easily available early, shortly after arrival of the patient to the ED. We have focused on physiologic parameters and acid/base status determinants. We found that the presence of significant acidosis with BD<6mmol/L, worsening of the acidosis with dBD>2mmol/L, systolic blood pressure of 104mmHg or less and the need for transfusion in ED at any time within 4 hours of arrival can predict PFRAB. Using BD<6mmol/L as a single criterion to triage patients for angiography, would pick up 73% of PFRAB, accepting certain rate of non-therapeutic angiograms. Our data clearly demonstrates that the more severe the acidosis was, the more likely the angiography was positive for PFRAB. Sensitivity can be increased using dBD>2mmol/L as an adjunct, especially for those patients who have alkalosis on arrival. Base deficit was assessed in only one previous study by Starr et al [2] and was not linked with the use of angiography in their series.

We have found systolic blood pressure of 104mmHg or less at any time during the first 4 hours after arrival of the patient can predict PFRAB. A previous study by Salim et al. [71] suggested that persistent hypotension with of SBP<100mmHg predicts PFRAB.

The longer the hypotensive episode the more likely the patient is to have arterial bleeding.

We also have found the need for transfusion of PRBC in the ED predicts PFRAB (r=0.46). Triggers of blood transfusion during trauma resuscitation are not easy to define: based on physiologic parameters, initial response to resuscitation and estimated blood loss, blood products are administered [80] individually on the decision of the trauma team leader. We recommend using this predictor with caution due to these potential modifying factors.

Other physiologic variables such as the initial ED systolic blood pressure (SBP 1st), initial MAP, temperature and pH were found to be poor predictors. There was no previous study assessing resuscitation parameters as potential predictors.

Trauma scores, such as ISS>25 and AIS pelvis≥4 can predict PFRAB [3]. We also found correlation between those scores and PFRAB. Unfortunately these scores are not available early, and most clinicians do not use them in daily decision making. The Revised Trauma Score (RTS) was associated with the use of pelvis angiogram (no report on PFRAB however) in a study by Starr et al [2].

Several previous studies assessed and reported pelvic fracture patterns as potential predictors. Unstable fractures such as Young-Burgess APC II, III, LC II, III, VS and CM were associated with PFRAB [21, 53, 66, 76, 81]. Contrary, other studies did not find correlation between the fracture pattern and PFRAB [2, 56, 65, 72]. We found some correlation only of the AO/OTA system with PFRAB (r=0.34). Accurate fracture classification warrants a CT scan and is time consuming making it less valuable in an acute clinical setting. Some fractures are particularly difficult to classify even for experts, and the final decision on stability is made with dynamic testing under image intensification.

Others evaluated features on the initial AP pelvis radiographs taken in ED. Niwa et al [68] found the pelvic radiographs to be useful for predicting haemorrhagic sites, especially in those with anterior fractures. Fracture patterns associated with PFRAB are SIJ disruption with displacement [71], displaced obturator ring fractures and pubic symphysis diastasis [61]. These features are easily detected by the first care providers

who are not necessarily experts. The relevance of these radiographic features is limited due to the recent protocols of application of PB prior to any imaging.

Measurement of the size of the pelvic haematoma on CT scan is recommended by Blackmore et al [62] and size>500ml strongly suggests PFRAB. Generally, bleeding patients are poor candidates for CT scans, before their bleeding is controlled, and we did not use the CT pelvis angiogram as a screening tool to identify PFRAB. In our study only 9 out of 22 patients indicated for angiography had CT scans of their pelvises prior.

Contrast blush into a pelvic haematoma on the pelvis CT angiogram is accepted to be evidence of PFRAB [67, 74]. Pereira et al [69] determined the sensitivity, specificity and accuracy (90%, 98% and 98% respectively) of the CT pelvic angiogram to detect PFRAB. Two other studies gave warnings, that absence of contrast blush on the CT scan does not reliably exclude PFRAB [63, 64].

Increasing age was found to predict PFRAB in several studies with cut-off values between 55 and 65 years [2, 53, 54, 75]. This can be due to the older patients' sclerotic vessels poor ability to arrest bleeding with vasospasm or the increased chance of antithrombotic or platelet aggregation inhibitor medication. We found age to be a weak predictor (r=0.19). Female gender predicted PFRAB in a study by Salim et al [71]. We did not find it to have any prediction value.

Evaluation of lactate levels as predictor of PFRAB was planned, but due to missing data unfortunately we could not assess it. There are many trauma studies indicating that lactate and BD values have predicting values on outcomes and are frequently interchangeable in the description of the metabolic acidosis during shock [82, 83, 84].

We have not recognized any complications or adverse events associated with angiography/embolization. There are some cases reported in the literature with associated significant complications such as male sexual dysfunction [85] and ischaemic necrosis of gluteal muscles [86]. To prevent such complications embolization should be as selective as possible. In severe uncontrolled bleeding from multiple sites, selectivity is not achievable. Bilateral proximal internal iliac artery (IIA) occlusion might be considered. We had only one such case who had successful bilateral proximal embolization of IIA.

Despite procedure performed within 40 minutes after his arrival, followed by immediate pelvis and femur fracture stabilization with external fixators and laparotomy, this patient did not survive.

We acknowledge some limitations of the study. The small number of patients in the PFRAB group (N=15) is a limitation, making statistic analysis and interpretation of results more difficult. Running the study for longer period would not be feasible in a single centre environment since changes in resuscitation strategies would potentially influence the results. A multicentre study with pooling of data may cause paucity due to different treatment protocols and local logistics.

3. Acute definitive fixation of high-energy pelvic ring injuries

Background

Management of HE-PRI patients with multiple associated injuries is a major challenge. Timing of procedures for different injuries in different body regions requires careful planning when competing priorities are present. For unstable HE-PRI that requires surgical stabilization, the safe and standard approach is staged management: early fixation with external fixator or pelvic clamp or traction followed by definitive surgery with respect to the physiology parameters of the patient. [88, 89] Some pelvic fracture patterns are suitable for less invasive definitive fixation such as plate fixation of pubic symphysis disruption via a limited suprapubic incision and percutaneous screw fixation of the dislocated sacro-iliac joint (SIJ) or sacrum fracture. Performing these less invasive techniques acutely offers potential benefit for some severely injured patients including easier fracture reduction with less invasive surgery and earlier discharge or transfer to the rehabilitation facility. If staged approach is used, these patients may sustain longer delays in their pelvic fracture treatment due to their associated injuries. Our aim was to determine the feasibility of acute definitive pelvis fixation of selected HE-PRI patients. We assumed that acute definitive pelvic fixation of selected HE-PRI patients is safe and short term outcomes are comparable to staged management.

Patients and methods

Review of our prospective data base on HE-PRI was performed for 43 months period. For details of collected data please see methods of study 1. Consecutive HE-PRI patients with suitable fractures for less invasive internal fixation were included in this study. Patients requiring extensive surgery for fixation of unstable pelvises were excluded. Patients were categorized based on timing of pelvic fixation as acute, AC (<24h of presentation) or staged, ST (>24h after presentation). Decision for management and timing was made by the attending orthopaedic trauma surgeon based on fracture pattern and availability of the pelvic specialist surgeon: either acute definitive pelvic fixation (AC) or temporary external fixation followed by later definitive surgery (ST) was

performed. All patients had emergency non-invasive pelvic stabilization (PB) applied as per protocol. Temporary pelvic ring stabilization was achieved with application of external fixators, C-clamp or skeletal traction. All procedures of definitive pelvic stabilization were performed or supervised by the same surgeon (pelvic specialist). Procedures of definitive pelvic stabilization included percutaneous iliosacral screw fixation or symphyseal plating via limited suprapubic incision or both. (Radiograph 3A, B, Appendix)

Initial pelvic radiographs and CT scans and postoperative imaging were reviewed to measure displacements. Demographics (age, gender), procedures (type of surgical pelvic fixation), volume of transfusions and outcome measures (mortality, length of stay in hospital, length of ICU stay and rate of ICU admissions) were compared to assess safety and feasibility. Univariate analysis (chi^2 and t tests) was performed, $p<0.05$ was considered significant. Results are presented as mean ± SD or percentages.

Results

Forty five patients with HE-PRI met inclusion criteria: 18 patients in the AC (with timing of surgery 5.5±8 h from presentation) and 27 patients in the ST (5±3 days) group. AC and ST groups had comparable demographics with age 48±22 years vs. 40±13 and male gender 82% vs. 79% and injury severity with ISS 30±18 vs. 24.5±13 and AIS pelvis 3.7±1 vs. 3.4±1.1. Initial shock parameters were significantly worse for the AC group with systolic BP 69.7±17mmHg vs. 108±21, BD 7.14±mmol/L vs. 4.9±2, lactate 6.67±7mmol/L vs. 2.51±1.3. Angiography was performed in comparable rates in AC 18% vs. ST 21% groups. (Table 6)

Table 6 Demographics, injury and shock severity of groups

	AC (N=18)	**ST** (N=27)
Age (year)	48±22	40±14
Male (%)	82	79
ISS	30±18	24±13
AIS pelvis	3.7±1	3.4±1
SBP (mmHg)	69.7±17	108±21
BD (mEq/L)	7.4±4	4.9±2
Lactate (mmol/L)	6.67±7	2.51±1.3
Laparotomy (%)	12	8
Angiography (%)	18	21

The distribution of surgical procedures was comparable in both groups: symphysis plating alone (AC 28%, ST 30%), iliosacral scew fixation alone (AC 22%, ST 11%) and both procedures (AC 39%, ST 59%). Most of the procedures were carried out in normal working hours: four patients in the AC group (22%) were operated after hours, while all patients in the ST group had their surgery between 8am and 6pm.

None of the outcome measures showed statistically significant difference. All patients in the AC group survived and one patient died in the ST group due to severe head injury.

There was a trend for shorter hospital stay for AC patients (25±24 days vs. 37±32) and decreased need for PRBC transfusions in the first 24h (4.7±5U vs. 6.6±4). Fewer cases of pneumonia (0% v. 14%) and deep vein thrombosis (6% vs. 8%) were recognized in the AC group. AC patients had shorter stay on the intensive care unit (2.9±2.5 days vs. 3.7±3.6) with ICU admission rates comparable (AC 67% vs. ST 56%). (Table 7)

Table 7 Outcomes of groups

Outcomes	**AC** (N=18)	**ST** (N=27)
PRBC <24h (U)	4.7±5	6.6±4
Deep Vein Thrombosis	1 (6%)	2 (8%)
Pulmonary Embolism	0	0
Pneumonia	0	4 (15.4%)
ICU LOS (days)	2.9±2.5	3.7±3.6
LOS (days)	25±24	37±32
Mortality (%)	0	3

Initial displacement tended towards more severe in AC group: symphyseal area AC 24±19.2mm vs. ST 14±10.1, SIJ area AC 11.2±8.6mm vs. ST 6.1±4.9. The quality of

reduction demonstrated on postoperative imaging was comparable: pubis area AC 7.5±4.0mm, ST 5.4±4.1, SIJ area AC 3.1±1.7mm, ST 2±1.8. (Figure 6)

Figure 6 Fracture displacements of groups

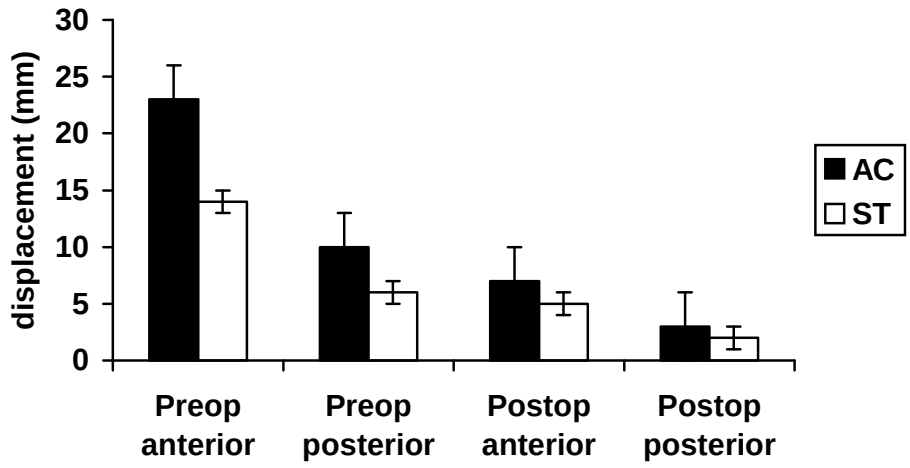

No septic complications occurred in the AC group. There were three superficial pin infections (11%) in the ST group and one deep infection (4%).

Discussion

Timing of operative fracture fixation of the multiply injured blunt trauma victim is a long debated issue. Severe pulmonary complications (acute respiratory distress syndrome, acute lung injury) and systematic complications (systematic immune response syndrome and multiple organ failure, fat embolization syndrome) after reamed intramedullary nailing of long bone fractures have been reported in the past. The incidence of these complications have reduced significantly with development of new management strategies and resusctitation protocols and better intensive care of polytrauma patients [90, 91]. Trauma patients were categorized based on their physiologic parameters by Pape et al [92, 92] as Stable, Borderline, Unstable and Extremis, and recommended management strategies are tailored. Early stabilization of long bone fractures in Stable patients with multiple injuries is generally preferred, even in presence of chest injuries, as it results in better short term outcomes, lower rate of

complications and reduced costs [94, 95, 96, 97, 98]. Borderline patients may benefit from a staged approach [90, 92, 93]. Some factors other than physiology, like estimated length of procedures and the amount of tissue damage caused by surgery are also important considerations. Generally, Unstable and Extremis patients are candidates for staged management [90, 92, 99]. The second stage of operations (definitive surgery) is performed after bleeding control is achieved and coagulation and inflammatory parameters are normalized [99, 100].

While timing of femur fracture stabilization was extensively researched, there is little evidence available on timing of pelvic fracture fixation in patients with multiple injuries [88, 89, 101]. There are many potential benefits of acute definitive pelvic stabilization including easier direct fracture reduction without extensive open surgery, less blood loss, better positioning and respiratory care on ICU, and shorter length of stay. Our results show that acute definitive fixation of selected HE-PRI can be performed safely and effectively, even in the multiply injured blunt trauma victim. We compared selected HE-PRI patients with those with similar fracture patterns based on timing of definitive pelvic fixation. AC and ST patients had comparable age, gender and injury severity. In most outcome measures there was a trend to favour acute definitive fixation, however no statistically significant difference was found. There was a trend for more severe fracture displacement before operation in the AC group, but the quality of fracture reduction was comparable between the groups.

If staged management is followed the aim is to perform definitive fixation in 48-72 hours. Frequently longer delays are experienced for various reasons. After shock resuscitation of the multiply injured blunt trauma victim generalized oedema is present making soft tissue conditions suboptimal even for minimally invasive surgery. Presence of intestinal gases results in poor visibility on intraoperative imaging. For percutaneous fixation techniques optimal intraoperative images are needed and definitive surgery is delayed until the bowel paralysis is resolved. Sometimes multiple associated injuries are present with competing priorities. For the above reasons acute definitive pelvic stabilization was preferred and performed in all our cases when physiology of the patient allowed and the fracture pattern was suitable for less invasive technique and the pelvic

surgeon was available. In all other cases definitive surgery was delayed. Main determinant of management was availability of the pelvic specialist surgeon. In the absence of the subspecialty surgeon staged surgery is a safe alternative. Switching to damage control mode during the acute management may be needed at any time based on the physiologic condition of the patient, even if acute definitive surgery was aimed originally.

The unexpected finding of AC patients required less PRBC transfusions in the first 24 hours may be the result of the minimally invasive nature, anatomic reduction and superior stability of acute definitive surgery compared to temporary fixation methods such as external fixation and C-clamp. These first stage stabilization methods improve alignment of the pelvis but do not result in the same stability and accurate reduction.

Given the very promising results and proved safety of our acute approach, investigating this further to find potential outcome benefit in a longer cohort study is considered.

Limitations of the study are the retrospective nature of analysis and the lack of randomization of patients into management arms.

4. Rectum injuries in association with pelvic ring disruptions

Background

High-energy pelvic ring injuries (HE-PRI) are part of multisystem blunt trauma, and are commonly associated with significant injuries of intra-pelvic organs and distant body regions. Associated injuries are responsible for significant mortality and morbidity and often for suboptimal outcomes. Common associated injuries include severe head injuries, chest, abdominal organ injuries, long bone fractures and genitourinary injuries [1, 3, 4, 6, 27]. The association with rectum injuries is well described; however there is limited data available on the incidence of this association. In previous studies it was reported 0.15-2.2% [102, 103]. They are described as (1) the rectum injury is a result of a perineal laceration extending to the rectum [29, 30, 104] or (2) a bone fragment directly pierces the rectum [28, 29, 31]. This condition is equivalent to an open pelvic ring injury. If the rectum tear is not associated with any perineal laceration (open only into the rectum) the injury may be more difficult to detect. During the secondary survey of the trauma victim per rectum digital examination is routinely performed as recommended by the ATLS [16] (REF) and integrity of the rectum wall is palpated in all cases of pelvic fractures. Blood detected in the rectum warrants further examination even in the case of no palpable injury. Many multisystem blunt trauma victims have CT scans performed of their head, spine, chest, abdomen and pelvis with intravenous contrast as part of their emergency workup. Even with advanced imaging it is possible to miss a rectum injury. Consequences of a late diagnosis might be very severe including generalized sepsis from pelvic origin, potentially leading to death [30, 31, 32]. The purpose of this study was (1) to determine the incidence of rectum injuries associated with high-energy pelvic ring disruptions and (2) describe the patterns of this combined injury. We assumed that rectum injuries occur with lateral compression or combined injury mechanisms as a result of direct bone penetration into the rectum or a perineal laceration extends to the rectum.

Patients and methods

All patients with HE-PRI admitted to a single level 1 trauma centre were entered in a data base in a prospective fashion from March 2005. For details of data collection please see methods of study 1. Retrospective analysis of the data was performed for the period of 48 months (March 2005-March 2009). All patients with HE-PRI were included. Patients with acetabulum fractures not involving the pelvic ring were not considered. Radiographs were reviewed including emergency department antero-posterior pelvis views, CT scans, intraoperative and postoperative images. Patients' medical charts were reviewed for ED notes and for operation reports. Autopsy reports were also reviewed for those who deceased in the hospital or arrived in the ED with no signs of life.

Patients identified with associated rectum injuries were further assessed for details of the injury mechanism, and details of the pelvic and rectum injury, management and outcomes.

Results

In the time period of 48 months of the study there were 194 patients presented with HE-PRI. Rectum tear was associated in 4 cases (incidence 2%). Patient demographics were age: 60, 56, 63, and 48 years, all male. Patients with associated rectum tear were more severely injured with ISS mean 55, range 33-66, versus ISS 25, range 4-66 than those without rectum tear. Patients with rectum injuries all had significant blood loss, which required transfusions in the first 24h; mean 11U, range 4-27U. Their hospital stay was longer mean 122 days, range 22-213 days versus 23 days (3-92), than of those without rectum injury. All patients had severe associated injuries, including facial fractures (1 case), intracranial haemorrhages (1 case), multiple rib fractures with haemopneumothorax (2 cases), prostathic urethra rupture (2 cases), extra-peritoneal bladder rupture (1 case) and severe extremity injuries (3 cases). All required multiple surgical procedures for the management of the pelvic, rectum and associated injuries. The overall mortality of the cohort was 7.8%. All patients with associated rectum injury survived.

The pelvic ring disruption was classified as AO/OTA 61B1 and Young-Burgess APC II in 3 cases and 61B3 / APC III in one case. All patients had disruption of the pubic symphysis with widening greater than 2.5cm on the emergency department AP pelvis radiographs. The injury mechanisms were the following: horse riding accident with hitting the pelvis on the saddle, motorbike accident with hitting the pelvis on the fuel tank (2 cases) and bicycle rider hit by a car.

One patient had a large perineal laceraton involving the anus and the anterior wall of the rectum and extending to the scrotum, which was obvious on physical examination. In the other three cases the diagnosis of the rectum injury was made by per rectum physical examination with the finding of blood in the rectum and palpation of the defect. Diagnosis was further clarified by CT scan with contrast enema in one case. Diagnosis was made in a timely fashion in the Emergency Department in three cases and was delayed until day 7 post injury in one case. For those who had no perineal laceration, the rectum injuries were located on the anterior wall of the rectum 3-5 cm distance from the anus and were 2-4 cm in size.

The pelvic ring disruption had emergency non-invasive stabilization (PB) with a sheet wrapped around as in all cases. Two patients had associated pelvic arterial bleeding detected on pelvic angiography and successfully managed by embolization. Acute pelvic ring fixation within 24h was performed by open reduction and internal fixation of the pubic symphysis with a plate in two cases and an external fixator was applied in the other two cases. Both patients with external fixators had it on as definitive fixation.

The rectum injury was managed with diverting colostomies in all cases. Laparoscopic procedure was performed in two cases and open procedure in the other two cases. The colostomy was performed within a few hours of the diagnosis in three cases, and as a planned procedure on day 4 post injury in one case. Distal rectal washout (DRWO) was performed in one case and presacral drainage (PSD) was used in another one. The rectum injury was directly repaired in one case. The large perineal laceration was managed in stages with debridement in the fist stage followed by sphincter repair and step by step closure of the laceration.

Complications occurred in two cases. One patient developed a bleeding duodenal ulcer requiring multiple transfusions, subtotal and later a total gastric resection. Another patient, in whom the rectum injury was diagnosed late, developed generalized sepsis from pelvic origin, which resolved with treatment.

Regarding long term outcomes only one patient could return to his preinjury activities (competitive bicycle riding) with permanent suprapubic catheter and definitive colostomy. Only one patient had his colostomy reversed after 26 months. One patient had permanent disability due to severe brain damage requiring 24h nursing care. One patient had below knee amputation for his mangled lower extremity. One patient was not available for long term follow up.

Discussion

Rectum injuries are result of penetrating trauma in >90% of the cases [29]. Open fractures of the pelvis are associated with anorectal trauma in 17-64% [105, 106, 107, 108] according to a review by Grotz et al [109]. In our study the incidence of rectum injuries associated with high-energy pelvic ring disruptions was 2%. We also described the characteristics of this injury pattern. (Table 8)

Table 8 Injury pattern

Case No	**Mechanism of injury**	**AO/OTA type**	**Pelvic ring injury description**	**Localization of rectum tear**
1.	Horse rider hit pelvis on saddle	61 B1.1	Pubis symphysis rupture with widening and unilateral SIJ partial rupture	Anterior wall
2.	Motorbike rider hit pelvis on fuel tank	61 B1.1	Pubis symphysis rupture with widening and unilateral SIJ partial rupture	Anterior wall
3.	Bicycle rider hit by car	61 B1.1	Pubis symphysis rupture with widening and unilateral SIJ partial rupture	Anterior wall
4.	Motorbike rider hit pelvis on fuel tank	61 B3	Pubis symphysis rupture with widening and bilateral SIJ partial rupture	Large perineal tear involving anus and anterior wall

All our cases had similar injury mechanisms with having something between the lower limbs at the time of the accident (motorbike, horse or bicycle) acting as a wedge and opening the pelvis from the front. Separation of the pubic symphysis was always the result in various degrees. With increase of the force applied, the pubis widening was larger and the posterior pelvic ring injury was either unilateral or bilateral. Aihara et al [102] have found in their study the widened pubic symphysis being an independent predictor of rectum injury.

In our cases the rectum injury could not be the result of a bone fragment piercing through, as all these injuries were pure ligamentous disruptions of the pelvic ring with no any bone fragments nearby. (Radiographs 4 A, B, C, D, Appendix) Penetration of any object could be also excluded as a possible mechanism in all cases. The same injury pattern was previously described by Berman et al in 1974 [32]. Their paper explains a theory about the anatomic situation of the pelvic floor, making the rectum vulnerable to avulsion injury, if the pubic symphysis widely separates. The location of the injury on the rectum is at the attachment of the levator ani muscle to the rectal wall with a firm aponeurotic band just at the vesicorectal wall. This theory is supported by our observations.

If there is no perineal laceration and the pelvis fracture is only open to the rectum, it might be easily missed. In all our cases the rectum injury was either visible or located in a short distance from the anus making it possible to palpate. Performing PR examination in ED is routine for patients with pelvic fractures, but it has some limitations. It might be performed by an inexperienced person, or it might be attenuated by the noisy environment or by a pelvic binder applied. Therefore we recommend repeating the examination later in a more controlled environment by an experienced person. The best option might be in the operating room or on the intensive care unit, after bleeding control is achieved and patient is stabilized. For high risk patients, even in case of a negative finding, other diagnostic options like contrast enema or rectoscopy/sigmoidoscopy might be also considered. A recent review on open pelvic fractures by Grotz et al [109] resulted in similar recommendations regarding diagnosis of anorectal injuries associated. Some authors questioned the use of routine performance of

PR examination in the secondary survey of the trauma victim in both adults [110, 111] and children [112] resulting in the recent change of the ATLS guidelines [16]. However nobody questions its value and indication in case of pelvic fractures. Other options, such as Guaiac testing, was also evaluated in a study by Levine et al [113] and was found to be insufficient to confirm or exclude an occult rectal injury if used alone. The risk of a missed injury outweighs the risks associated with the additional diagnostic procedures mentioned before.

There is no consensus in the literature regarding the management of rectum injuries. The evidence available is coming from retrospective studies with limited patients involved, and without control groups making the level of evidence low [114]. Most studies assessed penetrating trauma victims [115, 116, 117] as these injuries are much more frequent then blunt ones to the rectum. Diverting colostomy is still the standard of care for all blunt trauma victims [28, 109, 118, 119, 120]. Different management strategy of some penetrating trauma victims were reported by Gonzalez et al [115], who managed selected, extra peritoneal, non-destructive, penetrating rectum injuries without colostomy safely without complications. Technical details of the colostomy should be discussed between surgical and orthopaedic teams to save options for optimal fracture management. Other adjuncts like distal rectal washout (DRWO), presacral drainage (PDS) and direct repair of the rectum injury are a matter of debate. Our experience is not enough to make suggestions about these issues. In our institute the choice of treatment was based on the attending trauma or general surgeon’s preference.

Timing of the colostomy is an important issue. It should be performed as soon as bleeding control is achieved and the patient is in a stable condition [109]. Delays in treatment increase the risks of developing complications [121]. All our colostomies were performed with the aim for temporary diversion, but takeoff was performed in only one of our patients. This demonstrates that at the time of the procedure it is never known that will the colostomy be temporary or permanent for the patient.

All our patients survived, however the perineal/genitourinary trauma and also the associated severe distant injuries significantly influenced long term outcomes and quality of life.

5. Unilateral dislocation of the sacroiliac joint with intact anterior pelvic ring

Background

With high-energy mechanism injuries the ring structure of the pelvis usually brakes at two distinct parts [122, 123]. The weaker anterior part (pubic symphysis and pubic rami) is more prone to injuries, especially in cases of high-energy transfer. Isolated anterior part fractures (pubis and pubic rami) are common in low-energy trauma. On the sideways of studying patients with high-energy pelvic fractures, two cases of unilateral SIJ disruptions, with intact anterior pelvic ring, were identified. Conventional classification systems (Tile [37], AO/OTA [38], Young-Burgess [39]) are poorly applicable to these injuries. After detecting the second case we hypothesized that these injuries are rare, but there are more cases possibly.

Patients and methods

We reviewed our prospective data base on pelvic fractures. For details on data collection see methods of study 1. Conventional radiographs and CT scans were reviewed for all patients, regardless the fracture type. Cases identified were thoroughly assessed for injury mechanisms, associated injuries, management and outcomes with the aim of finding similarities to describe this rare injury pattern.

A comprehensive literature review was performed using MedLine database and PubMed search engine (since 1950), using keywords of `unstable pelvis`, `sacroiliac joint disruption/dislocation` and `intact anterior pelvic ring` to find similar cases. Studies on human subjects were searched in English.

Results

There were only two cases of isolated unilateral SIJ disruptions with intact anterior pelvic ring in our prospective data base. They were both classified as AO/OTA 61C1 and Young-Burgess CM. Our detected two cases were similar regarding patient demographics (both male age 18), high-energy injury mechanisms (passenger in a high

speed car crash, and motorbike rider), associated severe soft tissue injuries (both had extensive closed deglovig injuries, Morel-Lavallee lesions) and required surgical repair. In both cases the pelvic ring was reduced with closed manipulation and was fixed with percutaneous insertion of cannulated screws through the SIJ into the body of S1 and S2 (case 1) and into S1 (case 2) vertebrae in supine position of the patient. In both cases stability of the anterior ring was tested before and after posterior fixation and was confirmed stable. Definitive pelvic fixation was performed on day 3 (case 1) and on day 10 (case 2) after the accident. The longer delay in case 2 was due to the severe soft tissue damage in the gluteal region. Both patients had their Morel-Lavelee lesions surgically managed together with the pelvis stabilization, including drainage through separate lateral incisions and washout following recommendations of Tseng et al [124]. Both patients had excellent outcomes with complete return to their pre-injury activities 12 months after the accident.

Our comprehensive literature search identified one more case of unilateral SIJ disruption with intact anterior pelvic ring [125], which was published 2 years after our case. In this case the SIJ dislocation was anterior and superior. The victim was a young male injured in high speed automobile crash and was ejected from the vehicle. He had severe associated injuries including subdural haematoma and brain oedema resulting in long term vegetative state. We have found bilateral SIJ pure dislocations (2 cases) [126, 127] and bilateral fracture dislocations (4 cases) [128, 129, 130, 131] with intact anterior pelvic ring.

Discussion

High-energy pelvic ring injuries are likely to involve both the weaker anterior (pubis and pubic rami) and the stronger posterior part (iliac wings, SIJ and sacrum) of the pelvis [122, 123]. In case of posterior lesions, associated anterior injuries are the rule. Bilateral posterior lesions reflect even greater amount of energy transfer. Isolated unilateral SIJ disruptions with the anterior pelvic ring intact are extremely rare with only three cases reported so far.

Bilateral SIJ disruptions (either pure dislocations or fracture dislocations) are also rare with only a few cases reported. These cases were similar in the mechanism of injury being a severe direct hit to the sacral area from behind (possibly with some variations in the direction of the force) or an upwardly directed force applied on the ischial tuberosities. Associated soft tissue injuries of the lower back and gluteal area were reported [127]. Our cases reiterate this injury mechanism with a unique previously not described pelvic dislocation. This injury affects young age group, as in our cases, and those reported in the literature with bilateral SIJ injuries.

Detection of these injuries might be difficult on conventional radiographs. High index of suspicion is needed in young patients with initially unremarkable pelvis radiographs (Radiographs 5A, B, Appendix) especially when the thorough physical examination detects soft tissue injuries in the area [132]. Additional inlet/outlet views and a CT scan are essential to visualize the damaged skeleton. In retrospect the initial pelvic radiographs of our cases showed distinct features of trauma but were underreported.

For optimal outcome the dislocation should be reduced and stabilized. We prefer closed reduction with aid of manual traction and manipulation with Schantz pins inserted into the iliac crest and percutaneous fixation with cannulated screws. Less invasive technique is required with respect to the damaged soft tissues around. Loss of skin integrity and extensive soft tissue damage can influence timing and method of bony fixation. Minimally invasive drainage of the Morel-Lavallee lesion is possible to perform through separate small incisions in a safe and efficient way as recommended by Tseng et al [124]. Using separate incisions for bone fixation and for the closed degloving injury is preferred, but may not be always possible. In those cases alternative techniques such as plate fixation of the SIJ through anterior approach may be considered. Other alternatives are transiliac-sacral-iliac bar fixation [133], that is particularly useful in bilateral dislocations and posterior plate fixation. These techniques require prone positioning of the patient and optimal soft tissue conditions at the back.

Summary of conclusions and possible future directions

1. Emergency non-invasive pelvic ring fixation is safe and effective, even in hands of the first care provider. The adherence to the guidelines should be improved with further education. Fracture alignment could be improved in all B1 and most C type fractures. Although in some fracture patterns (B2 and B3) the deformity had increased, there was no evidence found of any significant hazards associated with the use of PB.
2. Physiologic parameters such as BD>6mmol/L, increase of BD>2mmol/L between two measures, SBP<104mmHg and the need for transfusion in ED can all predict PFRAB in ED. After exclusion of abdominal, chest, extremity and external bleeding, these predictors can be valuable to triage blunt trauma victims for pelvic haemorrhage control with angiography.
3. Acute definitive pelvic ring stabilization in selected HE-PRI can be performed safely and effectively even in the multiply injured blunt trauma victim.
4. Rectum injuries associated with pelvic fractures are present in 2% of all HE-PRI. They are result of AP directed force on the pelvis. Rectum injuries are possible to detect by physical examination as they are either visible or palpable on the anterior wall in 2-4cm distance from the anus. The conventional teaching about rectum injuries associated with pelvic ring disruptions should be revised with the addition of this injury pattern as a separate entity.
5. Unilateral SIJ disruptions with intact anterior pelvic ring are unique injuries after high energy impact. They are associated with severe soft tissue damage. Posterior ring fractures/dislocations can occur in young patients without anterior ring fractures or dislocations.
6. The future of early management of HE pelvic injuries might be development of operating rooms in the trauma centres, equipped with options to perform all possible interventions at one place, including advanced imaging, bone fixation, pelvic packing and angiography/embolization if needed. In this setting delays and decision making errors can be minimised.

Összegzés magyarul

Nagy-energiájú medencegyűrű sérülések akut ellátása

Bevezetés

A nagy-energiájú medencegyűrű sérülések (HE-PRI) jelentős halálozással és morbiditással járnak. A legjobban felkészült trauma centrumoknak is komoly kihívást jelent az ellátásuk. A John Hunter Kórház kiemelt sérültellátó központ Ausztrália Új Dél-Wales államában, mely felelős 1.100.000 fő baleseti ellátásáért 130.000 km² területen. Az állam legforgalmasabb sérültellátó kórháza évente 4500 sérültet lát el, akik közül több mint 400-an súlyos sérültek (ISS> 15). Minden nagy-energiájú medencegyűrű sérülést itt látnak el: a sérült vagy közvetlenül a baleset helyszínéről érkezik, vagy valamelyik referáló kórház közbeiktatásával. Egy korábbi prospektív vizsgálat ebből az intézetből részletesen leírta a medencegyűrű sérülések epidemiológiáját, és azonosította azokat a területeket, ahol az ellátás javítása kívánatos. A klinikai vizsgálatok tervezésekor a következő célokat tűztük ki:

1. Meghatározzuk a sürgős non-invazív medencegyűrű stabilizálás (PB) hatékonyságát és biztonságát.
2. Meghatározzuk a medencegyűrű sérüléssel társuló artériás vérzés (PFRAB) korai előrejelzésének klinikailag legalkalmasabb eszközeit.
3. Pontosítsuk az akut, definitív medencegyűrű stabilizálás szerepét.
4. Megismerjük a rectum sérüléssel társuló medencegyűrű sérülések jellegzetességeit.

A fenti célok elérésére négy klinikai tanulmányt végeztünk, melyeket itt összegzünk. A vizsgálatok során észleltünk és leírtunk olyan sérülés típust, melyet korábban nem ismertettek.

1. A sürgős non-invazív medencegyűrű stabilizálás hatékonysága és biztonsága

Bevezetés: A non-invazív sürgősségi medencestabilizálás része az intézeti protokollnak. Számos vizsgálat igazolta a non-invazív módszerek előnyeit, de kevés adatunk van a módszer hatékonyságáról és biztonságos kivitelezhetőségéről.

Beteganyag és módszerek: Prospektív adatgyűjtést indítottunk 2005 márciusában. Az elektronikus adatbázisban az összes beérkezett HE-PRI beteg adatait feljegyeztük úgy, mint: demográfiai adatok (életkor, nem), sérülési mechanizmusok, töréstípusok (AO/OTA és Young-Burgess beosztás szerint), fiziológiai mutatók (vérnyomás, pulzus, hőmérséklet, pH, base deficit, lactat), ellátás (medence stabilizálás, angiopgráfia/embolizáció, egyéb műtétek), társsérülések, kimeneti mutatók (halálozás, kórházi és intenzív osztályos tartózkodás). A vizsgálat során az első 4 év eseteit értékeltük. Az ellátási protokoll azonnali nem-invazív stabilizálást javasol minden shock jeleit mutató medence sérültnél, függetlenül a törés típusától. A rögzítéshez lepedőt vagy speciálisan erre a célra kifejlesztett orthesist használtunk. Minden rögzítőt 24 órán belül

eltávolítottunk vagy meglazítottunk. A vizsgálatban adatbázisunk első 41 hónapjának összes betegét értékeltük. A stabil medencesérüléseket (AO 61A típusok) és az izolált acetabulum töréseket kizártuk. Vizsgáltuk a protokoll betartását intézetünkben. A rögzítés hatékonyságát a PB felhelyezése előtti és utáni röntgen és CT felvételek összehasonlításával elemeztük. Kategóriák: Tökéletes, Jobb, Nem változott, Rosszabb. Minden esetet, amikor nagyér, ideg, rectum sérülés vagy egyéb szövődmény jelentkezett egyedileg megvizsgáltunk és vizsgáltuk az esetleges összefüggést a PB alkalmazásával.
Eredmények: 115 instabil HE-PRI beteg (AO/OTA B és C típusok) közül 43 (47%) esetében történt PB. A töréstípusokat illetően az arány B1 81%, B2 14%, B3 42%, C1 53%, C2 75%, C3 33%. Vérzéses shockot 36 (31%) betegnél észleltünk, ezek felénél alkalmaztunk PB-t, így a protokollt a betegek 50%-ában tartottuk be ezen időszakban. Töréstípusokra lebontva a protokoll betartása: B1 81%, C összes 68% volt. A B2 és B3 típusoknál gyenge volt a protokoll betartása (20%). A hatékonyság: Tökéletes 42%, Jobb 26%, Nem változott 21%, Rosszabb 11%. Az összes B1 és legtöbb C típus (82%) Tökéletes vagy Jobb eredményt adott. A deformitás fokozódását 5 esetben észleltük (B2 és B3 típusok). A halálozás 7,8% volt. Négy beteg esetében a halálok medencei vérzés volt, ezek közül kettő esetében PB történt az ellátás során a megfelelő időben. Két betegnél a PB késedelemmel történt vagy egyáltalán nem. Arteria femoralis superficialis sérülést egy esetben észleltünk angiográfián, mely végtagi ischaemiát nem okozott. A műtéti ellátásnál áthatoló sérülés kizárható volt. Három esetben rectum sérülés társult. Mindegyik B1 típusú sérülés volt, symphysis szakadással, csontsérülés nélkül, így az okok közül a PB mindegyik esetben kizárható volt. A tíz hólyagsérült közül 4 esetben történt PB. Ezek közül három esetben valamilyen éles fragmentum volt a közelben, ami a szervsérülést okozhatta. Ezeknél a PB oki szerepe nem volt valószínű, de nem volt egyértelműen kizárható. Sem neurológiai tüneteket okozó ideggyök compressiot, sem bőrelhalást vagy fekély kialakulását nem észleltük.

2. A medencegyűrű sérüléssel társuló artériás vérzés (PFRAB) predikciója

Bevezetés: Minden erőfeszítés ellenére a HE-PRI sérültek között a korai szakaszban a legjelentősebb halálok a medencei vérzés. A medencei vérzéscsillapítás különféle módszerek kombinációjával érhető el. A medencei vérzésforrás lehet a törött csont, a kismedencei vénás plexus vagy valamely megnevezett ér, érág. A társuló artériás vérzés (PFRAB) különös figyelmet érdemel. A nagy nyomású artériás rendszer vérzése nem csillapodik magától, mint a kis nyomású vénás vérzések egy része. Angiográfiát a PFRAB észlelésére és kezelésére széles körben alkalmaznak. Általános az egyetértés, hogy a jelenleg elérhető módszerek közül ez a legalkalmasabb az artériás vérzés csillapítására, de az érfestés időzítése és elhelyezése az ellátási algoritmusokban nem egységes. Szükséges azon betegek korai azonosítása, akik legjobb eséllyel kaphatnak terápiás beavatkozást.
Beteganyag és módszerek: az ellátási protokoll szerint az azonnali non-invazív medencestabilizálást a nem medencei eredetű vérzések azonosítása és ellátása követi. A külvilág felé észlelt vérzést kötéssel, varratokkal azonnal csillapítjuk. A hosszú csöves csontok töréseit sínezzük. Ha nincs testüregi vérzésre utaló jel (AP mellkas felvételen, FAST vizsgálaton vagy DPA/DPL során) a vérzés jeleit mutató beteget angiográfiára

visszük, a team vezető döntése alapján, ahol az észlelt PFRAB ellátása történik. Az adatgyűjtés 4 évig zajlott, prospektív módon a korábban leírtak szerint történt. Kizártuk a vizsgálatból a 18 évnél fiatalabbakat, akik a balesettől számított 4 óránál később érkeztek, és akiknél nem voltak vitális funkciók beérkezéskor. A potenciális prediktorokat standard statisztikai próbákkal vizsgáltuk (egyváltozós analízis, ROC görbe és döntésfa analízis, Pearson korreláció). Különös tekintettel vizsgáltuk azon fiziológiai paramétereket, melyek könnyen és azonnal elérhetők a sürgősségi ellátás során.
Eredmények: 143 HE-PRI beteg közül 15 (10%) esetben észleltünk PFRAB-t: angiográfiával 11, CT angiogramon 1, laparotómia során 3 esetben. Semmilyen szövődményt nem észleltünk az angiográfiával/embolizációval kapcsolatosan. PFRAB betegek jelentősen idősebbek, súlyosabban sérültek (ISS és AIS pelvis), alacsonyabb vérnyomásúak, acidotikusabbak (pH, BD) voltak. Gyakrabban igényeltek transzfúziót az első 4 órában, és többet az első 24 órában. A halálozásuk is magasabb volt. Pearson korreláció (r> 0,3) predikciós potenciált jelzett a következő változóknál: sürgős transzfúzió igénye, ISS, AIS pelvis, AO/OTA besorolás, pozitív FAST, legrosszabb SBP, Ph és BD, dBD értékek. ROC görbék elemzése a legrosszabb BD esetében mutatott kedvező képet. A görbe alatti terület 0,77 volt. Cut off értéket BD=6mmol/L-nél alkalmazva szenzitivitása=0,73, 1-specificitása=0,33 Chi^2 próbával a betegek jelentősen nagyobb része esetében észleltünk PFRAB-t BD>=6 mmol/L értékkel, mint ezen érték alatt. A döntésfa analízis a legrosszabb SBP-t adta egyedüli hasznos prediktornak, 104 Hgmm cut off értékkel.

3. Az akut medencegyűrű stabilizálás szerepe
Bevezetés: Az instabil HE-PRI sérültek ellátásának standard és mindig biztonságosan kivihető módszere a kétszakaszos műtét: elsődleges stabilizálás után definitív műtét. Bizonyos töréstípusok lehetővé teszik kevéssé invazív technikák alkalmazását, mint percután ilio-sacralis csavarozás, symphysis lemezelés kis feltárásból. A technikák korai alkalmazása sok szempontból előnyös lehet. Feltételeztük, hogy bizonyos HE-PRI sérülések akut definitív stabilizálása biztonságos és a korai eredmények összehasonlíthatóak a szakaszos ellátáséval.
Beteganyag és módszerek: Prospetív adatbázisunk 43 hónapját tekintettük át. Az összes HE-PRI beteget vizsgáltuk, akik medence sérülése lehetővé tett kevéssé invazív stabilizálást. A betegeket két csoportba osztottuk: akut definitív (AC) és szakaszos (ST). A kezelésről mindig az ügyeletes traumatológus/ortopéd döntött: ha a medence specialista azonnal elérhető volt akut definitív ellátás történt, más esetben szakaszos. A törések elmozdulásait preoperatíve és postoperatív CT felvételeken mértük. Az eredményeket standard statisztikai próbákkal vizsgáltuk.
Eredmények: A vizsgálat feltételeinek megfelelő 45 HE-PRI beteg közül 18 AC (definitív ellátás 5,8±8h), 27 ST (5±3 nap) csoportba került. A két csoport demográfiai mutatói és a sérülések súlyossága összemérhető volt. A shock paraméterei (SBP, BD, lactate) az AC csoportban rosszabbak voltak. A sebészi beavatkozások eloszlása összemérhető volt: symphysis lemezelés önmagában (AC 28%, ST 30%), SI csavarozás önmagában (AC 22%, ST 11%), a kettő együtt (AC 39%, ST 59%). A kimeneti mutatók közül egyik sem adott statisztikailag jelentős különbséget, de az AC csoportra kedvező tendenciát

észleltünk rövidebb kórházi tartózkodásra (25±24 nap vs. 37±32) és csökkent transzfúzió igényre az első 24 órában (4,7±5 U PRBC vs. 6,6±4) és kevesebb pneumóniát (0 vs. 14%) és mélyvénás thrombosist észleltünk (6% vs. 8%). Az AC betegek rövidebb ideig tartózkodtak az intenzív osztályon (2,9±2,5 nap vs. 3,7±3,6) hasonló felvételi arányok mellett (AC 65%, ST 56%). A törések kezdeti elmozdulása tendenciózusan nagyobb volt az AC csoportban a műtét előtt, míg a műtét után a reziduális elmozdulás hasonlatos volt.

4. Medencegyűrű sérüléssel társuló rectum sérülések jellegzetességei

Bevezetés: A HE-PRI sérülések szinte mindig más testtájak sérüléseivel társulnak, amelyek miatt a betegek életveszélyben lehetnek, vagy a kialakuló szövődmények miatt, illetve a felépülésüket késleltetik, életminőségüket ronthatják. A rectum sérülések társulása medencesérülésekkel ismert: az irodalmi adatok szerint ilyenkor (1) a gáttáji sérülés a rectumra terjed vagy (2) közvetlenül egy csontdarab penetrálása okozza. Ha a rectum sérülés a külvilág felé nem látható, a felismerés problémás lehet. A késői diagnózis életveszélyes szövődmények, mint medencei sepsis, kialakulását okozhatja. A rectum sérüléssel társult HE-PRI esetek azonosításával, a közös vonások keresésével vizsgáltuk a típusos sérülések jellegzetességeit.

Beteganyag és módszerek: Prospektív adatbázisunkat 4 évre visszamenően tekintettük át. Átvizsgáltuk az észlelt esetek kórházi dokumentációját, beleértve a radiológiai képalkotókat, a műtéti leírásokat és az elhunytak kórbonctani leleteit. Az észlelt HE-PRI-vel társult rectum sérülések közös jellegzetességeit kerestük.

Eredmények: A 194 HE-PRI betegből 4 esetben (2%) társult rectum sérülés. Ezek a betegek jelentősen idősebbek, súlyosabban sérültek voltak, több transzfúziót igényeltek, és tovább tartózkodtak kórházban, mint a többi HE-PRI sérült. Mindegyikük súlyos társsérüléseket szenvedett: arckoponya (1), agy (1), mellkas (2), urethra (2), hólyag (1), komplex végtag (3). Mindegyikük többszörös műtéteket igényelt a medencegyűrű és a társsérülések miatt. Mindegyik sérült túlélt (a teljes kohort mortalitása 7,8%). A törések besorolása: AO/OTA 61B1 és Y-B APCII 3 esetben és 61B3/APCIII 1 esetben. Mindegyik esetben a symphysis szakadása 2,5 cm-nél nagyobb megnyílással járt. A mechanizmusok elemzésekor a közös vonás az AP irányú erőbehatás volt az alsó végtagok kifelé rotációjával: lovagláskor a medence nyeregnek ütközött (1), motorozáskor a tanknak ütközött (2), kerékpárosként autóval ütközött (1). Egy beteg nagy gáttáji sebe a rectum elülső falára terjedt, a másik három esetben a sérülés a rectum elülső falán lévő 2-4cm-es szakadás az anustól 3-5cm távolságra volt. A rectum sérülését a székletet divertáló colostomával kezeltük minden esetben. A szakadás direkt zárása egy esetben történt. A gáttáji sebet több lépésben láttuk el.

5. Féloldali sacro-iliacalis ízületi (SIJ) ficam intakt elülső medencegyűrűvel

Bevezetés: A gyűrű struktúra miatt nagy energiájú erőbehatáskor a medence szinte mindig két ponton sérül. A gyűrű elülső része (pubis és szárak) mechanikailag gyengébb, sokkal gyakrabban sérül akár önmagában is. A HE-PRI sérülések vizsgálata során észleltünk két esetet, amikor a hátsó rész (SIJ ficam) sérülést izoláltan jelentkezett. A második eset észlelése után feltételeztük, hogy ezek a sérülések ritkák, de talán már több eset is létezik.

Beteganyag és módszerek: Prospektív adatbázisunk 4 évét áttekintettük, beleértve az összes eset képalkotó vizsgálatait, függetlenül a törés típusától. Az észlelt esetek kórházi dokumentációját átvizsgálva (beleértve a sérülési mechanizmusokat, társsérüléseket, ellátást és eredményeket) hasonlóságokat kerestünk. Az angol nyelvű irodalomban (MedLine 1950-tól, PubMed) „unstable pelvis", „sacroiliac joint disruption/dislocation" és „intact anterior pelvic ring" kulcsszavakkal kerestünk publikációkat.
Eredmények: Összesen két beteg esetében észleltünk féloldali SIJ ficamot intakt elülső gyűrű mellett. Mindkét beteg 18 éves férfi volt. Mindkettőt nagy-energiájú erőhatás érte: egyikük autóbaleset utasaként sérült, a másik motorkerékpárral esett el. A sérülések AO/OTA 61C1 és Y-B CM besorolást kaptak. Mindkét betegnél kiterjedt lágyrész károsodással társult a gluteális régióban (Morel-Lavallee). A műtéti ellátás során a SIJ fedett repozíciója és rögzítése történt a csípőlapát felől percután bevezetett kanülált csavarokkal, melyek az S1 és S2, illetve az S1 csigolyatestben rögzültek. A műtétek során teszteltük az elülső gyűrű stabilitását: rögzítés előtt és után is stabilak voltak. A Morel-Lavalee léziók is sebészi kezelést igényeltek: kétoldalról, kis metszésekből drainálás történt, majd szívó kezelés. Mindkét beteg teljesen felépült, tartósan semmilyen tevékenységében nem korlátozott. Az irodalom áttekintése során mindössze egy újabb hasonló esetet találtunk, melyet két évvel később publikáltak.

Következtetések összegzése:

1. A sürgősségi non-invazív medencegyűrű stabilizálás hatékony és biztonságos módszer, még az elsődleges ellátók kezében is. Minden B1 és legtöbb C típusú sérülés esetében javítja a törés helyzetét. Bizonyos B2 és B3 törések esetében a deformitás fokozódott, de következményként semmiféle klinikailag jelentős szövődményt nem tudtunk igazolni.

2. Fiziológiai paraméterek, mint BD> 6mmol/L, BD növekedése> 2mmol/L, a systolés vérnyomás <104mmHg és transzfúzió igénye az első 4 órában, mind képesek előjelezni a PFRAB-t. Az egyéb vérzésforrások kizárása után ezen értékek hasznosak lehetnek a HE-PRI sérültek osztályozásában az angiográfiás vérzéscsillapítás irányába.

3. Akut medencegyűrű stabilizálás a HE-PRI sérültek válogatott eseteiben biztonságosan és hatékonyan kivihető. Az észlelt tendencia jobb eredmények felé akut stabilizálás esetén, további vizsgálatokkal esetleg igazolható.

4. Rectum sérülések a HE-PRI esetek 2%-ában fordulnak elő, AP irányú erőbehatás eredményei. Fizikális vizsgálattal észlelhetőek, mert vagy láthatóak a külvilág felé vagy ujjal elérhetőek digitális vizsgálatkor; az elülső falon helyezkednek el az anustól 3-5cm távolságra.

5. Unilaterális SIJ ficamok intakt elülső medencegyűrűvel, ritka sérülések nagy-energiájú erőbehatást követően. Súlyos lágyrész károsodásokkal társultak az észlelt eseteinkben. A fiatal sérülteken létrejöhetnek hátsó medencegyűrű sérülések az elülső rész törése/ficama nélkül.

References

1. White CE, Hsu JR, Holcomb JB. Haemodynamically unstable pelvic fractures. *Injury*. 2009;40:1023-30
2. Starr AJ, Griffin DR, Reinert CM, et al. Pelvic ring disruptions: prediction of associated injuries, transfusion requirement, pelvic arteriography, complications and mortality. *J Orthop Trauma*. 2002; 16(8):553-61
3. Demetriades D, Karaiskakis M, Toutouzas K. Pelvic fractures: Epidemiology and predictors of associated abdominal injuries and outcomes. *J Am Coll Surg*. 2002; 195(1):1-10
4. Gansslen A, Pohlemann T, Lobenhoffer P et al. Epidemiology of pelvic ring injuries. *Injury*. 1996. Suppl.A13-20
5. Papadopoulos IN, Kanakaris N, Bonovas S et al. Auditing 655 fatalities with pelvic fractures by autopsy as a basis to evaluate trauma care. *J Am Coll Surg*. 2006; 203:30-43
6. Parreira JG, Coimbra R, Rasslan S. The role of associated injuries on outcomes of blunt trauma patients sustaining pelvic fractures. *Injury*. 2000;31:677-682
7. Pohlemann T, Stengel D, Tosounidis G et al. Survival trends and predictors of mortality in severe pelvic trauma: estimates from the German pelvic trauma registry initiative. *Injury*. 2011;42:997-1002
8. Lopez PP. Unstable pelvic fractures the use of angio for controlling haemorrhage. *J Trauma*. 2007;62:S30-31
9. Balogh ZJ, King KL, Mackay P et al: The epidemiology of pelvic ring fractures: a population based study, *J Trauma* 2007 Nov (63) 1066-73
10. Tien HC, Spencer F, Tremblay LN, et al. Preventable deaths from haemorrhage at a level 1 Canadian trauma center. *J Trauma*. 2007; 62:142-146
11. Smith W, Williams A, Agudelo J et al. Early predictors of mortality in haemodynamically unstable pelvic fractures. *J Orthop Trauma*. 2007;21:31-37
12. Simpson T, Kreig J, Heuer F: Stabilization of pelvic ring disruptions with a circumferential sheet, *J Trauma* 2002, 52, 158-61
13. Routt C M, Felicov A, Woodhouse E et al: Circumferential Pelvic Antishock Sheeting: A Temporary Resuscitation Aid, *J Orthop Trauma* 2002, Vol 16, No 1, pp 45-48
14. Krieg JC, Mohr M, Ellis TJ: Emergent stabilization of pelvic ring injuries by controlled circumferential compression: a clinical trial, *J Trauma* 2005, 59: 659-64
15. Spanjersberg WR, Knops SP, Schep NW: Effectiveness and complications of pelvic circumferential compression devices in patients with unstable pelvic fractures: A systematic review of literature, *Injury* 2009, 1031-103
16. American College of Surgeons Committee on Trauma: Advanced Trauma Life Support for Doctors, Student Course Manual, 8th edition, 2008
17. Heetveld M: Management of haemodynamically unstable patients with a pelvic fracture, Institute of Trauma and Injury Management NSW, Australia, Adult Trauma Guidelines, Jan 2007

18. Heetveld MJ, Harris I, Schlaphoff G: Guidelines for the management of haemodynamically unstable pelvic fracture patients, *ANZ J Surg* 2004; 74: 520-529
19. Hak DJ. The role of pelvic angiography in evaluation and management of pelvic trauma. *Orthop Clin N Am*. 2004; 35:439-43
20. Metz CM, Hak DJ, Goulet JA, et al. Pelvic fracture patterns and their corresponding angiographic sources of haemorrhage. *Orthop Clin N Am*. 2004; 35:431-7
21. O'Neill PA, Riina J, Sclafani S, et al. Angiographic findings in pelvic fractures. *Clin Orthop Relat Res*. 1996; 329:60-7
22. Kataoka Y, Maekawa K, Nishimaki H et al. Iliac vein injuries in hemodynamically unstable patients with pelvic fracture caused by blunt trauma. *J Trauma* 2005;58:704-10
23. DiGiacomo J C, Bonadies J A, Cole F J et al: Practice Management Guidelines for Haemorrhage in Pelvic Fracture, The EAST Practice Management Guidelines 2001
24. Cullinane DC, Schiller HJ, Zielinski MD et al. Eastern Association for the Surgery of Trauma Practice Management Guidelines for haemorrhage in pelvic fracture – Update and systematic review. *J Trauma*. 2011;71:1850-68
25. Balogh ZJ, Caldwell E, Heetveld M et al. Institutional practice guidelines on management of pelvic fracture related haemodynamic instability: do they make a difference? *J Trauma*. 2005;58:778-782
26. Biffl WL, Smith WR, Moore EE: Evolution of a multidisciplinary pathway for the management of unstable patients with pelvic fractures, Annals of Surgery 2001, 233, (6) 843-850
27. Poole GV, Ward EF, Muassaka FF et al. Pelvic fracture from major blunt trauma: outcome is determined by associated injuries. *Ann Surg*. 1991; 213:532-8
28. Burch JM, Feliciano DV, Mattox KL. Colostomy and drainage for civilian rectal injuries: is that all? *Ann Surg*. 1989; 20(5):600-611
29. Burch JM. Injury to the colon and rectum. Trauma 5th Edition. McGraw-Hill; 2004. Chapter 35:735-755
30. Leenen LPH, Werken C, Schoots F. Internal fixation of open unstable pelvic fractures. *J Trauma*. 1993; 35:220-225
31. Vrahas MS, Reid JS. Late recognition of a rectal tear associated with a pelvic fracture – a case report. *J Bone Joint Surg Am*. 1994; 76(7):1072-1076
32. Berman AT, Tom L. Traumatic separation of the pubic symphysis with associated fatal rectal tear: A case report and analysis of mechanism of injury. *J Trauma*. 1974; 14(12):1060-1067
33. Tang P, Meredick R, Prayson M et al. External fixation of the pelvis. *Techn Orthop*. 2002;17:228-38
34. Heini PF, Witt J, Ganz R. The pelvic C-clamp for the emergency treatment of unstable pelvic ring injuries: a report on clinical experience of 30 cases. *Injury*. 1996;Suppl A38-45

35. Krieg JC, Mohr M, Mirza AJ: Pelvic circumferential compression in the presence of soft-tissue injuries: a case report, *J Trauma* 2005, 59: 470-2
36. Schaller TM, Sims S, Maxian T: Skin breakdown following circumferential pelvic antishock sheeting, a case report, *J Orthop Trauma* 2005, 19: 661-665
37. Tile M. Acute pelvic fractures: I. Causation and classification. *J Am Acad Orthop Surg*. 1996;4:143-51
38. Isler B, Ganz R. Classification of pelvic ring injuries. Injury 1996;Suppl A3-12
39. Burgess AR, Eastridge BJ, Young JWR, et al. Pelvic ring disruptions: effective classification system and treatment protocols. *J Trauma*. 1990; 30:848-56
40. Eastridge B: Butt binder, *J Trauma* 2007, 62: S32
41. Routt M L, Simonian P T, Ballmer F: A rational approach to pelvic trauma, Resuscitation and early definitive stabilization, *Clin Orthop and Rel Research* 1995, 318, 61-74
42. Bottlang M, Simpson T, Sigg J: Noninvasive reduction of open-book pelvic fractures by circumferential compression, *J Orthop Trauma* 2002, 16: 367-373
43. Bottlang M, Krieg J, Mohr M et al: Emergent management of pelvic ring fractures with use of circumferential compression, *JBJS Am* Vol 84A Suppl 2 2002, 43-47
44. Jovett AJ, Bowyer GW. Pressure characteristics of pelvic binders. *Injury*. 2007;38:118-121
45. Croce M A, Magnotti L J, Savage S A et al: Emergent pelvic stabilization in patients with exsanguinating pelvic fractures, *Am Col Surg* May 2007, 204, 935-9
46. Ghaemmaghami V, Sperry J, Gunst M et al. Effects of early use of external pelvic compression on transfusion requirements and mortality in pelvic fractures. *Am J Surg*. 2007;194:720-3
47. Schank JR, Morgan SJ, Smith WR: Bilateral peroneal nerve palsy following emergent stabilization of a pelvic ring injury, *J Orthop Trauma* 2003; 17: 67-70
48. Cotren CC, Osborn PM, Moore EE et al. Preperitoneal pelvic packing for haemodynamically unstable pelvic fractures: a paradign shif. *J Trauma*. 2007;62:834-842
49. Routt M L, Simonian P T: Stabilization of pelvic ring disruptions, *Orthop Clin North Am* 1997, 28, 369-88
50. Tötterman A, Madsen JE, Skaga NO, et al. Extraperitoneal pelvic packing: a salvage procedure to control massive traumatic pelvic haemorrgahe. *J Trauma*. 2007; 62(4):843-52
51. Ertel W, Keel M, Eid K, et al. Control of severe haemorrhage using C-clamp and pelvic packing in multiply injured patients with pelvic ring disruption. *J Orthop Trauma*. 2001; 15:468-474
52. Smith WR, Moore EE, Osborn P et al. Retroperitoneal packing as a resuscitation technique for hemodynamically unstable patients with pelvic fractures: report of two representative cases and a description of technique. *J Trauma*. 2005;59:1510-4
53. Henry SM, Pollak AN, Jones AL, et al. Pelvic fracture in geriatric patients: a distinct clinical entity. *J Trauma*. 2002; 53(1):15-20

54. Kimbrell BJ, Velmahos GC, Chan LS, et al. Angiographic embolization for pelvic fractures in older patients. *Arch Surg*. 2004; 139:728-33
55. Agolini SF, Shah K, Jaffe J et al. Arterial embolization is a rapid and effective technique for controlling pelvic fracture haemorrhage. *J Trauma*. 1997;43:395-9
56. Cook RE, Keating JF, Gillespie I. The role of angiography in the management of haemorrhage from major fractures of the pelvis. 2002; *J Bone Joint Surg*. 84-B(2):178-82
57. Fangio P, Asehnoune K, Edouard A et al. Early embolization and vasopressor administration for management of life-threatening haemorrhage from pelvic fracture. *J Trauma*. 2005;58:978-984
58. Hagiwara A, Minakawa K, Fukushima H el at. Predictors of death in patients with life-threatening pelvic haemorrhage after successful transcatheter embolization. *J Trauma*. 2003;55:696-703
59. Gansslen A, Giannoudis P, Pape HC, et al. Hemorrhage in pelvic fracture: who needs angiography? *Curr Opin Crit Care*. 2003; 9:515-23
60. Wong YC, Wang LJ, Ng CJ et al. Mortality after successful transcatheter arterial embolization in patients with unstable pelvic fractures: rate of blood transfusion as a predictive factor. *J Trauma*. 2000;49:71-4
61. Blackmore CC, Cummings P, Jurkovich GJ, et al. Predicting major hemorrhage in patients with pelvic fracture. *J Trauma*. 2006; 61:346-352
62. Blackmore CC, Jurkovich GJ, Linnau KF, et al. Assessment of volume of hemorrhage and outcome from pelvic fracture. *Arch Surg*. 2003; 138:504-9
63. Brasel KJ, Yang H, Christensen R. Significance of contrast extravasation in patients with pelvic fracture. *J Trauma*. 2007; 62(5):1149-52
64. Brown CVR, Kasotakis G, Wilcox A. Does pelvic haematoma on admission computed tomography predict active bleeding at angiography for pelvic fracture? *Am Surg*. 2005; 71(9):759-62
65. Elzik ME, Dirschl DL, Dahners LE. Haemorrage in pelvic fractures does not correlate with fracture length. *J Trauma* 2008;65:436-441
66. Hamill J, Holden A, Paice R. Pelvic fracture pattern predicts pelvic arterial haemorrhage. *ANZ J Surg*. 2000; 70:338-43
67. Miller PR, Moore PS, Mansell E, et al. External fixation or arteriogram in bleeding pelvic fracture: Initial therapy guided by markers of arterial hemorrhage. *J Trauma*. 2003; 54(3):437-43
68. Niwa T, Takebayashi S, Igari H, et al. The value of plain radiographs in the prediction of outcome in pelvic fractures treated with embolisation therapy. *Br J Radiol*. 2000;73: 945-50
69. Pereira S, O'Brien D, Luchette FA. Dynamic helical computed tomography scan accurately detects hemorrhage in patients with pelvic fracture. *Surgery*. 2000; 128(4):678-85
70. Sadri H, Nguyen-Tang T, Stern R. Control of severe haemorrhage using C-clamp and arterial embolization in haemodynamically unstable patients with pelvic ring disruption. *Arch Orthop Trauma Surg*. 2005; 125:443-7

71. Salim A, Teixeira P, DuBose J, et al. Predictors of positive angiography in pelvic fractures: A prospective study. *J Am Coll Surg*. 2008; 207(5):656-62
72. Sarin EL, Moore JB, Moore EE, et al. Pelvic fracture pattern does not always predict the need for urgent embolization. *J Trauma*. 2005; 58:973-7
73. Shapiro M, McDonald AA, Knight D et al. The role of repeat angiography in the management of pelvic fractures. *J Trauma*. 2005;58:227-31
74. Stephen DJ, Kreder HJ, Day AC, et al. Early detection of arterial bleeding in acute pelvic trauma. *J Trauma*. 1999; 47(4):638-42
75. Velmahos GC, Toutouzas KG, Vassiliu P, et al. A prospective study on the safety and efficacy of angiographic embolization for pelvic and visceral injuries. *J Trauma.* 2002; 52(2):303-8
76. Eastridge BJ, Starr A, Minei JP, et al. The importance of fracture pattern in guiding therapeutic decision-making in patients with haemorrhagic shock and pelvic ring disruptions. *J Trauma*. 2002; 53(3):446-51
77. Perez JV, Hughes MD, Bowers K. Angiographic embolization in pelvic fracture. *Injury.* 1998;29:187-91
78. Jeske HC, Larndofer R, Krappinger D et al. Management of haemorrhage in severe pelvic injuries. *J Trauma*. 2010;68:415-20
79. Osborn PM, Smith WR, Moore EE et al. Direct retroperitoneal packing versus pelvic angiography: a comparison of two management protocols for haemodynamically unstable pelvic fractures. *Injury*. 2009;40:54-60
80. Sisak K, Manolis M, Hardy BM et al. Acute transfusion practice during trauma resuscitation: Who, when, where and why? *Injury.* In Press
81. Fu CY, Wu SC, Chen RJ et al. Evaluation of pelvic fracture stability and the need for angioembolization: pelvic instabilities on plain film have an increased probability of requiring angioembolization. *Am J Emerg Med*. 2009;27:792-796
82. Callaway DW, Shapiro NI, Donnino MW, et al. Serum lactate and base deficit as predictors of mortality in normotensive blunt elderly trauma patients. *J Trauma*. 2009; 66: 1040-1044
83. Neville AL, Nemstev D, Manasrah R, et al. Mortality risk stratification in elderly trauma patients based on initial arterial lactate and base deficit levels. *Am Surg*. 2011; 77: 1337-41
84. Paladino L, Sinert R, Wallace D, et al. The utility of base deficit and arterial lactate in differentiating major from minor injury in trauma patients with normal vital signs. *Resuscitation.* 2008; 77: 363-368
85. Ramirez JJ, Velmahos GC, Best CR et al. Male sexual function after bilateral internal iliac artery embolization for pelvic fracture. *J Trauma*. 2004;56:734-41
86. Yasumura K, Ikegami K, Kamohara T et al. High incidence of ischaemic necrosis of the gluteal muscle after transcatheter angiographic embolization for severe pelvic fracture. *J Trauma*. 2005;58:985-90
87. Velmahos GC, Chahwan S, Hanks S et al. Angiographic embolization of bilateral internal iliac arteries to control life-threatening haemorrhage after blunt trauma to the pelvis. *Am Surg*. 2000;66:858-62

88. Giannoudis PV, Pape HC. Damage control orthopaedics in unstable pelvic ring injuries. *Injury*. 2004;35:671-7
89. Probst C, Probst T, Gansslen A et al. Timing and duration of the initial pelvic stabilization after multiple trauma in patients from the German trauma registry: is there an influence on outcome? *J Trauma*. 2007;62:370-7
90. Pape HC, Rixen D, Morley J et al. Impact of the method of initial stabilization for femoral shaft fractures in patients with multiple injuries at risk for complications (Borderline patients). *Ann Surg*. 2007;246:491-501
91. Pape HC, Giannoudis PV, Krettek C. The timing of fracture treatment in polytrauma patients: relevance of damage control orthopaedic surgery. *Am J Surg*. 2003;83:622-629
92. Pape HC. Effects of changing strategies of fracture fixation on immunologic changes and systemic complications after multiple trauma: damage control orthopaedic surgery. *J Orthop Res*. 2008;26:1478-84
93. Pape HC, Grimme K, Griensven M et al. Impact of intramedullary instrumentation versus damage control for femoral fractures on immunoinflammatory parameters: prospective randomized analysis by the EPOFF study group. *J Trauma*. 2003;55:7-13
94. Anwar IA, Battistella FD, Neiman R et al. Femur fractues and lung complications. *Clin Orthop Rel Res* 2004;422:71-6
95. Bone LB, Johnson DK, Weigelt J. Early versus delayed stabilization of femur fractures. *J Bone Jonit Surg Am*. 1989;71:336-40
96. Bosse MJ, McKenzie EJ, Riemer BL et al. Adult respiratory distress syndrome, pneumonia and mortality following thoracic injury and femoral fracture treated either with intramedullary nailing with reaming or with plate. *J Bone Joint Surg Am* 1997;79:799-809
97. Scalea T. Optimal timing of fracture fixation:have we learned anything in the last 20 years? *J Trauma*. 2008;65:253-60
98. Dunham MC, Bosse MJ, Clancy TV et al. Practice management guidelines for the optimal timing of long-bone fracture stabilization in polytrauma patients: the EAST practice management guideline work group. *J Trauma*. 2001;50:958-67
99. Pape HC, Hildebrand F, Pertschy F, Zelle B et al. Changes is the management of femoral shaft fractures in polytrauma patients: from early total care to damage control orthopaedic surgery. *J Trauma*. 2002;53:452-62
100. Harwood PJ, Giannoudis PV, Griensven M et al. Alterations in the systemic inflammatory response after early total care and damage control procedures for femoral shaft fracture in severely injured patients. *J Trauma*. 2005;58:446-454
101. Katsoulis E, Giannoudis PV. Impact of timing of pelvic fixation on functional outcome. *Injury*. 2006;34:1133-42
102. Aihara R, Blansfield JS, Frederick H, et al. Fracture locations influence the likelihood of rectal and lower urinary tract injuries in patients sustaining pelvic fractures. *J Trauma*. 2002; 52:205-209
103. Ferrera PC, Hill DA. Good outcomes of open pelvic fractures. *Injury*. 1999; 30:187-190

104. Davidson BS, SimmonsGT, Williamson PR, et al. Pelvic fractures associated with open perineal wounds: a survivable injury. *J Trauma*. 1993; 35:36-39
105. Birolini D, Steinman E, Utiyama EM, et al. Open pelviperineal trauma. *J Trauma*. 1990; 30(4):492-496
106. Dong J, Dong Z. Management and outcome of open pelvic fractures: a retrospective study of 41 cases. *Injury.* 2011;41:1003-7
107. Govender S, Sham A, Singh B. Open pelvic fractures. Injury. 1990; 21:373-376
108. Hanson PB, Milne JC, Chapman MW. Open fractures of the pelvis: review of 43 cases. *J Bone Joint Surg Br*. 1991;73B:325-9
109. Grotz MR, Allami MK, Harwood P et al. Open pelvic fractures: epidemiology, current concepts, of management and outcome. *Injury.* 2005;36:1-13
110. Esposito TJ, Ingraham A, Luchette FA. Reasons to omit rectal digital exam in trauma patients: no rectum, no fingers, no useful additional information. *J Trauma.* 2005;59:1314-9
111. Ball GC, Jafri M, Kirkpatrick AW et al. Traumatic urethral injuries: does the digital rectal examination really help us? *Injury.* 2009;40:984-6
112. Kristinsson G, Wall SP, Crain EF. The digital rectal examination in pediatric trauma: a pilot study. *J Emerg Med.* 2007;32:59-62
113. Levine H, Simon RJ, Smith TR, et al. Guaiac testing in the diagnosis of rectal trauma: what is its value? *J Trauma.* 1992; 32(2):210-212
114. Lunsjo K, Abu-Zidan FM. Does colostomy prevent infection in open blunt pelvic fractures? A systematic review. *J Trauma*. 2006; 60(5): 1145-1148
115. Gonzalez RP, Phelan H, Hassan M et al. Is fecal diversion always necessary for nondestructive penetrating extraperitoneal rectum injuries? *J Trauma.* 2006;61:815-9
116. Navsaria PH, Graham R, Nicol A. A new approach to extraperitoneal rectal injuries: laparoscopy and diverting loop colostomy. *J Trauma*. 2001;51:532-5
117. Weinberg JA, Fabian TC, Magnotti LJ et al. Penetrating rectal trauma: management by anatomic distinction improves outcome. *J Trauma*. 2006; 60:508-514
118. Faringer PD, Mullins RJ, Feliciano PD. Selective faecal diversion in complex open pelvic fractures from blunt trauma. *Arch Surg*. 1994; 129:958-964.
119. Woods RK, O'Keefe G, Rhee P. Open pelvic fractures and faecal diversion. *Arch Surg.* 1998; 133:281-286
120. Pell M, Flynn WJ, Seibel RW, et al. Is colostomy always necessary in the treatment of open pelvic fractures? *J Trauma*. 1998; 45(2):371-373
121. Brenneman FD, Katyal D, Boulanger BR, et al. Long-term outcomes in open pelvic fractures. *J Trauma*. 1997; 42(5):773-777
122. Tile M, Helfet D, Kellam J. Fractures of the pelvis and acetabulum. Lippincott Williams & Wilkins. 2003
123. Smith WR, Ziran BH, Morgan SJ. Fractures of the pelvis and acetabulum. Informa Healthcare. 2007
124. Tseng S, Tornetta P. Percutaneous management of Morel-Lavallee lesions. *J Bone Joint Surg Am*. 2006; 88:92-96

125. Bouguennec N, Gourin F, Pietu G et al. Isolated anterior unilateral sacroiliac dislocation without pubic arch disjunction. *Orthop Traumatol Surg Res*. 2012:98:359-62
126. Wright Z, Zelle B. Bilateral sacroiliac joint dislocation without associated fracture or anterior pelvic ring injuries. *J Orthop Trauma*. 2004;18:634-637
127. Loupasis G, Anastopoulos G. Pure bilateral sacroiliac dislocation with intact anterior pelvis. *Injury.* 2005; 36:1379-1382
128. Stevens KJ, Preston BJ. Bilateral fracture dislocation of the sacroiliac joint. *Skeletal Radiol*. 1997; 26:556-558
129. Lafollette BF, Levine MI. Bilateral fracture dislocations of the sacrum. J Bone *Joint Surg Am*. 1986; 68:1099-1101
130. Marcus RE, Hansen ST. Bilateral fracture dislocation of the sacrum. *J Bone Joint Surg Am.* 1984; 66:1297-1299
131. Nagi ON, Mandeep S. Bilateral fracture dislocation of the sacrum without injury to the anterior pelvis. *Orthopaedics.* 1993; 16:215-217
132. McCormick JP, Morgan SJ. Clinical effectiveness of the physical examination in disgnosis of posterior pelvic ring injuries. *J Orthop Trauma*. 2003; 17:257-261
133. Vanderschot PMJ, Broens PMA. Trans iliac-sacral-iliac bar stabilization to treat bilateral sacroiliac joint disruptions. *Injury.* 1999; 30:637-640

Appendix

Radiographs

Copies of publications related to the thesis

Radiograph 1A, B

Angiogram demonstrates intimal injury of the common femoral artery.

Radiograph 2A, B

AP pelvis radiographs with pelvic custom made orthesis applied.

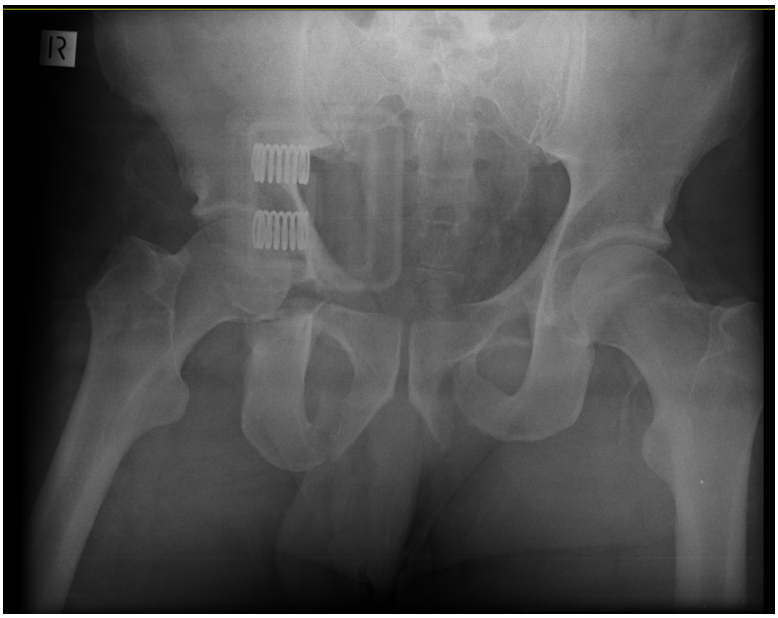

CT pelvis cystogram demonstrates contrast leakage from the bladder.

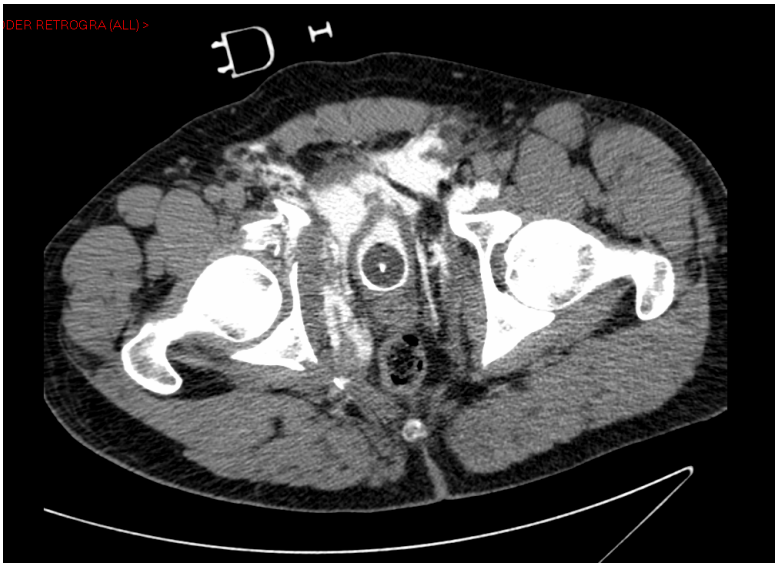

Radiograph 3A, B

Typical preoperative and postoperative images of a patient after acute definitive pelvic fixation with iliosacral lag screw and pubic symphysis plate.

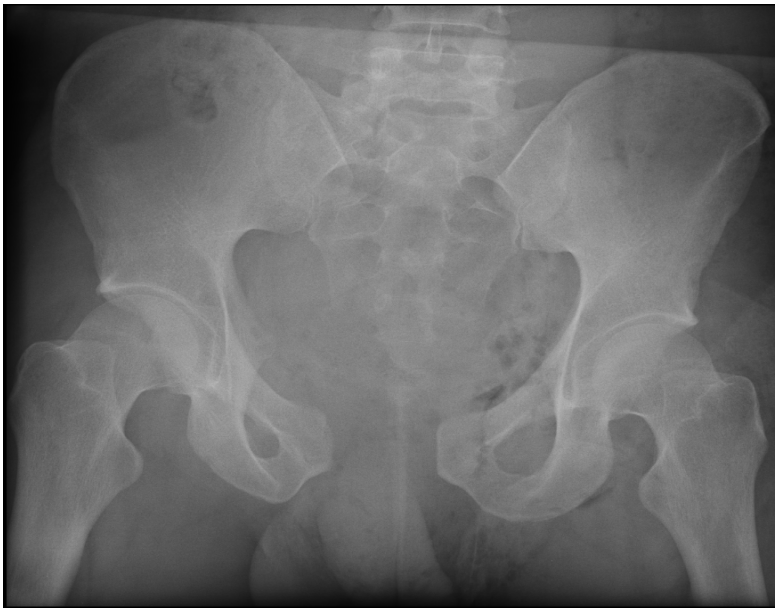

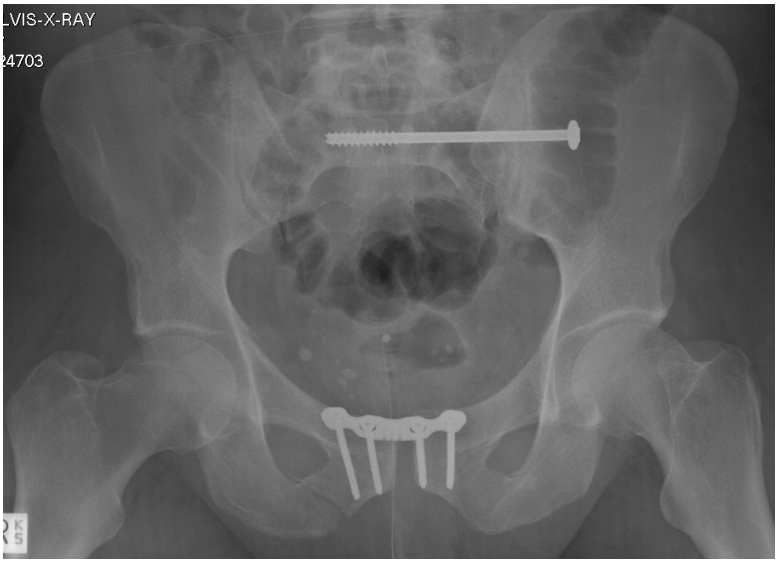

Radiograph 4A, B, C, D

Emergency Department AP pelvis radiographs of patients with associated rectum tears. (all 4 cases)

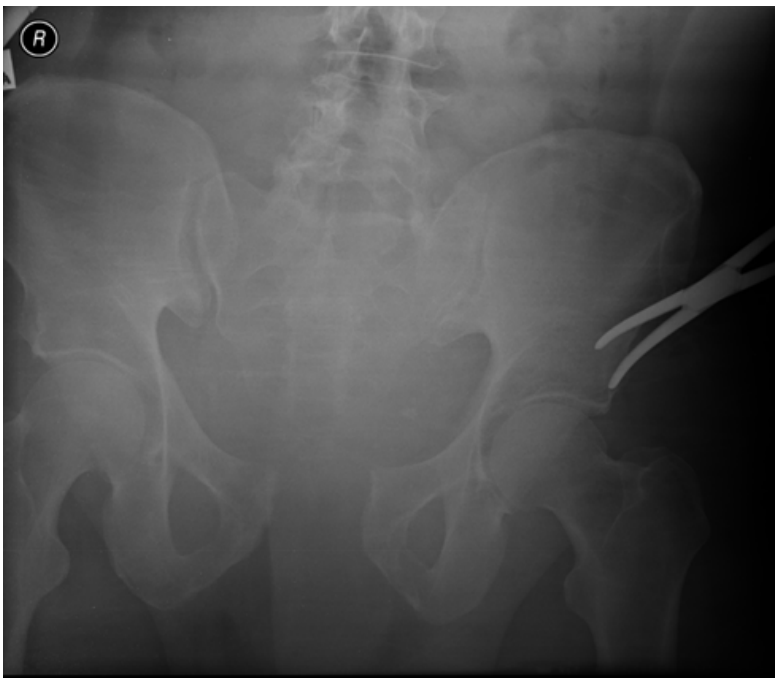

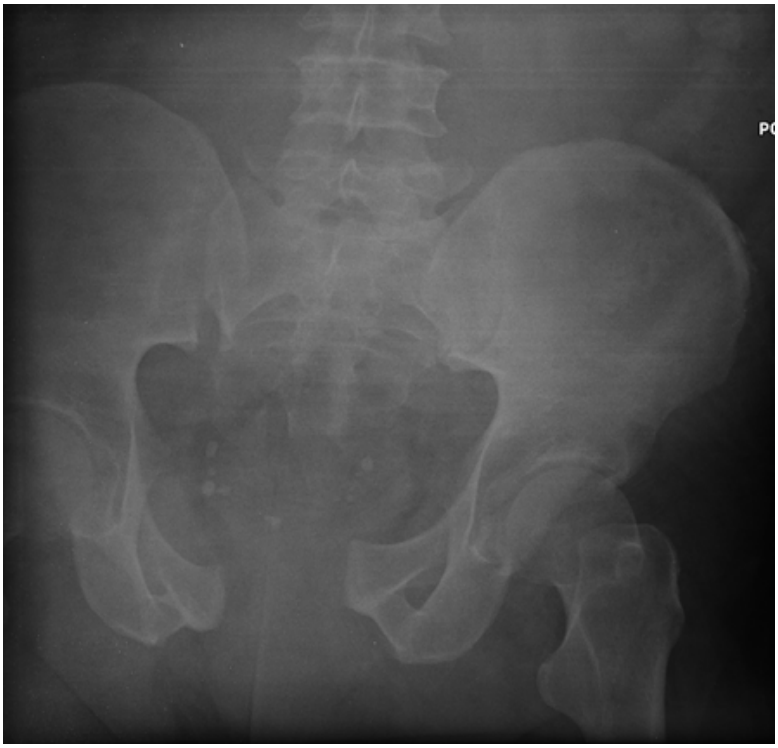

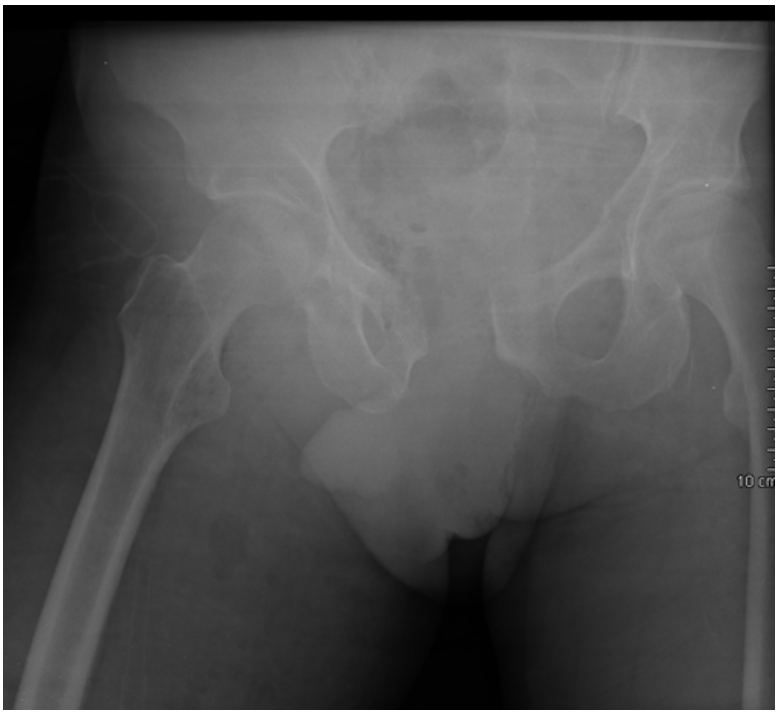


L

Radiograph 5A, B

Emergency Department AP pelvis radiographs of patients with unilateral SIJ disruption and intact anterior pelvic ring. (both cases)


10 cm
L
C
M
C 2048
W 4096