Pediatric laparoscopic procedures in special indications

Ph.D. THESIS

Brigitta Balogh M.D.

Department of Pediatrics, University of Szeged

Faculty of Medicine

Doctoral School of Clinical Medicine

Supervisor: Tamás Kovács M.D., Ph.D.

Szeged 2021

TABLE OF CONTENTS

LIST OF PUBLICATIONS RELATED TO THE SUBJECT OF THE THESIS 3
LIST OF ABBREVIATIONS IN THE TEXT 4
1. INTRODUCTION 5
1.1. Laparoscopy in incarcerated inguinal hernia 6
1.2. Laparoscopic-assisted percutaneous endoscopic gastrostomy 7
1.3. Laparoscopic-assisted ventriculoperitoneal shunt revision 7
2. AIMS OF THE THESIS 7
3. PATIENTS AND METHODS 8
3.1. Laparoscopy in incarcerated inguinal hernia 8
3.1.1. Manual reduction and delayed surgery (MRDS) 8
3.1.2. Manual reduction in general anesthesia (MRGA) 8
3.1.3. Intraoperative reduction (IOR) 8
3.2. Laparoscopic-assisted percutaneous endoscopic gastrostomy 8
3.2.1. Original pull technique 9
3.2.2. Laparoscopic-assisted percutaneous endoscopic gastrostomy 9
3.3. Laparoscopic-assisted ventriculoperitoneal shunt revision 9
3.3.1. Open revision of distal catheter of VP shunt 9
3.3.2. Laparoscopic-assisted revision of distal catheter of VP shunt 10
4. RESULTS 10
4.1. Laparoscopy in incarcerated inguinal hernia 10
4.2. Laparoscopic-assisted percutaneous endoscopic gastrostomy 11
4.3. Laparoscopic-assisted ventriculoperitoneal shunt revision 12
5. DISCUSSION 13
5.1. Laparoscopy in incarcerated inguinal hernia 13
5.2. Laparoscopic-assisted percutaneous endoscopic gastrostomy 14
5.3. Laparoscopic-assisted ventriculoperitoneal shunt revision 16
6. CONCLUSION 18
6.1. Laparoscopy in incarcerated inguinal hernia 18
6.2. Laparoscopic-assisted percutaneous endoscopic gastrostomy 18
6.3. Laparoscopic-assisted ventriculoperitoneal shunt revision 18
6.4. Summary of new findings 18
ACKNOWLEDGEMENTS 19

LIST OF PUBLICATIONS RELATED TO THE SUBJECT OF THE THESIS

1. Complications in children with percutaneous endoscopic gastrostomy (PEG) placement.
   Balogh B, Kovács T, Saxena AK.
   World J Pediatr. 2019 Feb;15(1):12-16

   IF: 1.437

2. Outcomes of laparoscopic incarcerated inguinal hernia repair in children.
   Balogh B, Hajnal D, Kovács T, Saxena AK
   J Minim Access Surg. 2020 Jan-Mar;16(1):1-4.

   IF: 1.407

3. Training for pediatric surgeons through the keyhole
   Balogh B, Kovács T.
   Orv Hetil. 2018 Oct;159(43):1747-1753.

   IF: 0.564

4. Laparoscopic-assisted percutaneous endoscopic gastrostomy reduces major complications in high-risk pediatric patients
   Balogh B, Szűcs D, Rieth A, Gavallér G, Kovács T.
   Pediatr Gastroenterol Hepatol Nutr. 2021 May;24(3):273-278.

5. Laparoscopic peritoneal catheter revisions reduce the rate of subsequent revisions in pediatric hydrocephalic patients
   Balogh B, Rárosi F, Kovács T.

LIST OF ABBREVIATIONS IN THE TEXT

MIS	minimally invasive surgery
LIHR	Laparoscopic inguinal hernia repair
PEG	Percutaneous endoscopic gastrostomy
TAD	Thoracoabdominal deformity
L-PEG	Laparoscopic assisted percutaneous endoscopic gastrostomy
HC	Hydrocephalus
CSF	Cerebrospinal fluid
VP	Ventriculoperitoneal
MRDS	Manual reduction and delayed surgery
MRGA	Manual reduction in general anesthesia
IOR	Intra-operative reduction
US	Ultrasound

1. INTRODUCTION

In recent decades, minimally invasive surgical techniques have undergone enormous development. Pediatric surgeons adopted minimal invasive surgery (MIS) slowly because in infants and toddlers the relatively smaller traditional incisions and the good healing capacity of children usually lead to good cosmetic results. Small-sized instruments were developing slowly because companies were focusing on adults, and instruments for children –the market of which is much smaller- were much more expensive. The advanced techniques required for pediatric laparoscopic surgeries are associated with a relatively long learning curve. Laparoscopy has a lot of technical difficulty in infants and even in children, because the intraabdominal cavity is smaller, and the liver and spleen are relatively larger than in adults.

The first minimal invasive procedures at Hungarian pediatric surgical departments were performed at the end of the 90's. The first operation to be performed were the same procedures as in adults, for example cholecystectomies or varicocele ligations followed by appendectomies and ovarian procedures. Nowadays, the most common laparoscopic interventions are hernioplasty, appendectomy, cholecystectomy and pyloromyotomy; however, in few centers fundoplication, splenectomy, Meckel-diverticulectomy or even total colectomy are also performed. Most Hungarian centers started to perform MIS for urologic diseases; first for undescended, intraabdominal testes, later for hemi/nephrectomy, and nowadays laparoscopy is the gold standard even for pyeloplasty. Currently, the next step forward is the spread of MIS in newborn pathologies. In more and more cases of esophageal atresia, diaphragmatic hernia and duodenal atresia MIS has been successfully applied in some Hungarian centers.

According to the statistics of Hungarian pediatric surgical centers, the number of MIS-s is five times higher than it was ten years ago. (Table 1)

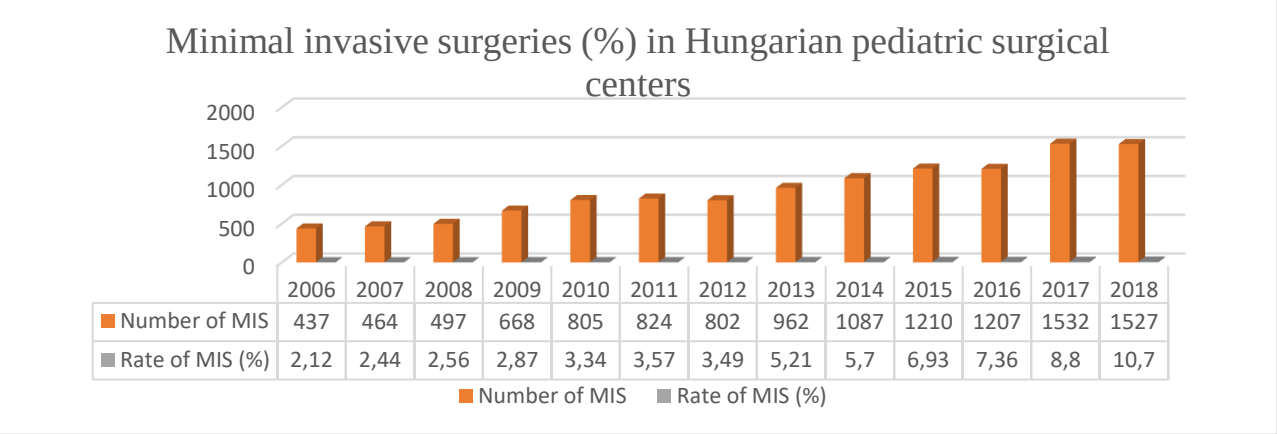

	2006	2007	2008	2009	2010	2011	2012	2013	2014	2015	2016	2017	2018
Number of MIS	437	464	497	668	805	824	802	962	1087	1210	1207	1532	1527
Rate of MIS (%)	2,12	2,44	2,56	2,87	3,34	3,57	3,49	5,21	5,7	6,93	7,36	8,8	10,7

Table 1. The number and rate of minimally invasive surgical procedures in the Hungarian pediatric surgical centers

At the pediatric surgical department of University of Szeged, we perform almost all of the above mentioned common MIS interventions as shown by the increasing number of MIS (Table 2). Also, as pediatric surgery involves all fields of surgery in childhood, cooperation with other subspecialties, like gastroenterology, pulmonology, nephrology and neurosurgery, is essential. We share our experience in MIS in less frequent indications as well, where laparoscopy can offer several benefits and reduce the rate of intraoperative complications, as shown by the following dissertation.

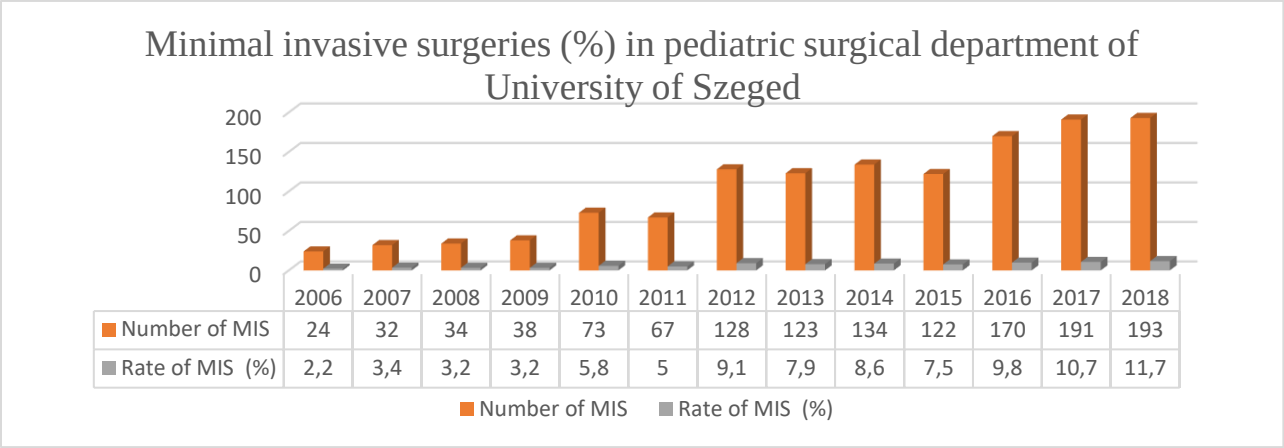

	2006	2007	2008	2009	2010	2011	2012	2013	2014	2015	2016	2017	2018
Number of MIS	24	32	34	38	73	67	128	123	134	122	170	191	193
Rate of MIS (%)	2,2	3,4	3,2	3,2	5,8	5	9,1	7,9	8,6	7,5	9,8	10,7	11,7

Table 2. The number and rate of minimally invasive surgical procedures in our pediatric surgical center (University of Szeged)

1.1. Laparoscopy in incarcerated inguinal hernia

Indirect inguinal hernia repair is one of the most common surgical procedures in pediatric population. Montupet was the first to perform intracorporeal laparoscopic pediatric hernia repair in 1993. Laparoscopic hernioplasty has gradually gained popularity; however, its role in incarcerated cases is not well outlined. The incidence of incarcerated inguinal hernia is as high as 1/6th of the total pediatric population with inguinal hernia. If it is not treated in time, serious complications can develop, such as intestinal obstruction, strangulation and perforation, testicular atrophy or ovarian necrosis. If manual reduction maneuvers fails, urgent surgical treatment is necessary. The conventional open surgery may be difficult to perform in these patients due to inflammation and edema, which in turn may increase the risk of intraoperative injury of the vas deferens or testicular vessels. Laparoscopic inguinal hernia repair (LIHR) gives the advantage of excellent visualization, ability to evaluate contralateral side, less iatrogenic trauma of incarcerated structures, and decreased operative time. Even the pneumoperitoneum

helps to widen the internal ring that can aid in the reduction. After reducing the hernia content, the inguinal ring can be closed in the same session with a minimal access technique, such as purse string suture (intracorporeal) or the hook method (extracorporeal).

1.2. Laparoscopic-assisted percutaneous endoscopic gastrostomy

Enteral tube feeding is indicated in all patients in need of supplementary feeding for more than 2 - 3 weeks. Percutaneous endoscopic gastrostomy (PEG) was first described in 1980 by Gauderer, which is widely used all over the world even though the rate of adverse effects is not low. Laparoscopic guidance during PEG insertion is very useful in patients with severe thoracoabdominal deformities (TAD), hepatomegaly, or following abdominal surgeries, because the site of the puncture is under visual control and hepatic- or colon interposition, vascular injuries are avoidable, adhesions can easily be released.

1.3. Laparoscopic-assisted ventriculoperitoneal shunt revision

Ventriculoperitoneal (VP) shunt placement is the most common treatment for hydrocephalus (HC); however, revisions are often required due to mechanical failure, infection, fracture or disconnection of the catheter. In 25 - 30% of mechanical failures, the distal catheter is obstructed by peritoneal adhesions, cerebrospinal fluid (CSF) pseudocysts, kinking, migration or, rarely, false passage of the distal catheter.

Laparoscopy helps the detection and release of adhesions and it permits the fenestration of CSF pseudocysts. The fractured fragment is easily removable via the use of laparoscopic instruments, and the insertion of a new catheter into the lowest point of the abdominal cavity is visually controlled. If any complications, such as bowel injury, occur during laparoscopy, they can be seen and resolved immediately as part of the laparoscopic procedure.

2. AIMS OF THE THESIS

1. One objective of our study was to prove the efficacy of laparoscopic treatment in irreducible incarcerated inguinal hernia in children by analyzing the literature.
2. We aimed to confirm that laparoscopic assistance during PEG insertions can reduce the rate of intraoperative complications in high-risk patients.
3. Furthermore, we aimed to prove that laparoscopic assistance during VP shunt revision in the abdominal cavity can prolong the postoperative symptom-free period.

3. PATIENTS AND METHODS

3.1. Laparoscopy in incarcerated inguinal hernia

We searched on PubMed® search using the terms “laparoscopic”, „incarcerated”, “inguinal”, “hernia” and “children” from 1998-2018. Data was extracted with regards to the age of the child, sex, side of the hernia, sac content, operative technique, follow-up period, complication and recurrence rate. These data were analyzed in this study.

3.1.1. Manual reduction and delayed surgery (MRDS)

If incarceration of an inguinal hernia has been confirmed, the reduction of the hernia should be attempted manually. The patient is placed in the supine position and his or her pelvis is grasped gently but firmly to prevent any lateral movement of the buttocks. After successful reduction, 24-48 hours later, the hernia should be closed during the day shift, when the patient’s general condition has improved. Hernia repair may be open or it can be performed using a minimally invasive intra- or extracorporeal technique.

3.1.2. Manual reduction in general anesthesia (MRGA)

Sometimes general anesthesia is essential for successful manual reduction, it is advised to do emergency laparoscopy immediately after the reduction, because it provides the direct vision of the reduced hernia content and serosal or deeper intestinal injury, Meckel’s diverticulum or ovarian necrosis.

3.1.3. Intraoperative reduction (IOR)

In case of severely incarcerated hernia, the reduction is successful only with the combination of inner retraction using laparoscopic instruments together with external manual pressure. Carbon dioxide insufflation and intra-abdominal pressure widen the internal inguinal ring, which helps the reduction of the hernia content. After successful reduction, the degree of intestinal injury, ovarian necrosis or other pathologies can be evaluated under direct vision and laparoscopic treatment can be performed.

3.2. Laparoscopic-assisted percutaneous endoscopic gastrostomy

A retrospective analysis was performed on PEG surgeries between January 2014 and December 2019. The data of high risk patients (with severe TAD, previous abdominal surgery or abdominal tumor and VP shunt) were analyzed retrospectively regarding patients' age, gender, diagnosis, indication for surgery, operative time, minor and major complications and mortality, and they were compared in the conventional PEG group and in the L-PEG group. Open gastrostomies, laparoscopic gastrostomies and one-step gastrostomy insertions were excluded from the study.

3.2.1. Original pull technique

The stomach was insufflated by gastroscope; after transillumination the surgeon performed a 5 mm skin incision at the anterior abdominal wall. After puncture and air aspiration, a guidewire was passed through the cannula sheath into the stomach, then it was grasped and pulled out through the oropharynx together with the gastroscope. The loop of the gastrostomy tube was fixed to the guidewire and pulled back through the esophagus into the stomach and out through the puncture site until the internal fixation plate was adjacent to the anterior gastric wall.

3.2.2. Laparoscopic-assisted percutaneous endoscopic gastrostomy

Using an open (Hasson technique) infraumbilical access, pneumoperitoneum was achieved and abdominal exploration was performed. If the abdominal cavity was adhesion-free, the original PEG procedure could be performed under gastroscopic and laparoscopic visual control. In case of adhesions, they were released with 3 mm instruments and then the gastrostomy tube was inserted with the conventional pull technique.

3.3. Laparoscopic-assisted ventriculoperitoneal shunt revision

A retrospective analysis of our hydrocephalus surgeries between January 2009 and December 2018 was performed. Subsequent revisions within 12 months, shunt infections, operative time, and hospital stay of laparoscopic versus open distal shunt revisions were compared in pediatric patients.

3.3.1. Open revision of distal catheter of VP shunt

The open procedure entailed a 2-3 cm long skin incision, which was made on the epigastrium above the obstructed distal catheter. The obstructed catheter was removed. When

the access through the muscles and peritoneum was free, the end of the catheter was directed into the pelvis with a pair of long forceps, blindly.

3.3.2. Laparoscopic-assisted revision of distal catheter of VP shunt

A camera port was inserted through an infraumbilical access with an open (Hasson) technique. Pneumoperitoneum was achieved by insufflating carbon dioxide and abdominal exploration was performed. Any adhesions or pseudocysts found could be released with laparoscopic instruments. Afterwards a 5 mm long epigastric incision was made, where the obstructed catheter was removed and the end of the new catheter was pulled into the abdomen and pushed into the pelvic cavity with laparoscopic forceps under direct visual control.

4. RESULTS

4.1. Laparoscopy in incarcerated inguinal hernia

In the English literature, 15 articles with n=689 incarcerated inguinal hernias were identified that met the inclusion criteria. The *age* distribution at the time of surgery was 2 weeks to 16 years with the median age being 22.4 months. *The male to female ratio* was 2.2:1. The *affected side* was reported in n=576 cases, with 69.1% (n=398) being right-sided and 30.9% (n=178) left-sided.

In n=355 cases (51.5%), manual reduction and delayed surgery (MRDS) was performed in 24-48 hours. In n=34 (4.9%) patients, manual reduction was possible only in general anesthesia (MRGA) followed by emergency LIHR. In n=300 cases (43.5%), the hernia content was reducible only intra-operatively (IOR) with laparoscopic instruments and external pressure.

During the intraoperative reduction, *incarcerated contents* were documented in 68 patients: intestine n=36 (52.9%), ovary n=14 (20.6%), omentum n=11 (16.2%), appendix n=5 (7.4%), and Meckel's diverticulum n=2 (2.9%). Among the 18 girls in the IOR group 14 (77.8%) had ovarian incarceration in the sac.

Hernia repair was achieved with two different surgical techniques. The *hook method* (extracorporeal) was used in n=376 (54.6%) and the *purse string suture* (intracorporeal) in n=313 (45.4%) patients. Two conversions were found in the IOR group: in one patient the reduction required release of the external inguinal ring, and in the other patient LIHR was hampered by a friable internal ring. *Mean follow–up time* was 15 months (3-80 months). During

the follow-up period, n=1 (0.15%) testicular atrophy was reported in the IOR group. *Recurrence* was found in 4 (0.58%) patients in the MRDS group and in one (0.15%) in the IOR group.

All 5 recurrences were found in the purse string technique group. The total recurrence rate was 0.73%. Recurrence was significantly higher (p=0.014) with Chi square test in the purse string group (n=5, 1.6%) than with the hook technique (n=0).

In the reviewed literature, 4 male patients required laparoscopic assisted bowel resections: n=2 small bowel gangrene, n=1 perforated Meckel's diverticulum and n=1 deep serosal tear of small bowel. Two partial omentectomies were performed laparoscopically and an oophorectomy in case of a necrotic ovary.

One testicular atrophy was mentioned after a late, difficult, instrument aided reduction. Umbilical granuloma was mentioned in 19 patients (4,8%). Other minor complications were detected in less than 1%, such as hydrocele (n=6), port site hernia (n=6), and trocar infection (n=3).

4.2. Laparoscopic-assisted percutaneous endoscopic gastrostomy

A total of 25 high-risk patients received PEG tubes between January 2014 and December 2019. Open, one-step and laparoscopic assisted gastrostomies were not included in this analysis. This retrospective study included 15 (60%) boys and 10 (40%) girls with a mean age of 70 months (2 and a half months - 17.5 years).

These 25 interventions in high-risk patients were divided into 2 groups. The first group of purely endoscopic visualization was composed of 15 patients (60%) who underwent the *original PEG* insertion with the pull technique. The second group of both endoscopic and laparoscopic control included 10 patients (40%) who underwent *L-PEG* placement.

The mean age in the first group was 71 months (2 and a half months - 17.5 years), *the boy: girl ratio* was 9:6. In the second group, the median age was 57 months (10 months -14 years) with 6 boys and 4 girls. *Indications* for gastrostomy in all cases were feeding difficulties or malnutrition.

Risk factors in the first group were n=7 severe TAD, n= 6 abdominal tumor (n=3 neuroblastoma, n=3 Wilms tumor) and n= 2 VP shunts. Risk factors in the second group were n=5 VP shunts, n=4 previous abdominal surgeries (duodenal atresia, previous gastrostomy, left nephrectomy because of Wilms tumor, tumor biopsy of rhabdomyosarcoma), and n=1 severe TAD. *Adhesions* were found in n=3 (30%) patients, and they were released laparoscopically. There was no need for *conversion*.

*The mean operating tim*e of the PEG procedure was 23 minutes (14-35 minutes) in the first group, compared to 46 minutes (32-80 minutes) necessary for the L-PEG procedure. Welch's two sample t-test found a significant difference between the length of the two procedures: L-PEG was significantly (p=0.001) longer than the original PEG, especially if adhesiolysis was necessary (60-80 minutes).

Refeeding was started 8 hours later with water, and formula was started 24 hours after the insertion in both groups. There were no significant differences in refeeding time between the two groups. Hospital stay depended on refeeding time and underlying diseases, not on the operative technique.

Adverse effects were classified as minor or major based on the ESPGHAN guidelines. *Minor complications* occurred in 2 patients (8%). A total of one minor complication was observed in the first group (n=1), which was unplanned removal of the tube (6.6%). The opening of the skin closed spontaneously after the unplanned removal and the internal fixation plate was emptied with the stool. In the L-PEG group there was n=1 peristomal granuloma (10%)

A total of 3 *major complications* were observed: they all occurred in the first group (20%). One transverse colon perforation, one gastrocolic fistula and one pneumoperitoneum were found in the first group. No major complication (0%) was observed in the second group.

There was n=1 *lethal outcome* in a patient with severe comorbidities, who died due to severe outcome of his general condition long after the postoperative period. He was in the 1st group; however, there was no association between the fatal outcome and the operation.

4.3. Laparoscopic-assisted ventriculoperitoneal shunt revision

A total of 140 HC surgeries were performed in 60 patients in our pediatric surgery department between January 2009 and December 2018. The minimum follow-up period was at least 1 year (1-10 years).

HC surgeries were performed in 38 boys and 22 girls. *The mean age* was 5.6 years (1 month - 21 years old). Out of all distal shunt revisions, n=55 were intraabdominal procedures.

Intraabdominal VP shunt revisions were divided into 2 groups: 28 laparoscopic revisions in 19 patients and 27 open revisions (20 open intraabdominal revisions, 7 VP shunt exchanges) in 19 patients. The *mean age* was 11.2 years (3 months - 21 years) in the laparoscopic group, and 8.5 years (3 months - 16 years) in the open group.

The number of *previous abdominal surgeries* was not significantly different in the two groups. In the open group, the number of previous abdominal surgeries varied between 1-8, and in the laparoscopic group between 1-9.

Traditional open procedures through mini-laparotomy offer only limited access to the peritoneal cavity. During laparoscopic revisions, n=7 extensive and n=3 localized adhesions and n= 4 pseudocysts were found and released.

In 3 cases, laparoscopy was particularly helpful in choosing the proper surgical management via evaluating the peritoneal cavity. In one patient, a ventriculovesical shunt was replaced with a VP shunt. In one boy, a ventriculoatrial shunt was performed after the direct inspection of the abdominal cavity and in another child laparoscopy was used to explore the abdominal cavity since the insertion of a new VP shunt was preceded by bowel perforation.

Shunt infection requiring externalization was detected in one patient in the laparoscopic group and in 2 patients in the open group.

The intraoperative time was not significantly different in the two groups. In the open group, the mean operative time was 28 minutes (13-86 minutes), and in the laparoscopic group it was 33 minutes (24-67 minutes).

Mean hospital stay was 7.2 days (2-65 days) in the open group and 6.6 days (2-46 days) in the laparoscopic group.

Subsequent abdominal revision within 12 months was necessary in 13 cases (48.1%) in the open group and in 6 cases (21.4%) in the laparoscopic group. The figures are significantly lower ($p=0.037$) with Chi-square test in the laparoscopic group. Chi-square test for independence was used. A p-value of $p<0.05$ was regarded as statistically significant. Statistical software IBM SPSS version 25 was also used.

5. DISCUSSION

5.1. Laparoscopy in incarcerated inguinal hernia

Incarceration is the severe complication of inguinal hernias, for which emergency treatment is necessary. After manual reduction, hernias can be repaired open or using minimal access techniques after 24-48 hours. Laparoscopic closure has the advantage of avoiding the difficult dissection of an edematous sac even days following reduction of incarceration, and it permits the repair of a contralateral patent processus vaginalis if present.

If general anesthesia is necessary for manual reduction, it is recommended to do emergency laparoscopy in the same session, because it allows inspection of the reduced hernia content.

Reduction of severely incarcerated contents can be done by a combination of retraction using laparoscopic instruments together with external manual pressure. Under direct visualization the degree of intestinal injury or gonad necrosis can be evaluated and laparoscopic treatment can be performed. Bowel necrosis due to strangulation or serosal tears resulting from the retraction force of laparoscopic instruments can be treated with intracorporeal suturing, or damaged intestine could be exteriorized through the single-incision LIHR for repair. Omentectomy, appendectomy, oophorectomy or Meckel's diverticulum resection can also be managed with MIS.

Only one testicular atrophy was documented in a male who underwent a late, difficult instrumental reduction. It can be hypothesized, that the development of testicular atrophy can be attributed more to the duration of incarceration and condition of testis, rather than the surgical technique employed.

Two conversions were documented: in the first case the releasing of the external inguinal ring was necessary, in the other case the LIHR was hampered by a friable internal ring.

In girls with irreducible hernia, the content of hernia is most commonly the ovary, which should be treated by laparoscopy, as soon as possible after they are detected.

Recurrence rate of LIHR after incarceration is as low as 0.78%, which is comparable with non-incarcerated hernias, however after open closure it is 15-20%. Hook and purse string methods are equally popular in LIHR, however recurrence is significantly higher with purse string suture than hook technique.

5.2. Laparoscopic-assisted percutaneous endoscopic gastrostomy

Tube feeding is the method of choice when enteral nutrition is recommended but oral intake is insufficient. After Gauderer first described PEG in 1980, this minimally invasive technique became the gold standard. Its advantages are less scarring, shorter operative time, less infections, less postoperative pain and shorter hospital stay. In most cases, PEG tube insertion is a safe procedure when the esophagus is patent and transillumination of the stomach through the abdominal wall is well achievable.

According to our literature review on complications of PEG insertions, the most common major complications after conventional PEG procedure were systemic infections in 3.5% and peritonitis, sepsis or wound dehiscence in 1.5%. Pneumoperitoneum was observed in

0.7%. Asymptomatic pneumoperitoneum can occur without intestinal perforation as a result of the procedure, however in 0.3% of the cases esophagus or bowel perforations were noticed. Gastrocolic fistulas due to interposition of the splenic flexure between the anterior abdominal and gastric walls were found in 0.45%. Buried bumper, intraabdominal bleeding and ileus were detected in 1%.

Impaired coagulation, severe ascites, peritonitis and local esophageal and general gastrointestinal obstructions are considered to be absolute contraindications. Severe kyphoscoliosis with interposed organs and distorted anatomy are relative contraindications. Laparoscopic guidance is recommended during PEG placement in patients with severe kyphoscoliosis, hepatomegaly, splenomegaly, extreme obesity or an intraabdominal tumor, as well as in patients with previous abdominal surgery.

In our institute, L-PEG was started in 2014 after a major complication in a patient with a VP shunt. Since then, all patients with a high risk of intestinal injury (VP shunts, PD catheters, previous abdominal surgery, severe TAD, hepatomegaly or intraabdominal masses) have been operated this way. Before this shift, the original PEG was performed in 15 high-risk patients: severe TAD (n=7), abdominal tumor (n=6) and VP shunts (n=2). There were 3 major complications: colon perforation (n=1), gastrocolic fistula (n=1) and pneumoperitoneum (n=1).

The colon perforation was found in a 2-year-old VP-shunt patient. The patient developed peritonitis on the 1st postoperative day. Laparotomy was performed and two perforation openings were found on the transverse colon, which were closed in double layer. The distal catheter of the VP shunt was temporarily externalized. The PEG was exchanged to a gastrostomy tube.

Gastrocolic fistula was found in a 3-year-old boy with Fallot- tetralogy, severe TAD and somato-mental retardation. The internal bumper was removed endoscopically and the chronic fistula was closed surgically.

One case of pneumoperitoneum was caused by early dislodgement of the tube, because it was moved in the early postoperative period by an autistic patient with severe TAD. Gastropexy was performed with laparoscopic exploration. This complication was independent from the surgical technique and even from the patient’s high risk status.

After selection for high-risk patients was started, 10 L-PEGs were inserted; the indications for laparoscopic guidance were VP shunts (n=5), previous abdominal surgeries

(n=4) (duodenal atresia, previous gastrostomy, left nephrectomy because of Wilms tumor, tumor biopsy from rhabdomyosarcoma), and severe TAD (n=1). Adhesions were found in three patients (30%); two of them had a VP shunt and one had previous gastrostomy.

The advantage of L-PEG is that surgeons and endoscopists perform the same procedure as usual and there is no need to learn a new technique. The endoscopist performs the original pull technique. The surgeon performs the umbilical access in the same way as in any laparoscopic procedure for a 5 mm camera port. We prefer the open, Hasson technique instead of the Veress needle to prevent vessel-, hepatic- or bowel injury. Any adhesions found can be released laparoscopically. When the stomach is free of adhesions, the original PEG procedure can be performed under double visual control. The laparoscopic procedure is longer but safer than the pure endoscopic insertion not only in high-risk patients, but in all patients as well.

5.3. Laparoscopic-assisted ventriculoperitoneal shunt revision

VP shunt is the treatment of choice for HC of various origin; however, complication rates are considerably high. VP shunt dysfunction varies between 11–25% within the first year after initial shunt placement. The most common complication of VP shunts is obstruction. Traditional open procedures through mini-laparotomy for distal revision offer limited access to the peritoneal cavity. In the event of extensive abdominal adhesions this procedure will result in only a short complication-free period as we have experienced among our patients. The introduction of laparoscopic shunt revisions (N=10 laparoscopic release of extensive adhesions and n=4 excision of pseudocysts) has resulted in longer shunt survival. In 3 patients, laparoscopy was performed to help decision making, as evaluation of the abdominal cavity for sufficient absorbing surface or local inflammation can affect shunt survival.

In a 16-year old male patient with multiple previous revisions, a ventriculovesical shunt was performed due to extensive abdominal adhesions. After the patient developed bladder stones around the shunt, revision was necessary. Following laparoscopic adhesiolysis, the VP shunt was re-formed successfully and no more distal revision has been necessary in the past 10 years.

A distal shunt catheter penetrated the colon and appeared in the anus of an asymptomatic 9-month old girl. After 2 weeks of externalization and antibiotic therapy, laparoscopy found a healed perforation site on the colon and a new VP shunt was inserted into another part of the abdominal cavity under laparoscopic control. She has been complication-free for 8 years.

During a laparoscopic revision, there was no free abdominal cavity in a 14-year old boy due to dense adhesions in all parts of abdomen because of previous inflammation. In the 2nd step, a ventriculoatrial shunt was inserted. The patient has been symptom-free for 6 years.

In hydrocephalic patients, most authors report a significantly higher number of shunt revisions and replacements among pediatric patients compared to adults. Laparoscopic assistance can help not only with proper adhesiolysis and excision of pseudocysts, but also with decision making when choosing another surgical management. In VP shunt patients, our aim is to achieve the longest complication-free period possible.

6. CONCLUSION

6.1. Laparoscopy in incarcerated inguinal hernia

LIHR is highly recommended for incarcerated hernias because of its advantages in the reduction of irreducible hernias with pneumoperitoneum and in pulling the content of the sac with laparoscopic instruments. The inguinal hernia can be closed immediately with any LIHR technique (hook or purse string methods), with a much lower risk of injuring the vas or vessels compared to open procedures. If intestinal injuries, gonadal necrosis or Meckel's diverticulum are visible, they can be treated immediately with laparoscopic instruments. Recurrence rate is low and comparable with that of non-incarcerated hernias; however, it is significantly higher with the purse string suture than with the hook technique.

6.2. Laparoscopic-assisted percutaneous endoscopic gastrostomy

Our results show that the rate of major complications in high-risk patients is lower with L-PEG; however, the operative time is significantly longer, especially if adhesiolysis is necessary.

Laparoscopic guidance provides a clear intraabdominal view, offers the possibility of releasing adhesions, thus adjacent bowel or hepatic injuries can be prevented. L-PEG is advised for children with distorted anatomy, VP shunts or previous abdominal surgeries. L-PEG can provide an immediate solution if transillumination of the gastric wall is inappropriate during gastroscopy. PEG insertion for high-risk patients is advised in centers with pediatric surgical departments, where laparoscopy is routinely used.

6.3. Laparoscopic-assisted ventriculoperitoneal shunt revision

VP shunts are the first line treatment of HC; however, revisions are frequently necessary. Distal shunt revisions can be performed both in an open and laparoscopic way. The most important advantages of laparoscopy are the possibility of releasing adhesions, fenestration of CSF pseudocysts and visually controlled insertion of the new catheter into the abdominal cavity. Laparoscopy can facilitate the diagnostic evaluation of the peritoneum, thereby helping in decision making regarding surgical management. As a result, significantly fewer new abdominal revisions are necessary in the first postoperative year.

6.4. Summary of new findings

1. **Laparoscopic procedure is effective in the treatment of irreducible incarcerated inguinal hernias in children. Laparoscopy can help not only in the reduction, but also in the repair of the inguinal hernia in one session.**

2. **Laparoscopic assistance during PEG insertions can reduce the rate of intraoperative complications in high-risk patients with distorted anatomy or previous abdominal surgery.**

3. **Laparoscopic assistance during intraabdominal VP shunt revisions can significantly reduce the number of subsequent abdominal revisions, and in special cases, laparoscopic findings can help in the selection and timing of the most appropriate technique for VP shunt insertion.**

ACKNOWLEDGEMENTS

First and foremost, I wish to express my gratitude to **Dr. Tamás Kovács** for his constant support and encouragement along the scientific process and for the supervision of this manuscript.

I would like to offer my special thanks to **Prof. Kristóf Füzesi** for his inspiration in my work and for the ongoing support.

I am also grateful to **Prof. Amulya K. Saxena**, who gave me a head start in scientific publications and made me feel completely part of his staff during my stay in London.

I am obliged to all my colleagues for their support in my everyday work at **the Division of Surgery, Department of Pediatrics, University of Szeged**. Without them this work would never have been completed.

Last but not least, I would like to express my gratitude to my family for their support and understanding.