

Individualized Surgical Management in the Head and Neck Region

Zoltán Lóderer, MD

Department of Oral and Maxillofacial Surgery, University of Szeged

PhD Thesis

Szeged

2019

LIST OF PAPERS RELATED TO THE SUBJECT OF THE THESIS

- I. László I, Janovszky Á, Lovas A, Vargán V, Öveges N, Tánzos T, Mikor A, Trásy D, **Lóderer Z**, Piffkó J, Szabó A, Molnár Z. Effects of goal-directed crystalloid vs. colloid fluid therapy on microcirculation during free flap surgery: A randomised clinical trial. Eur J Anaesthesiol. 2019;36(8):592-604. doi: 10.1097/EJA.0000000000001024. **Q1, IF: 4,14**
- II. **Lóderer Z**, Vereb T, Paczona R, Janovszky Á, Piffkó J. An anterolateral thigh chimeric flap for dynamic facial and esthetic reconstruction after oncological surgery in the maxillofacial region: a case report. Head Face Med. 2018;14(1):7. doi: 10.1186/s13005-018-0164-6. **Q1, IF: 1,492**
- III. **Lóderer Z**, Janovszky Á, Lázár P, Piffkó J. Surgical Management of Progressive Hemifacial Atrophy With De-Epithelialized Profunda Artery Perforator Flap: A Case Report. J Oral Maxillofac Surg. 2017;75(3):596-602. doi: 10.1016/j.joms.2016.10.020. **Q1, IF: 1,779**

TABLE OF CONTENTS

LIST OF PAPERS RELATED TO THE SUBJECT OF THE THESIS	2
TABLE OF CONTENTS	3
SUMMARY OF THE THESIS	5
1. INTRODUCTION.....	6
1.1. Head and neck oncology.....	6
1.1.1. Ethiopathogenesis and risk factors.....	6
1.1.2. Diagnosis and staging	11
1.1.3. Management.....	12
1.2. Functional and aesthetic aspects after resective oncological treatment - possibilities for the reconstruction of tissue defect in head and neck region	13
2. MAIN GOALS	14
3. MATERIALS AND METHODS.....	15
3.1. Microcirculatory investigation of radial forearm free flaps	15
3.2. Case 1.....	16
3.3. Case 2.....	17
4. RESULTS.....	19
4.1. Microcirculatory investigation of radial forearm free flaps	19
4.2. Case 1.....	21
4.3. Case 2.....	26
5. DISCUSSION.....	31
5.1. Commonly used free flaps for the reconstruction of the head and neck region	31
5.2. Individualized planning during the reconstructive surgical management in the head and neck region.....	33

6. CONCLUSIONS	40
7. SUMMARY OF NEW FINDINGS.....	42
8. ACKNOWLEDGEMENTS	43
9. REFERENCES.....	44
Appendix I.	53
Appendix II.....	54
Appendix III.....	55

SUMMARY OF THE THESIS

The surgical management of malignant tumors or in the head and neck region often leads to functional and esthetic defects that impair the quality of life of the patients. Reconstruction can be solved with prostheses in these cases, but various types of microsurgical free flaps can provide a better clinical outcome. Not only head and neck cancer and related surgical interventions, but also trauma and congenital cranio-maxillofacial deformities can result in appearance, which may impair the socialization or social integration of the patient. These special cases indicate special consideration and surgical techniques. The aim of the current thesis is to present the importance of the individualized surgical management through special cases.

1. INTRODUCTION

1.1. Head and neck oncology

1.1.1. Etiopathogenesis and risk factors

The development of tumorous lesions is initiated with chronic particular environmental or lifestyle habits, inducing irreparable DNA damage. The DNA damage causes an imbalance in the regulation of cell cycle, and overexpression of tumor-promoter oncogenes and suppression or inactivation of tumor-suppressor genes can be observed. These processes lead to uncontrolled cell proliferation, development of malignant neoplasm, and consequently invasion and metastasis into remote organs (Figure 1.).

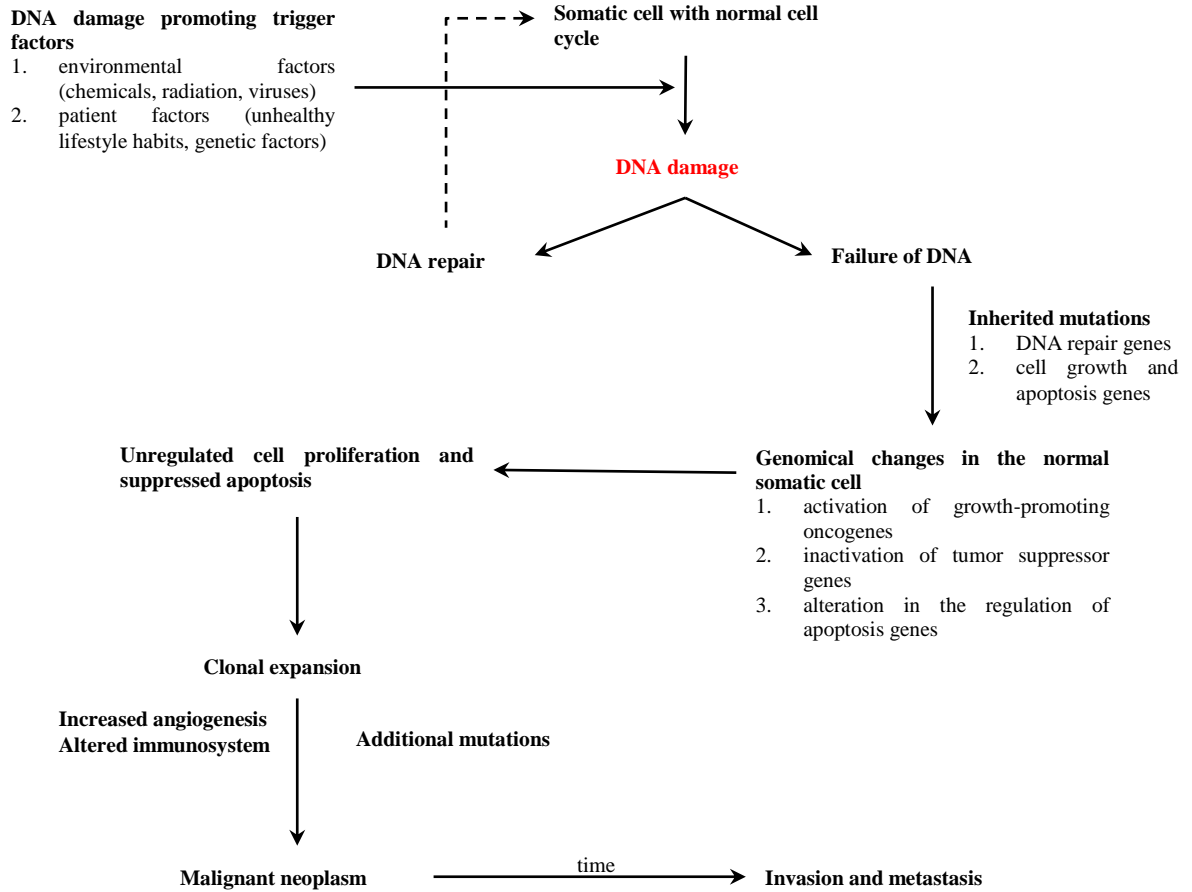


Figure 1. Progression of malignant tumor

Excessive smoking and alcohol consumption are the most common trigger factors of head and neck cancers. However, particular viral infection and genetic factors also contributes to the development of oral malignancies [Beynon RA 2018].

Risk factors of head and neck cancer	
Primary risk factors	Secondary risk factors
<ol style="list-style-type: none"> 1. smoking and smokless tobacco (e.g. betel quid or snuff) 2. alcohol 3. Human papillomavirus 	<ol style="list-style-type: none"> 1. premalignant lesions (e.g. leukoplakia) 2. immunosuppressive conditions (e.g. HIV) 3. diet 4. oral hygiene 5. radiation and sun exposure 6. Plummer-Vinson syndrome, Li Fraumeni syndrome 7. Fanconi anaemia 8. dyskeratosis congenita

Table 1. The most common risk factors of head and neck cancers

Smoking

Smoking is the main trigger factor of oral malignancies, while alcohol can synergistically increase the risk of these tumors. Based on international public health and literatura data, the majority of patients with head and neck cancer has a history of smoking [Blot WJ 1988, Hashibe M 2007, Rettig EM 2015, Kumar M 2016], increasing the risk of oral cancers with four-fold to ten-fold [Vineis P 2004]. The carcinogenic effects of smoking are dose-dependent, the frequency, duration, and intensity of this unhealthy lifestyle habit have an influence on the risk of head and neck cancer [Blot WJ 1988, Hashibe M 2007, Rettig EM 2015]. Interestingly, there is evidence that risk of oral malignancies can reduce not only by smoking cessation, but with increasing time since smoking cessation

[Franceschi S 1990, Gupta PC 1995, Schlecht NF 1999, Rettig EM 2015]. Aromatic hydrocarbon benz-pyrene and the tobacco-specific nitrosamines (4-(nitrosomethylamino)-1-(3-pyridyl)-1-butanone and N'-nitrosornicotine) are responsible carcinogens, and their metabolites can covalently bind with DNA of keratinocyte stem cells forming DNA adducts, inducing critical mutations in DNA replication. The above mentioned carcinogens are metabolized by P450 enzymes in cytochromes and conjugation by glutathione-S-transferase. Genetic polymorphisms related to these enzymes may play a role in the genetic predisposition to smoking-induced head and neck cancers [Warnakulasuriya KA 1999, Kumar M 2016].

Alcohol

Excessive alcohol consumption independently increases the risk of oral malignancies, but the larger impact can be observed in the interaction of alcohol with smoking, increasing the risk of oral malignancies with even a greater than 35-fold [Blot WJ 1988, Hashibe M 2009, Rettig EM 2015, Kumar M 2016].

Gender, age, and race

According to international statistics and epidemiological data, HNCs show a higher incidence among men, than women worldwide, which can be explained with the higher rates of substance abuse, such as tobacco or alcohol use [Simard EP 2014, Thun M 2012]. Previously the risk showed an increased tendency with age (60-70 years), however because of the changed lifestyle habit and human papillomavirus infection oral malignant tumors can also develop in younger population (30-40 years) [Lewis A 2015, Young D 2015]. According to the National Cancer Institute data, the incidence of HNCs has been higher among blacks than whites, while nowadays has been declining, and is currently lower than

in whites (age-adjusted incidence rate of all HNCs is 14.8 per 100,000 for blacks compared with 15.5 per 100,000 for whites) [<https://seer.cancer.gov/statistics/>]. The incidence can be explained partially by rising incidence of HPV infection among white population, which was not observed among black patients [Chaturvedi AK 2011, Fakhry 2017, Peterson CE 2016, Settle K 2009].

Immune suppression

Organ transplantation or HIV infection related immuno-suppressive state are associated with a higher risk of HNC. Several studies showed, that the incidence of lip cancer may increase by 10-fold after organ transplantation, while 2- to 5-fold increases can be revealed at other regions of head and neck. By 2- to 5-fold, HIV infection can also increase the risk of the development of head and neck cancers. This higher incidence correspond with the initiation of highly active antiretroviral therapy resulting in longer survival of patients and the possibilities to develop non-AIDS-defining malignancies [Agaimy A 2018, Picard A 2018].

Risk Factors for Human Papillomavirus-Positive Head and Neck Cancer

HPV is a sexually transmitted infection that may cause HPV-positive HNC (HPV-HNC), a special subgroup of head and neck cancers occurring predominantly in the oropharyngeal region. This special subgroup shows a growing incidence, and the oral HPV infection is the putative precursor to HPV-induced head and neck cancers. Only high risk or carcinogenic HPVs, HPV-16 in the vast majority, can be associated with oropharyngeal malignant tumors, however, the vast majority of infections do not progress to HPV-induced head and neck cancers [Vokes EE 2015].

1.1.2. Diagnosis and staging

Detailed clinical history and following the methodology of the current guideline for the diagnosis of HNC are indispensable in a good clinical practice. Accurate staging is crucial for determining the appropriate and individualized therapeutic management. The following staging process is recommended in HNCs:

1. clinical history and physical examination (with special emphasis of the head and neck region, involving endoscopic examination)
2. histological staining
 - a. primary tumor biopsy or
 - b. lymph node puncture for cytological staining
 - c. HPV determination in oropharynx and oral cavity tumors
3. radiological imaging
 - a. cervical computed tomography (CT) +/- contrast agent or magnetic resonance (MR).
 - b. chest imaging (X-ray) or computed tomography (CT) with contrast agent
 - c. esophageal-gastric contrast study or esophagoscopy in case of dysphagia
 - d. positron emission tomography (PET) for stage III–IV disease (patients with definitive treatment intention and high risk of metastases)
4. functional study
 - a. swallowing
 - b. phonation
 - c. breathing

- d. odontology
 - e. nutritional status
5. special aspects
- a. psychological and social situation
 - b. prevention and cessation of cigarette smoking or alcohol dependence, etc.

The TNM classification is an internationally accepted system for tumour staging. Stage at diagnosis predicts survival rates and guides management. The eighth edition of TNM classification was published in January, 2017. The main changes to the seventh edition are the following:

1. separate classification for p16-positive oropharyngeal tumours, and N category has been reclassified
2. T category (T1–T3) of lip and oral cavity includes the extent of depth invasion, and N3 category has been subdivided into N3a and N3b according to extranodal extension

The overall stage of the tumour is complete with the definition of the presence (M0) or absence (M1) of distant metastasis [Iglesias Docampo LC 2018, NCCN guideline].

1.1.3. Management

Treatment depends on primary tumour location and extension. A multidisciplinary professional team, so called onco-team, should decide the potential treatment option for each patient. Surgery and radiotherapy (RT) (external or brachytherapy) may provide similar locoregional control and survival outcomes, however, these modalities have not been compared in randomized trials. Several aspects, such as functional outcome, the

possibility of an adequate follow-up, the patient's general condition, may influence the choice of treatment modality or the likelihood of developing a second primary tumour.

Surgical intervention is the preferred option for HNCs and involves resection of tumor with an appropriate safety margin and subsequent reconstruction, completing with neck dissection in certain cases. Sentinel lymph node biopsy may be indicated for small cancers to avoid morbidity. In case of locally advanced disease, it has to be determined whether the lesion is resectable or not. There is no an accepted definition of unresectability, but certain anatomical localizations are considered indisputable, such as involvement of skull base, cervical vertebrae, prevertebral muscles, brachial plexus, mediastinal spread, nasopharynx, or fixed tumour to collarbone. Furthermore, the surgical team should be considering, that satisfactory outcome can only be achieved with appropriate patient selection and indication. Before the initiation of the therapy, the patient's nutritional status must be corrected and maintained, and dental rehabilitation is indicated before radiotherapy [NCCN guideline].

1.2. Functional and aesthetic aspects after resective oncological treatment - possibilities for the reconstruction of tissue defect in head and neck region

The reconstructive surgeon should be familiar with all aspects of the reconstructive ladder, which a conventional well-adaptable guidance during planning and surgical reconstruction. In general - aside from some small or superficial defects - free flaps should be the first choice during reconstruction of large or composite defects involving bone, soft tissue, and skin of the head and neck. The reconstructive ladder is not linear, different techniques can be combined, and patient's factors should be also considered. Radial forearm and fibula free flaps are the most commonly used free tissue flaps in the head and

neck reconstruction. However, the surgeon should have the possibility of choosing from a wider armamentarium instead of being forced to apply these most frequently used flaps to solve a surgical situation in the head and neck region.

2. MAIN GOALS

The main goals of our clinical investigation were to optimize and to individualize the patient care at Department of Oral and Maxillofacial Surgery, and to examine the microcirculatory dynamics of radial forearm free flaps.

3. MATERIALS AND METHODS

This clinical investigation (Ethical Committee No. 44/2014) was undertaken between April 2014 and February 2018 and was approved by the Regional and Institutional Human Medical Biological Research Ethics Committee, University of Szeged, Hungary on 28 April 2014. The investigation was performed at the University of Szeged. The study was registered at ClinicalTrials.gov with the registration number: NCT03288051. Written informed consent was obtained from all participants. Adult patients of both sexes undergoing radical forearm free flap surgery were recruited. Exclusion criteria included vulnerable individuals as defined in ISO 14155: 2011, pregnant or lactating women, and end-stage oral cancer.

3.1. Microcirculatory investigation of radial forearm free flaps

All flaps were monitored with non-invasive laser-Doppler flowmetry (PeriFlux 5000 LDPM; Perimed, Jarfalla, Sweden) intraoperatively, and postoperatively. A probe with a standard fibre separation of 0.25 mm, and a 780 nm wavelength laser was used. The depth of the measurements was 0.5 to 1 mm. Results are expressed as perfusion units. The first measurements were taken after the flap was prepared (Rbs1), then 1 h after reperfusion and continued hourly for up to 12 h (R1–R12). The probe was placed and fixed in a position in the centre of the forearm flap skin island. The skin in the deltoid region provided the control site. At both places, measurements were taken after active warming of the skin, at 35°C and 44°C. Data were recorded for more than 2 min at each measurement point. Quantitative assessment of the recording periods was performed off-line.

3.2. Case 1

A third relapse of basal cell carcinoma was confirmed by histology in the left midfacial region of a 42-year-old patient (Figure 2A). The preoperative CT imaging demonstrated that the tumor invaded the maxillary sinus, the orbital floor and the surrounding soft tissues,

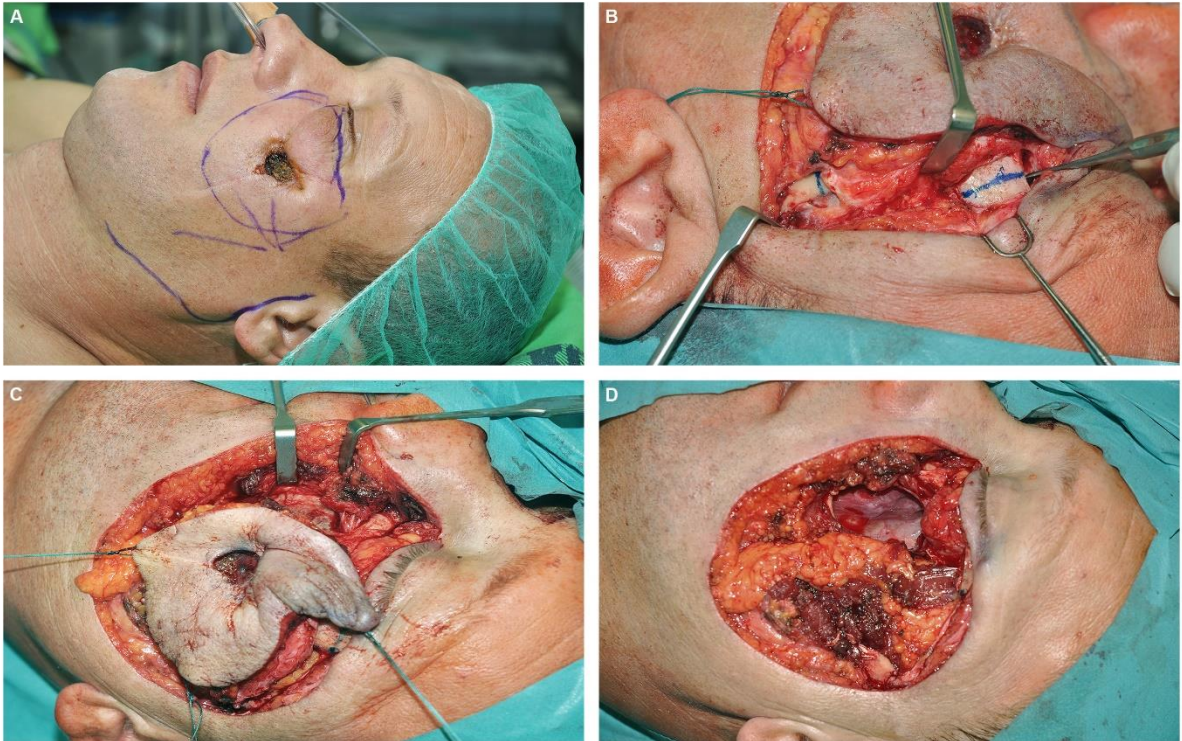


Figure 2. Preoperative appearance of the basal cell carcinoma in the left midface (A) and theradical tumor resection procedure (B-D)

e.g. facial skin, the subcutaneous tissue and the mouth elevator muscles (Figure 3). The resection results in an extended tissue defect, consequently reconstructive surgical difficulty.

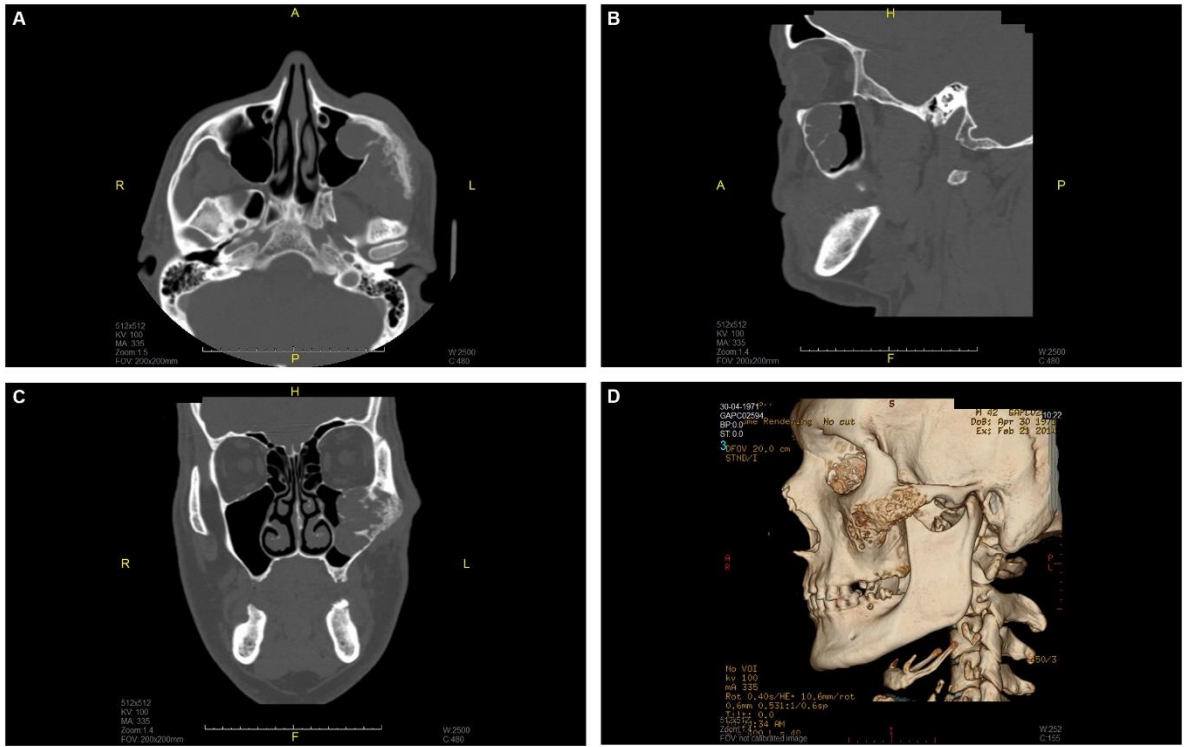


Figure 3. CT scans in coronal (A), sagittal (B) and axial (C) views and 3-dimensional reconstruction in a lateral view (D)

3.3. Case 2

A 21-year-old female patient with progressive haemifacial atrophy causing a substantial facial asymmetry (diagnosed when she was 5 years old) presented to our clinic in 2015. Physical examination showed extensive alopecia, localized hyperpigmentation,

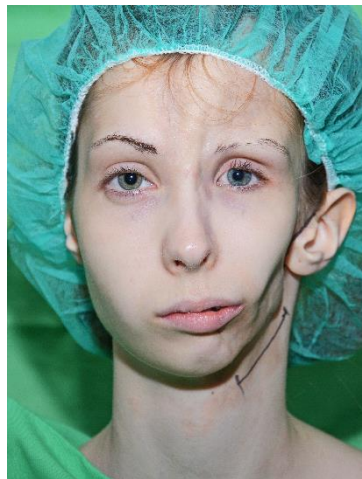

Figure 4. Preoperative appearance of the patient

and severe atrophy of the skin and the underlying subcutaneous tissues on the left side of the face between the zygomatic arch, body of the mandible (affecting the left submental region), nasolabial fold, and ear (Figure 4). The mimic muscles were not involved. Radiologic investigation showed bone involvement of the body of the mandible; however, relatively stable occlusion was observed (Figure 5). The main complaint of the patient was

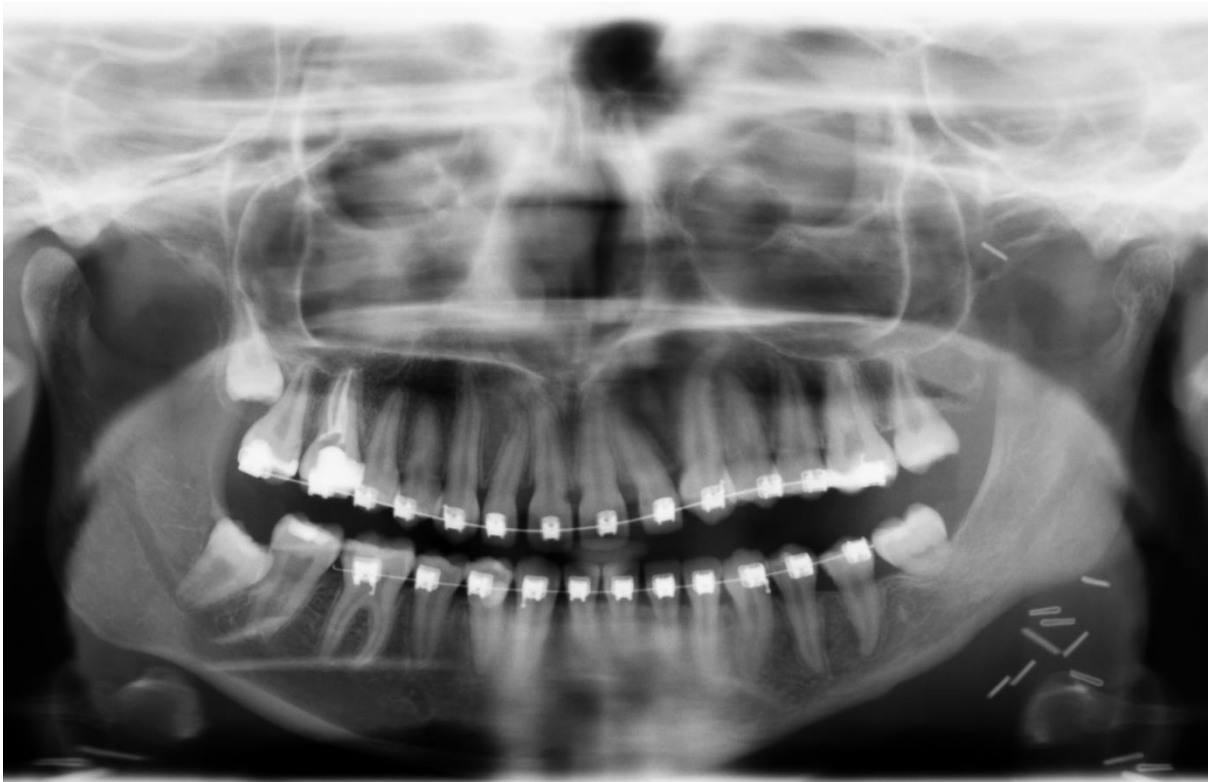

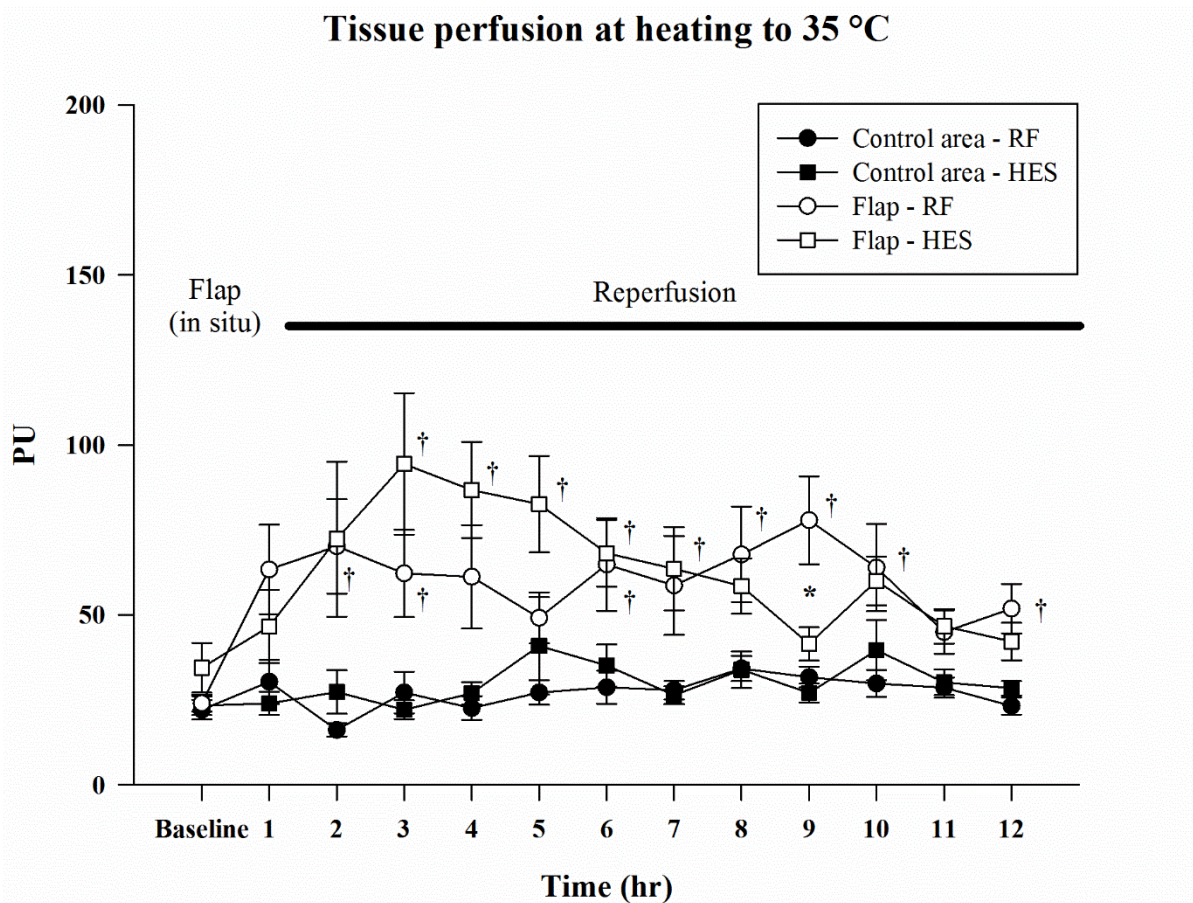
Figure 5. Orthopantomogram image of the patient

severe facial asymmetry that substantially influenced her social interactions.

4. RESULTS

4.1. Microcirculatory investigation of radial forearm free flaps

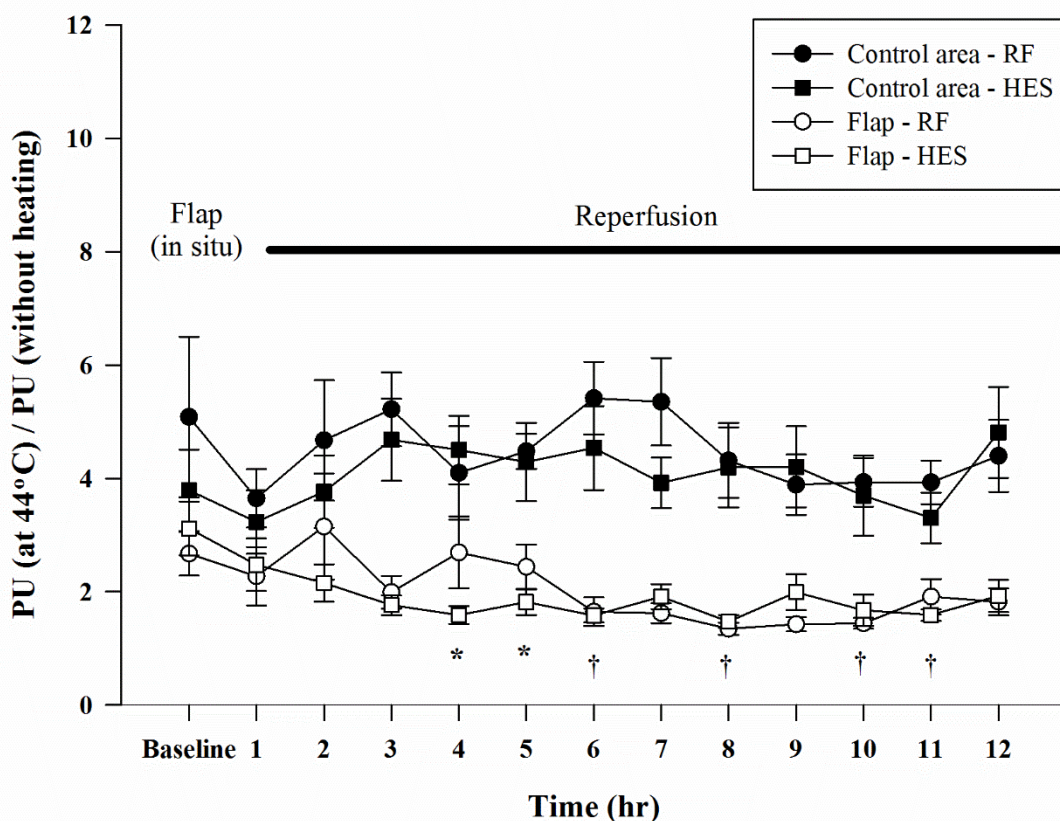
As evidenced by laser-Doppler flowmetry, baseline perfusion values were similar at the flap areas (in situ, before harvesting) and at the control sites (at 35°C and 44°C) (Figures 6 and 7). During reperfusion, however, significantly higher tissue perfusion values



*Figure 6. Perfusion is expressed as the ratio of the perfused units at 44°C/PU without heating (i.e. at original temperature). The figure shows tissue perfusion on heating to 35°C in the forearm flap and at the control area (skin at the deltoid region) in the crystalloid (RF) and colloid (HES) treated patients at different time-points of the study. Recordings were taken when the flap was prepared (Rbsl), 1 h after reperfusion and continued hourly for up to 12 h. Data are presented as mean SD. *P < 0.05 significant difference between groups. † P < 0.05 vs. Rbsl*

were observed at the free flap sites than those observed at baseline or at the control areas

Effect of heat provocation



*Figure 7. Perfusion is expressed as the ratio of the perfused units at 44°C/PU without heating (i.e. at original temperature). The figure shows the effects on perfusion at the control site (skin at the deltoid region) and in the forearm flap in the crystalloid (RF) and colloid (HES) treated patients at different time-points. Recordings were taken when the flap was prepared (Rbsl), 1 h after reperfusion and continued hourly for up to 12 h. Data are presented as mean SD. *P < 0.05 significant difference between groups. † P < 0.05 vs. Rbsl.*

(at corresponding time-points) at 35°C (Figure 6). Heat provocation (to 44°C) induced increases significantly in tissue perfusion only at the control areas, whereas this effect was missing in the flaps during reperfusion (Figure 7). In some cases, where circulatory failure of the flap developed, the venous or arterial thrombosis can be differentiated with the oscillation pattern registered by laser-Doppler flowmetry. The primary clinical study aimed to investigate the effects of goal-directed crystalloid or colloid fluid therapy on microcirculation during free flap surgery, however it is not the subject of this thesis.

4.2. Case 1

Radical tumor resection combined with partial maxillectomy and wide peritumoral soft tissue resection was performed. The marginal mandibular branch of the facial nerve could be salvaged, but the zygomaticobuccal branches of the mimetic muscles were ablated due to their infiltration by the tumor. The zygomaticus major and minor, levator anguli oris, levator labii superioris and buccinator muscles were resected (Figure 2B-D).

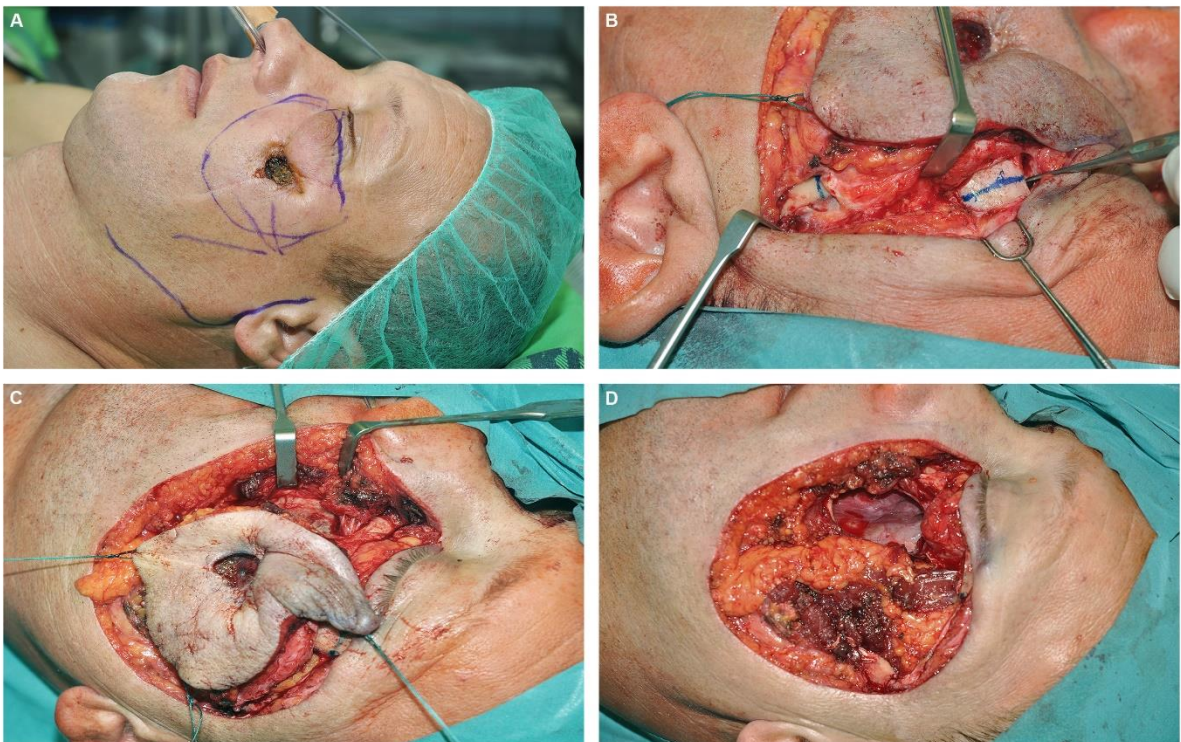


Figure 2. Preoperative appearance of the basal cell carcinoma in the left midface (A) and theradical tumor resection procedure (B-D)

Following partial maxillectomy, the orbital floor was reconstructed with a titanium mesh (Titanium Contourable Mesh Plates, malleable, 1.3 mm, Synthes Medical Hungary, Budapest, Hungary). In parallel with the tumor resection, a chimeric type I ALT fasciocutaneous and a vastus lateralis muscle segment flap were harvested on the left thigh (Figure 8) [4]. Both were supplied by a perforator of the descending branch of the lateral circumflex femoral artery. The segmental branch of the femoral nerve innervating the

selected muscle segment was identified by use of a bipolar electric stimulator (Aesculap

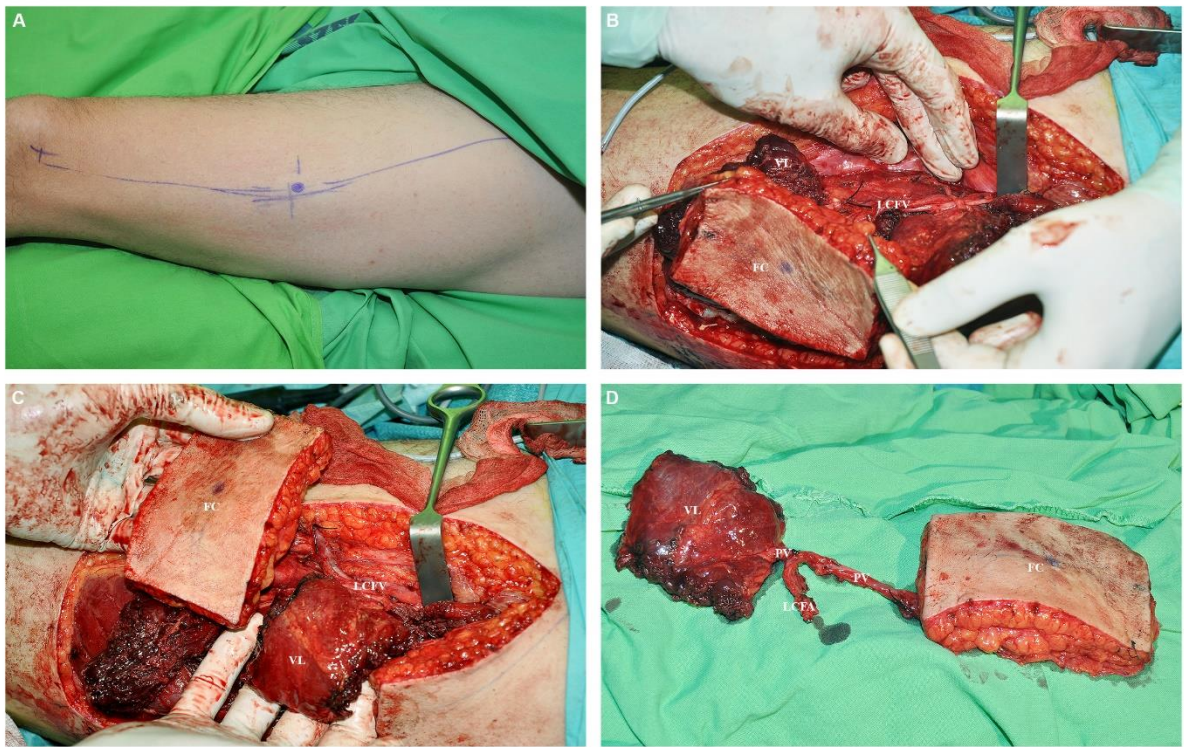


Figure 8. Marking of the surgical site and the perforator vessel on the left thigh (A). Raising of the chimeric type I anterolateral fasciocutaneous (FC) and vastus lateralis muscle segment (VL) flap with the circumflex femoral vessels (LCFV) (B, C), and the segmental branch of the femoral nerve and perforator vessels (PV) (D)

GN015, B. Braun Melsungen AG, Melsungen, Germany) and was prepared under an

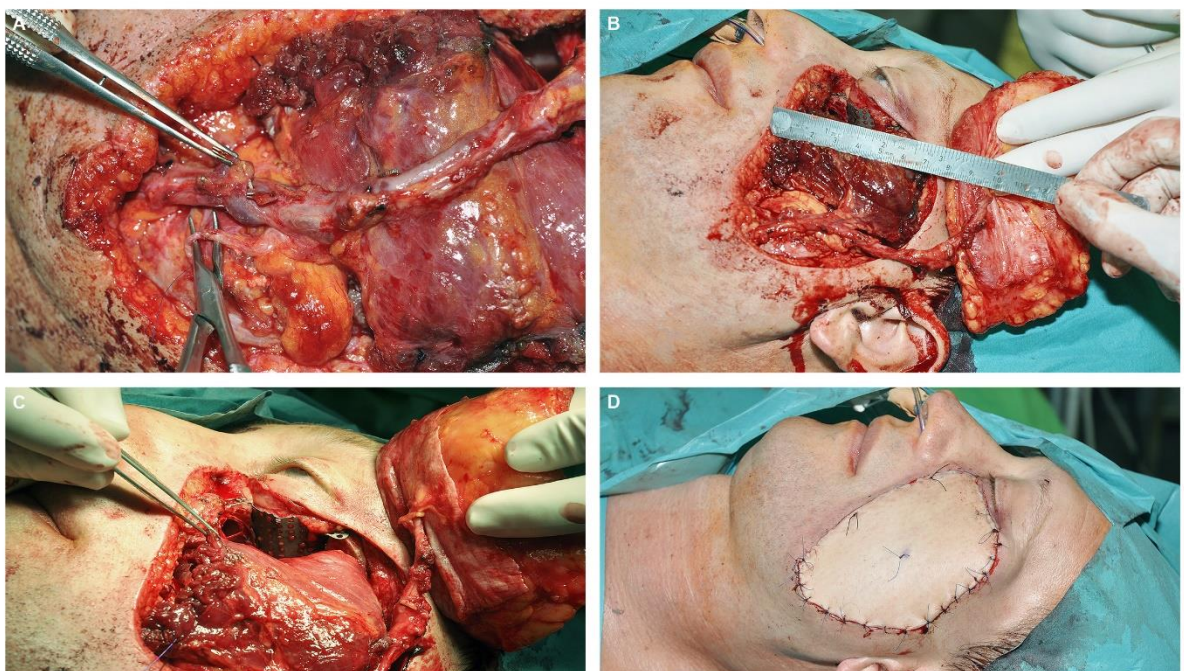


Figure 9. Blood vessel and nerve anastomoses on the recipient side (A), the flap position (B, C), and the state directly after the surgical reconstruction (D).

operating microscope (HEZ 2429, Möller-Wedel GmbH & Co. KG, Wedel, Germany) by intraneural dissection in the nerve trunk in order to gain more nerve length. The vastus lateralis muscle was dissected and sectioned, providing an appropriate length with which to substitute the mouth corner elevators. The chimeric type I flap was transplanted onto the midfacial defect (Figure 9). The vastus lateralis muscle segment was fixed to the modiolus and temporal fascia with 2.0 monofilament, absorbable interrupted sutures (PDS®, Ethicon, One Johnson & Johnson Plaza, New Brunswick, New Jersey, USA). Vessel anastomoses were created between the left facial and left circumflex femoral arteries, and the left facial and left circumflex femoral veins. Dynamic functional reconstruction of the region was attempted by co-aptation of the motor nerve of the muscle and the previously selected buccal branch of the facial nerve. 9.0 monofilament, non-absorbable (Prolene®, Ethicon, One Johnson & Johnson Plaza, New Brunswick, New Jersey, USA) interrupted

sutures were applied to anastomose the above arteries and nerves, and two half running sutures in venous anastomosis. The perforator artery was signed with a stitch to allow observation of the perfusion with a hand-held Doppler probe. The recipient and donor site

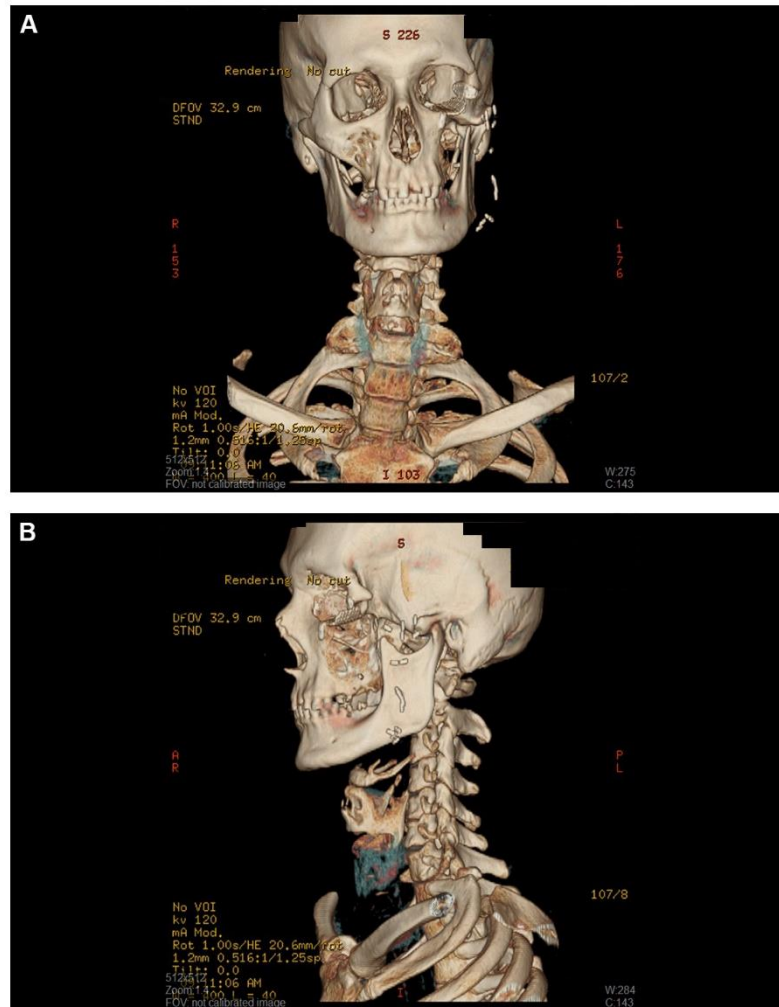


Figure 10. The tumor-free status revealed by CT 6 months after the operation.

were closed primarily. During the regular follow-up (monthly for 6 months), possible complications (such as bleeding, wound healing failure, or abscess formation) and functional improvements were checked. Histological examination revealed basal cell carcinoma infiltrating the muscular and bony tissues and nest formation with palisaded tumor cells at the periphery. The histological sample indicated R0 resection with a wide tumor-free surgical margin. The subsequent CT imaging confirmed successful resection of the basal cell carcinoma with no tumor recurrence or pathological accumulation of contrast

agent (Figure 10). A salivary fistula proceeding from the parotid gland was found and

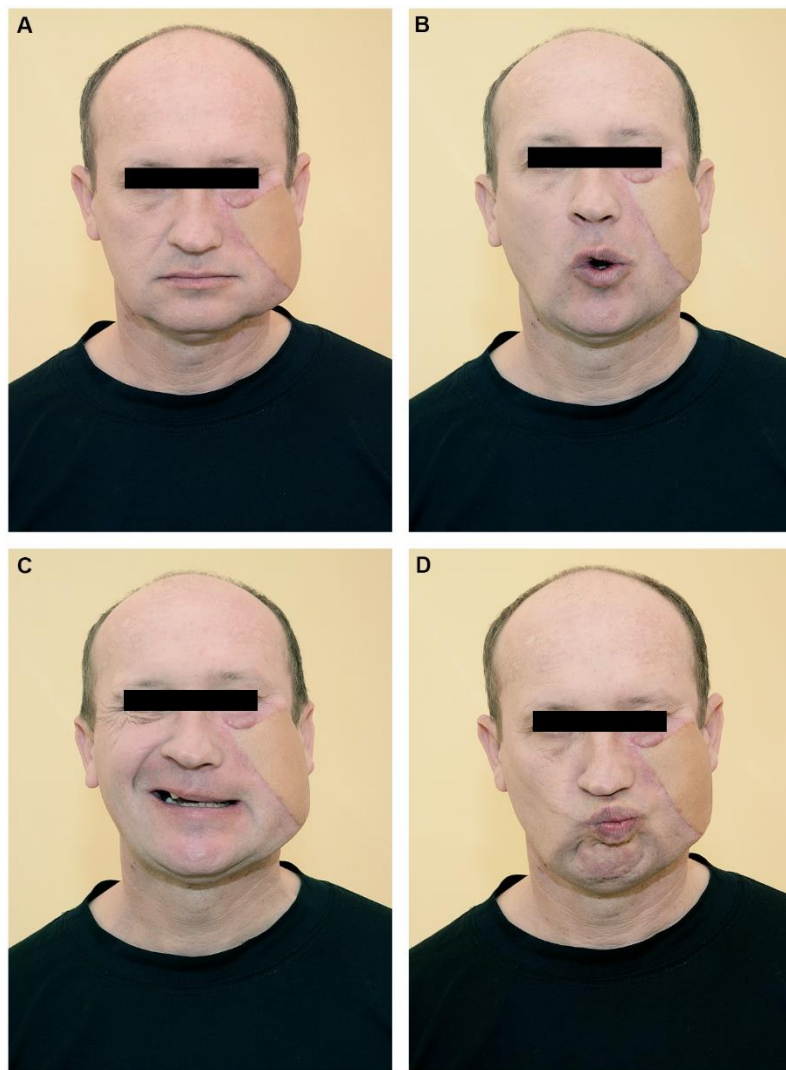
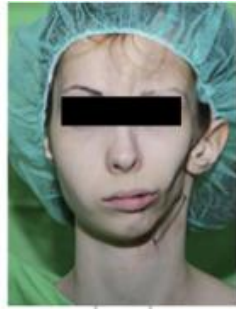

Figure 11. Esthetic appearance of the patient (A) and the function of the restored facial nerve 6 months after the surgical intervention (B-D).

treated on an outpatient basis. Positional facial asymmetry was not observed in a standing or calm position. Certain functions of the mimetic muscle (such as lip rounding) returned, but ability to elevate the left corner of the mouth remained far below that on the intact side 6 months after the surgical management (Figure 11).

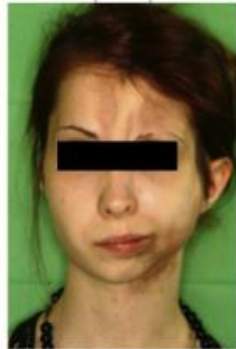
4.3. Case 2

Soft tissue reconstruction was planned, first with free flap and then with contingent autologous lipotransfer to replace the facial deformity, defect, and tissue loss. At the same time, orthodontic treatment was started for the preparation of a further bimaxillary osteotomy. Considering the thin body type and the expectations of the patient and comparing all reconstructive possibilities, we decided on a profunda artery perforator



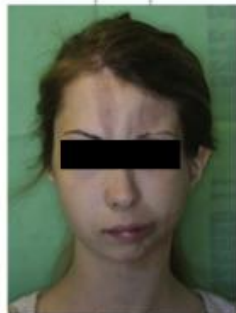1. Asthenic body type
 - not enough fatty tissue
 - not appropriate flap thickness
2. Expectations of the patient
 - non-visible scar
 - reduction of facial asymmetry

**Before the surgery in May 2015
(orthodontic treatment started)**



No complications after the surgery
Submental lipofilling and flap
thinning indicated

3 months after the surgery



Hair transplantation indicated
Orthognathic surgery suggested

**2 months after the submental lipofilling
in June 2016**



Figure 12. Surgical management of patient.

(PAP) flap (Figure 12). Before the operation, computed tomography angiography was performed and it showed more sufficient perforant vessels on the right side. During the surgical procedure, the patient was placed in the lithotomy position and was operated on by 2 surgical teams at the same time. After the localization of the right PAP with a handheld Doppler probe, the landmarks of the flap were drawn as an ellipse including the dominant

perforator 2 to 3 cm posterior to the gracilis muscle. The superior line was marked 1 cm below the gluteal fold, reaching the anterior gracilis muscle medially and the gluteal crease posteriorly. The inferior line was defined by the size of the flap required, 9 cm inferior to the superior line. An incision was performed on the lateral border of the planned flap preparing the perforant vessels - which are mostly localized 2 cm behind the gracilis muscle - subfascially. The fibers of the adductor magnus muscle were gently separated, reaching the origin and drainage of the perforant vessels and producing a 9-cm-long pedicle with the artery and vein, whose diameter was 1 mm (at the origin of the right deep femoral artery) and 2 mm (at the drainage into the right deep femoral vein), respectively (Figure 13A). The forepart of the flap was cut by an epifascial preparation. Finally, a flap with a size of 9x5 cm was mobilized. A preauricular incision was made to prepare the recipient area. The skin of the cheek was undermined to the infraorbital margin proximally, the nasolabial fold medially, and the mandibular body distally (Figure 13B); the left facial vessels with a length

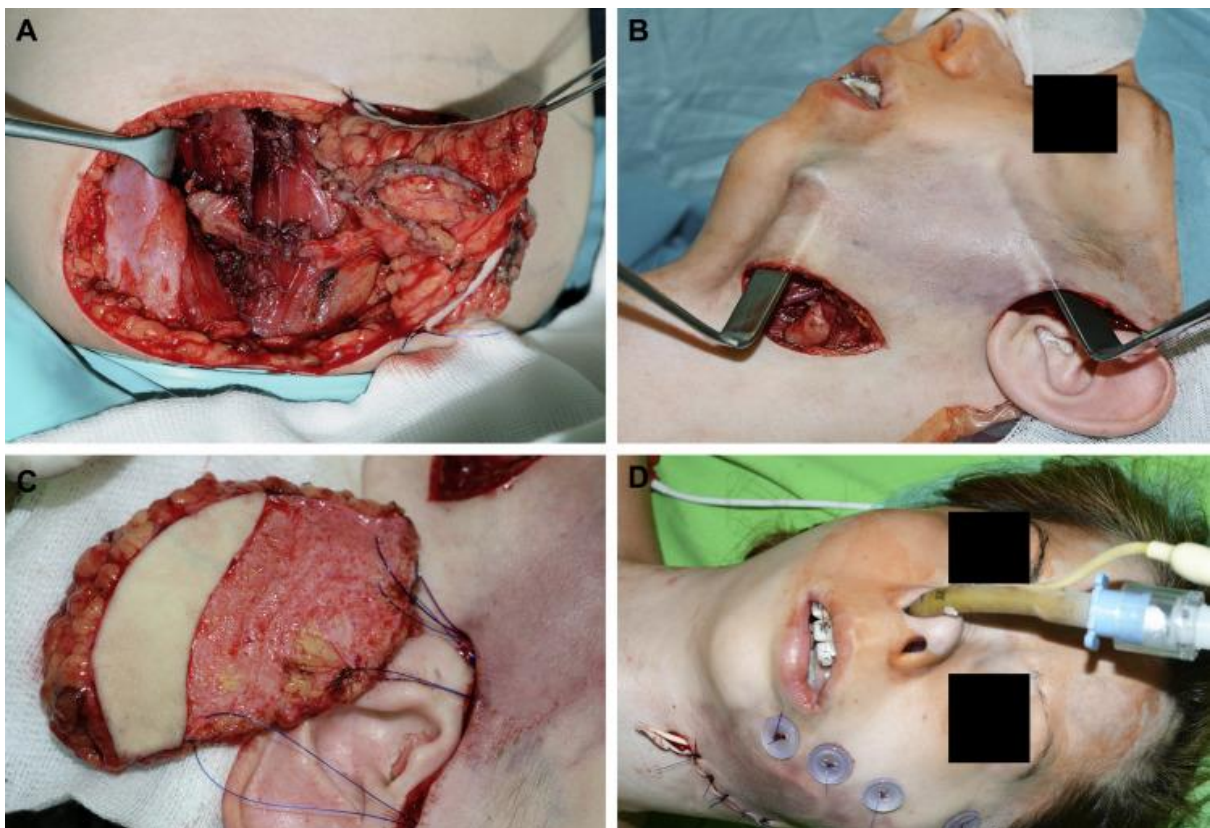

Figure 13. Preparation of profunda artery perforator flap (A) and subcutaneous tunnel (B) on left side of face and positioning (C) and fixation (D) of de-epithelialized flap.

of 4 cm were prepared from a transverse incision, forming a subcutaneous tunnel between these regions. The flap was transplanted to the left facial region, and the pedicle was led to the neck through the tunnel. End-to-end anastomoses were applied with 2 half continuous stitches in the vein and simple interrupted stitches in the artery by use of No. 8.0 and 9.0 monofil, nonabsorbable sutures (Prolene; Ethicon, New Brunswick, NJ). The ischemia time was 117 minutes. The flap was de-epithelialized and positioned subcutaneously. A monitor skin flap with a size of 3x1 cm was left preauricularly to observe the circulation of the flap (Figure 13C, D). The recipient and donor sites were closed primarily. Because the patient was young and had no history of hypercoagulability, anticoagulant therapy was not administered and she was mobilized on the day of the operation. During the surgical procedure, it is not possible to determine the thickness of the flap at the recipient site because of the interstitial edema and hemorrhage that develop locally. Therefore, a thicker flap is more favorable in this situation with its correction at a later time (eg, cut or liposuction), creating a symmetric facial appearance. It takes approximately 1 year for a scar to reach its final form, and the efficacy of lipofilling also can be determined at that time together with the indication of further correction. In our patient, after the absorption of tissue fluids, the 3-month follow-up showed a better esthetic outcome without any complications during the recovery period (Figure 14A). Because the quality and quantity of the facial skin around the monitor flap were found to be appropriate and the preauricular

monitor flap might have resulted in a less esthetic appearance, 1 year after the first operation, the monitor flap was cut out, the flap was thinned, and the wound was primarily closed after lipofilling in the mental region. In view of the improved facial appearance and better symmetry, the main complaint of the patient has been managed successfully (Figure 14B). The alopecia will be resolved with hair transplantation performed by a plastic surgeon.

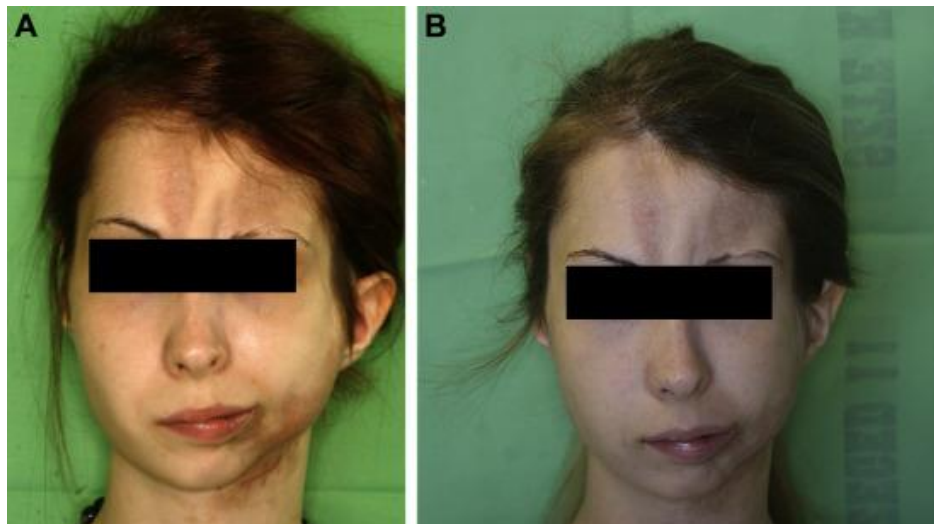


Figure 14. Appearance of patient 3 months (A) and approximately 1 year (B) after first surgery.

5. DISCUSSION

5.1. Commonly used free flaps for the reconstruction of the head and neck region

Oral soft tissues include tongue, floor of mouth, buccal mucosa and the retromolar region. These regions are not involved separately, so the reconstructive management is usually determined by the extent of surgical resection. Surgical resection of a malignant tumor in the head and neck region as part of complex oncological management has a considerable impact on the clinical outcome. These procedures often result in severe defects not only in the craniofacial bones, but also in the soft tissue coverage and function of the mimetic muscles, and the complexity of these lesions necessitates the use of different types of tissues with different functions for the reconstruction.

Small defects within the oral cavity can be closed with local mucosal flaps. Regional flaps such as pectoralis major and deltopectoral can be effective in importing tissue, but are not generally considered as a first choice.

Microsurgical techniques and reconstruction with free flaps provide the mainstay of oral soft tissue reconstructions as they allow importation of large volumes of healthy tissue from sites distant to prior surgical or radiotherapy fields. Radial forearm or anterolateral thigh flaps are commonly used, if the defects involve only soft tissues, however, there are certain clinical cases where the latissimus dorsi, rectus abdominus and flaps based on the scapular and/or para-scapular axis are utilised. Radial forearm flap allows for transplantation of a large, thin, pliable flap with excellent reliability and simplicity of harvest, with the possibility of design of multiple skin paddles (e.g. cutaneous, fasciocutaneous, fascial, adipofascial, osseo-fascial or osseo-cutaneous flap). The poor donor site aesthetic is a considerable disadvantage of this flap. In contrast with radial

forearm flap, the anterolateral thigh flap (fascio-cutaneous or fascial) allows for transplantation of very large tissue volumes. Although it is a relatively thick flap, but it can be thinned, if necessary. In some cases, more perforating vessels are available, which allows to raise multiple paddles. Because of minimal donor site morbidity, the use of this flap is increasing dynamically [Ragbir M 2016].

The recovery of maxillofacial integrity can be achieved by means of free or vascularized autologous bone transplantation, but allogeneic bone or artificial materials also play an important role in the reconstruction of maxillofacial defects. The soft tissue coverage is a basic part of the primary treatment. While local and regional flaps offer a simple practicable solution, free flaps (currently applied in an increasing number) can provide significantly more satisfactory esthetic and functional results [Ragbir M 2016].

Reconstruction of the mandible depends on the site and size of the bony defect, extent of soft tissue defect and the claim to dental rehabilitation. Fibula, deep circumflex iliac artery, scapular or radial forearm osteocutaneous flaps are commonly used for the reconstruction of the mandible with high success rates, which can be modified to fit the desired shape, have good vascularisation and are amenable to osseointegration. Fibular flap may provide a relatively long bone for the reconstruction of the mandible, and it can be osteotomised for contouring. The availability of software facilitates to plan the osteotomies prior to transfer the fibula. Osseous or osteoseptocutaneous flap can be harvested. High bony segment can be provided with the deep circumflex iliac artery flap, which has a natural curve, lending to lateral mandibular defects. The skin paddle can be reserved for external use, while muscle can be incorporated for oral reconstruction. In contrast with the above mentioned flaps, scapular flap can provide only a relatively small amount of bone, but large volume of skin and muscle (latissimus dorsi) can be used. Since patient positioning can be complicated during harvesting of this flap, it is not so preferable, like fibula flap. Also,

radial forearm flap is rarely used for the reconstruction of the mandible because of its small volume and low height, and the potential subsequent fracture after the harvesting. However, there are certain classifications, which may help to choose the appropriate flap for the reconstruction of the mandible [Ragbir M 2016].

It can be concluded, that there is no available evidence-based knowledge in all areas of reconstruction, and more particularly in the maxilla and midface. The nature of the midfacial defects also determines the choice of a prosthetic option or reconstruction, regarding a recently published classification and professional experience [Ragbir M 2016].

5.2. Individualized planning during the reconstructive surgical management in the head and neck region

The literature provides only a limited number of recommendations as concerns the management of basal cell carcinoma with an extensive tissue defect. Various local flaps, such as a paramedian forehead flap, a lateral cheek rotation flap or a platysma myocutaneous flap, can be applied for the reconstruction of large maxillofacial defects after malignant lesion resection [Kumar SLK 2014]. However, a study involving 685 patients with 765 basal cell carcinomas suggested that a better functional and esthetic result can be achieved through the use of pedicled flaps [Piesold JU 2005].

A common complication such as facial paralysis after maxillofacial surgery has a great impact on the social interaction of the patient. The aim of dynamic facial reconstruction is to achieve a symmetrical and coordinated smile, an enhanced cheek tone, improved speech and the ability to eat [Coyle M 2013]. Coyle et al. published an algorithm for the therapeutic approaches to facial palsy at different stages after the neural impairment, but possible soft tissue defects were not considered [Coyle M 2013]. Chuang discussed the

therapeutic possibilities of long-standing facial paralysis, emphasizing the feasibility of regional muscle and microvascular free tissue transfer. While regional muscle transfer is reliable and provides the immediate return of movement without a spontaneous mimetic nature, it usually requires multiple surgery [Chuang DC 2008, Robey AB 2011]. Although these methods are often unable to restore full maxillofacial integrity and balance the facial movements, they are options for patients not eligible for free micro-neurovascular reconstruction [White H 2013, Matic DB 2012]. Free flaps can provide synchronous, mimetic movement, but a prolonged healing time may be required [Chuang DC 2008]. With regard to the extensive soft tissue defect after the surgical resection of the tumorous lesion and the general state of health of our patient, we applied an ALT chimeric flap to reconstruct soft tissue defect and to correct the facial paralysis. The blood supply of this flap is supported by the descending branch of the lateral circumflex femoral artery, its applicability therefore requiring a complex reconstructive solution [Song YG 1984].

The myocutaneous ALT flap can readily be obtained and may provide a good amount of muscle for filling of the tissue defect, together with the chance to reconstruct the bony defect in the craniofacial region. The thickness of the subcutaneous fat in the anterolateral area can be modified in order to achieve the necessary flap thickness, which makes it highly suitable for the surgical treatment of oral and maxillofacial defects [Wolff KD 1998, Ren ZH 2014]. Donor site morbidity, such as reduced sensitivity around the scar, is a common complaint of the patients [Wolff KD 1995, Kimata Y 2000, Wolf KD 2006, Townley WA 2011]. However, the donor site defect both esthetically and functionally in our case was minimal, and the quadriceps function was not affected.

The dynamic reconstruction of facial palsy demands careful patient selection and an appropriate surgical technique if excellent results are to be expected [Coyle M 2013]. A number of studies have revealed that significantly better functional results are achieved if

reconstruction surgery is performed within 2 years [Momeni A 2013, Terzis JK 2013]. Single-stage surgery (reconstruction of both the soft tissue defect and the facial palsy) may provide a better outcome, but the general state of health of a patient has to be considered and multistage operations may be unavoidable in certain cases. Various nerve grafts, such as those of the masseteric or segmental branch, influence the functional and aesthetic results. While the masseteric nerve guarantees free voluntary gracilis muscle activation without any spontaneous smiling, free flaps innervated by the segmental branch have a lower success rate and result in less movement; however, spontaneous smiling can be observed [Biglioli F 2012]. The age and expectations of our patient played an important role in the management of the maxillofacial integrity, including the decision concerning the microvascular free tissue transfer combined with the segmental nerve branch.

There is professional disagreement concerning the proper timing and method of complex surgical management of patients with PHA. Evidence-based knowledge is not available, but it is generally agreed that the surgical procedure should ideally follow the stabilization of the disease process and the completion of facial growth.¹ However, an early intervention may reduce negative psychosocial effects and improve patient satisfaction, but it also can necessitate further surgical procedures [Slack GC 2012].

The main goal of surgical treatment in PHA is to restore the facial contour and resolve facial asymmetry. The surgical possibilities are numerous and largely dependent on the severity of the defect. Slight deformities can be treated with autologous lipotransfer, whereas microvascular flap procedures provide long-term contour correction in severe cases [Agostini T 2014]. The main drawback of lipotransfer or injection is subsequent absorption, resulting in substantial shrinkage of the injected fat volume, which may reach a volume of about 65% of the transplanted tissue over the first few months. The results can be improved or maintained with the use of tissue-derived stem cells and proper

centrifugation technique, but fat injection and an en bloc technique also provide a low absorption rate with a relatively nonvisible scar [Livaoğlu M 2009, Koh KS 2012]. The body type of the patient also can pose a problem because it is difficult to harvest fat tissue from thin patients.

The selection of the proper flap is based on the amount and shape of the soft tissue defect, but sometimes on the expectations of the patient as well. In the case of severe defects, a combined approach using soft tissue and bone augmentation is commonly required. Microvascular flaps combined with orthognathic surgery and/or bone augmentation are considered the gold standard in the restoration of facial asymmetry [HU J 2011]. Multiple microvascular free flaps have been used successfully in the treatment of PHA, including omentum, rectus, latissimus, serratus, deep inferior epigastric perforator (DIEP), anterolateral thigh (ALT), or parascapular flaps [Jurkiewicz MJ 1985, Siebert JW 1996, Cheng J 2010, Wójcicki P 2011, Si L 2012]. The largest disadvantage of musculocutaneous flaps is the inactivity-related tissue atrophy that is difficult to predict, which results in failure to fill the atrophied soft tissues. Inframammary extended circumflex scapular (IMECS) flaps are commonly used in our department to restore hemifacial atrophy of various causes (eg, facial palsy). This flap has a robust blood supply with low anatomic variability; it can provide the appropriate size; and during the operation, the structure or extension (eg, full-thickness flap with de-epithelialized skin; flap containing fat and fascia, in which fat can be thinned; or flap containing only fascia folded according to the needs of the recipient site) can be modified, as necessary [Siebert JW 1997, Albarah A 2010]. The primary arguments against an IMECS flap in this case were (1) the asthenic body type of the patient, which would have resulted in a 4- to 5-mm thinner flap than a PAP flap; (2) the visible scar on the back; and (3) the position of the patient during the operation, which would not allow the simultaneous work of 2 surgical teams. DIEP flaps are usually too thick

for facial reconstruction and very vulnerable for flap thinning techniques [Chana JS 2010, Prasetyono TO 2014]. Thoracodorsal artery perforator flaps also can be used in head and neck reconstructive surgery, and they are modifiable as an IMECS flap [Guerra AB 2005]. Although flap harvesting can be performed with the patient in the supine position, this does not provide appropriate accessibility for simultaneous surgery. Because our patient refused to undergo surgical methods that would leave visible scars at the donor sites (eg, IMECS or thoracodorsal artery perforator flap) and the use of the DIEP flap was not feasible because of her body type, another solution had to be found.

Because of the unmodifiable explicit absorption of musculocutaneous flaps, fasciocutaneous flaps are more frequently adopted and used for the reconstruction of hemifacial microsomia or facial asymmetry [Siebert JW 1996, Tanna N 2011]. The posteromedial thigh region, first described by Ahmadzadeh et al in 2007, is a relatively novel donor site in reconstructive surgery [Ahmadzadeh R 2007]. Allen and colleagues first used it for breast reconstruction, and their surgical team also provided a more detailed anatomic description of the special characteristics of this particular flap [Allen RJ 2012, Saad A 2012]. Recently, PAP flaps have been used for breast reconstruction in which abdominal donor sites were not desirable, and some articles have shown their use as a pedicle flap for vulvar reconstruction [Healy C 2014, Huang JJ 2015]. Just a few publications can be found regarding the use of PAP flaps in the maxillofacial region. However, these have shown a survival rate similar to conventional flap types (radial forearm or ALT flaps) for head and neck reconstruction, as well as a relative ease of harvest [Scaglioni MF 2015, Mayo JL 2016, Wu JC 2016]. The main advantages are a reliable blood supply, sufficient pedicle length (approximately 10 cm) to reach the neck, thick donor tissue, and relatively favorable donor site [Saad A 2012, Wu JC 2016]. Previous publications have suggested that a PAP flap may be a good alternative to an ALT flap in

head and neck reconstruction if the perforant vessel of the ALT flap is not suitable (in approximately 5% of cases) or if the esthetic result at the donor site is more important (eg, young patients) [Mayo JL 2016, Wu JC 2016, Lu JC 2015].

Because the asthenic body type and the expectations of our patient did not allow the use of other fasciocutaneous flaps, we hypothesized that the PAP flap would offer a good alternative. This flap permits simultaneous surgery by 2 teams and provides a relatively large size (up to 8×28 cm) and long pedicle length with proper vessel diameters, and if the surgical incision does not extend beyond the midline of the gluteal crease, the scar is barely visible [Saad A 2012, Wu JC 2016]. This flap harvested from the upper medial and posterior thigh contains skin and fat tissue, providing a sufficient flap size even in a thin patient for reconstructing soft tissue defects; however, the narrow width can limit the harvested tissue volume [Garcia-de la Torre I 1995]. Unlike IMECS flaps, in which the same anatomic situation almost always can be found, in the case of PAP flaps, computed tomography angiography is necessary to determine the suitability of the perforant vessel [Siebert JW 1997, Haddock NT 2012]. Although PAP flaps are not as modifiable as IMECS flaps, the PAP flap's thickness better matched the recipient site in this case and it provided a barely visible scar in the gluteal fold. As in our case, PAP flaps are suitable to minimize facial asymmetry and to replace soft tissue defects. This case report may draw attention to the importance of interdisciplinary cooperation and individualized surgical management of patients. However, further clinical investigations and experience or prospective multicenter studies are required to evaluate the clinical significance and more common use of the PAP flap in head and neck reconstructive surgery.

6. CONCLUSIONS

Laser-Doppler flowmetry requires some experience, especially during the analysis, however it is a well-reproducible and non-invasive method for the detection of the microcirculatory changes of free flaps.

Oncological surgery in the head and neck region can often lead to complex functional and aesthetical defects. The management of these extensive impairments often involves therapeutic difficulties, and the surgeon may have to seek new opportunities to achieve acceptable results. In general, single-stage surgery is associated with fewer complications and better neural regeneration. The chimeric type I ALT flap can be a good option for facial dynamic reconstruction, but the surgeon must also consider individual anatomical variation and other potential therapeutic solutions with a view to obtaining a satisfactory clinical outcome.

This is the first description of the use of a PAP-flap for the reconstruction of facial deformity in a patient with PHA. To choose the best therapeutic option for patients, all potential treatment modalities have to be considered, which may be influenced by the physical status or request of the patient, sometimes necessitating the use of uncommon reconstructive surgical solutions. We have to emphasize the importance of interdisciplinary cooperation, the development of surgical skills and knowledge, which are essential for the proper management of complex cases. PAP flaps may be useful in certain cases where the individual surgical plan has a particular intended impact, and the surgeon has the possibility to choose from a wider armamentarium instead of being forced to apply the most frequently used flaps (radial forearm and ALT flaps) when solving a surgical situation in the head and neck region.

7. SUMMARY OF NEW FINDINGS

1. this is the first description of the use of a PAP-flap for the reconstruction of facial deformity Europe,
2. this is the first description of the use of a PAP-flap for the reconstruction of facial deformity in a patient with PHA

8. ACKNOWLEDGEMENTS

I am grateful to Professor József Piffkó for initiating my scientific career and for providing me with the opportunity to carry out my scientific work in the Department of Oral and Maxillofacial Surgery under his scientific guidance and with his help. I am indebted to Dr. Ágnes Janovszky, who helped me and granted me unlimited assistance in writing publications. I thank Professor Zsolt Molnár, Dr. Domonkos Trásy and Ildikó László for their cooperation in the clinical studies. My special thanks are due to all the staff at the Department of Oral and Maxillofacial Surgery for their skillful assistance.

9. REFERENCES

1. Agaimy A, Mueller SK, Harrer T, Bauer S, Thompson LDR. Head and Neck Kaposi Sarcoma: Clinicopathological Analysis of 11 Cases. *Head Neck Pathol.* 2018;12(4):511-516.
2. Agostini T, Spinelli G, Marino G, Perello R. Esthetic restoration in progressive hemifacial atrophy (Romberg disease): structural fat grafting versus local/free flaps. *J Craniofac Surg.* 2014;25(3):783-7.
3. Ahmadzadeh R, Bergeron L, Tang M, Geddes CR, Morris SF. The posterior thigh perforator flap or profunda femoris artery perforator flap. *Plast Reconstr Surg.* 2007;119(1):194-200; discussion 201-2.
4. Albarah A, Kishk T, Megahed M, Elsakka D, Ghareeb F. Pre-expanded Extended Island Parascapular Flap for Reconstruction of Post-burn Neck Contracture. *Ann Burns Fire Disasters.* 2010;23(1):28-32.
5. Allen RJ, Haddock NT, Ahn CY, Sadeghi A. Breast reconstruction with the profunda artery perforator flap. *Plast Reconstr Surg.* 2012;129(1):16e-23e.
6. Biglioli F, Colombo V, Tarabbia F, Autelitano L, Rabbiosi D, Colletti G, Giovanditto F, Battista V, Frigerio A. Recovery of emotional smiling function in free-flap facial reanimation. *J Oral Maxillofac Surg.* 2012;70(10):2413-2418.
7. Beynon RA, Lang S, Schimansky S, Penfold CM, Waylen A, Thomas SJ, Pawlita M, Waterboer T, Martin RM, May M, Ness AR. Tobacco smoking and alcohol drinking at diagnosis of head and neck cancer and all-cause mortality: Results from head and neck 5000, a prospective observational cohort of people with head and neck cancer. *Int J Cancer.* 2018;143(5):1114-1127.

8. Blot WJ, McLaughlin JK, Winn DM, Austin DF, Greenberg RS, Preston-Martin S, Bernstein L, Schoenberg JB, Stemhagen A, Fraumeni JF Jr. Smoking and drinking in relation to oral and pharyngeal cancer. *Cancer Res.* 1988;48(11):3282-7.
9. Chana JS, Odili J. Perforator flaps in head and neck reconstruction. *Semin Plast Surg.* 2010;24(3):237-54.
10. Chaturvedi AK, Engels EA, Pfeiffer RM, Hernandez BY, Xiao W, Kim E, Jiang B, Goodman MT, Sibug-Saber M, Cozen W, Liu L, Lynch CF, Wentzensen N, Jordan RC, Altekruze S, Anderson WF, Rosenberg PS, Gillison ML. Human papillomavirus and rising oropharyngeal cancer incidence in the United States. *J Clin Oncol.* 2011;29(32):4294-301.
11. Chana JS, Odili J. Perforator flaps in head and neck reconstruction. *Semin Plast Surg.* 2010;24(3):237-54.
12. Chuang DC. Free tissue transfer for the treatment of facial paralysis. *Facial Plast Surg.* 2008;24:194-203.
13. Coyle M, Godden A, Brennan PA, Cascarini L, Coombes D, Kerawala C, McCaul J, Godden D. Dynamic reanimation for facial palsy: an overview. *Br J Oral Maxillofac Surg.* 2013;51(8):679-683.
14. Fakhry C, Westra WH, Wang SJ, van Zante A, Zhang Y, Rettig E, Yin LX, Ryan WR, Ha PK, Wentz A, Koch W, Richmon JD, Eisele DW, D'Souza G. The prognostic role of sex, race, and human papillomavirus in oropharyngeal and nonoropharyngeal head and neck squamous cell cancer. *Cancer.* 2017;123(9):1566-1575.
15. Franceschi S, Talamini R, Barra S, Barón AE, Negri E, Bidoli E, Serraino D, La Vecchia C. Smoking and drinking in relation to cancers of the oral cavity, pharynx, larynx, and esophagus in northern Italy. *Cancer Res.* 1990;50(20):6502-7.

16. Garcia-de la Torre I, Castello-Sendra J, Esgleyes-Ribot T, Martinez-Bonilla G, Guerrerosantos J, Fritzler MJ. Autoantibodies in Parry-Romberg syndrome: a serologic study of 14 patients. *J Rheumatol.* 1995;22(1):73-7.
17. Guerra AB, Lyons GD, Dupin CL, Metzinger SE. Advantages of perforator flaps in reconstruction of complex defects of the head and neck. *Ear Nose Throat J.* 2005;84(7):441-7.
18. Gupta PC, Murti PR, Bhonsle RB, Mehta FS, Pindborg JJ. Effect of cessation of tobacco use on the incidence of oral mucosal lesions in a 10-yr follow-up study of 12,212 users. *Oral Dis.* 1995;1(1):54-8.
19. Haddock NT, Greaney P, Otterburn D, Levine S, Allen RJ. Predicting perforator location on preoperative imaging for the profunda artery perforator flap. *Microsurgery.* 2012;32(7):507-11.
20. Hashibe M, Brennan P, Benhamou S, Castellsague X, Chen C, Curado MP, Dal Maso L, Daudt AW, Fabianova E, Fernandez L, Wünsch-Filho V, Franceschi S, Hayes RB, Herrero R, Koifman S, La Vecchia C, Lazarus P, Levi F, Mates D, Matos E, Menezes A, Muscat J, Eluf-Neto J, Olshan AF, Rudnai P, Schwartz SM, Smith E, Sturgis EM, Szeszenia-Dabrowska N, Talamini R, Wei Q, Winn DM, Zaridze D, Zatonski W, Zhang ZF, Berthiller J, Boffetta P. Alcohol drinking in never users of tobacco, cigarette smoking in never drinkers, and the risk of head and neck cancer: pooled analysis in the International Head and Neck Cancer Epidemiology Consortium. *J Natl Cancer Inst.* 2007;99(10):777-89.
21. Hashibe M, Brennan P, Chuang SC, Boccia S, Castellsague X, Chen C, Curado MP, Dal Maso L, Daudt AW, Fabianova E, Fernandez L, Wünsch-Filho V, Franceschi S, Hayes RB, Herrero R, Kelsey K, Koifman S, La Vecchia C, Lazarus P, Levi F, Lence JJ, Mates D, Matos E, Menezes A, McClean MD, Muscat J, Eluf-Neto J,

- Olshan AF, Purdue M, Rudnai P, Schwartz SM, Smith E, Sturgis EM, Szeszenia-Dabrowska N, Talamini R, Wei Q, Winn DM, Shangina O, Pilarska A, Zhang ZF, Ferro G, Berthiller J, Boffetta P. Interaction between tobacco and alcohol use and the risk of head and neck cancer: pooled analysis in the International Head and Neck Cancer Epidemiology Consortium. *Cancer Epidemiol Biomarkers Prev.* 2009;18(2):541-50.
22. Healy C, Allen RJ Sr. The evolution of perforator flap breast reconstruction: twenty years after the first DIEP flap. *J Reconstr Microsurg.* 2014;30(2):121-5.
23. Huang JJ, Chang NJ, Chou HH, Wu CW, Abdelrahman M, Chen HY, Cheng MH. Pedicle perforator flaps for vulvar reconstruction--new generation of less invasive vulvar reconstruction with favorable results. *Gynecol Oncol.* 2015;137(1):66-72.
24. Hu J, Yin L, Tang X, Gui L, Zhang Z. Combined skeletal and soft tissue reconstruction for severe Parry-Romberg syndrome. *J Craniofac Surg.* 2011;22(3):937-41.
25. Jou A, Hess J. Epidemiology and Molecular Biology of Head and Neck Cancer. *Oncol Res Treat.* 2017;40(6):328-332.
26. Jurkiewicz MJ, Nahai F. The use of free revascularized grafts in the amelioration of hemifacial atrophy. *Plast Reconstr Surg.* 1985;76(1):44-55.
27. Kimata Y, Uchiyama K, Ebihara S, Sakuraba M, Iida H, Nakatsuka T, Harii K. Anterolateral thigh flap donor-site complications and morbidity. *Plast Reconstr Surg.* 2000;106(3):584-589.
28. Koh KS, Oh TS, Kim H, Chung IW, Lee KW, Lee HB, Park EJ, Jung JS, Shin IS, Ra JC, Choi JW. Clinical application of human adipose tissue-derived mesenchymal stem cells in progressive hemifacial atrophy (Parry-Romberg disease) with microfat

- grafting techniques using 3-dimensional computed tomography and 3-dimensional camera. *Ann Plast Surg.* 2012;69(3):331-7.
29. Kumar M, Nanavati R, Modi TG, Dobariya C. Oral cancer: Etiology and risk factors: A review. *J Cancer Res Ther.* 2016;12(2):458-63.
30. Kumar SLK, Khalam SA, Jacob MM, Manuel S, Kurien NM, Varghese MP. Maxillofacial reconstruction following the excision of basal cell carcinoma: Case report. *OA Case Reports* 2014;18;3(7):63.
31. Lewis A, Kang R, Levine A, Maghami E. The New Face of Head and Neck Cancer: The HPV Epidemic. *Oncology (Williston Park).* 2015;29(9):616-26.
32. Livaoglu M, Yavuz E. Soft tissue augmentation with autologous fat graft: the dissected pouch technique. *J Cutan Aesthet Surg.* 2009;2(1):21-5.
33. Lu JC, Zelken J, Hsu CC, Chang NJ, Lin CH, Wei FC, Lin CH. Algorithmic approach to anterolateral thigh flaps lacking suitable perforators in lower extremity reconstruction. *Plast Reconstr Surg.* 2015;135(5):1476-85.
34. Marur S, Forastiere AA. Head and Neck Squamous Cell Carcinoma: Update on Epidemiology, Diagnosis, and Treatment. *Mayo Clin Proc.* 2016;91(3):386-96.
35. Matic DB, Yoo J. The pedicled masseter muscle transfer for smile reconstruction in facial paralysis: repositioning the origin and insertion. *J Plast Reconstr Aesthet Surg.* 2012;65(8):1002-1008.
36. Mayo JL, Allen RJ, Sadeghi A. Four-flap Breast Reconstruction: Bilateral Stacked DIEP and PAP Flaps. *Plast Reconstr Surg Glob Open.* 2015;3(5):e383.
37. Myers EN. Head and neck oncology-2010, Part I. *Otolaryngol Pol.* 2010;64(3):136-46.
38. Myers EN. Head and neck oncology-2010, part II. *Otolaryngol Pol.* 2010;64(4):204-14.

39. Momeni A, Chang J, Khosla RK. Microsurgical reconstruction of the smile--contemporary trends. *Microsurgery*. 2013;33(1):69-76.
40. Peterson CE, Khosla S, Chen LF, Joslin CE, Davis FG, Fitzgibbon ML, Freels S, Hoskins K. Racial differences in head and neck squamous cell carcinomas among non-Hispanic black and white males identified through the National Cancer Database (1998-2012). *J Cancer Res Clin Oncol*. 2016;142(8):1715-26.
41. Picard A, Arowas L, Piroth L, Heard I, Ferry T; ORL-HIV-HPV study group. Head and neck squamous cell carcinoma in people living with HIV in France. *Med Mal Infect*. 2018;48(8):503-508.
42. Piesold JU, Vent S, Krüger R, Pistner H. Treatment results after surgery for basal cell carcinomas of the head and neck region taking into consideration various reconstruction techniques. *Mund Kiefer Gesichtschir*. 2005;3:143-151.
43. Prasetyono TO, Bangun K, Buchari FB, Rezkini P. Practical considerations for perforator flap thinning procedures revisited. *Arch Plast Surg*. 2014;41(6):693-701.
44. Ragbir M, Brown JS, Mehanna H. Reconstructive considerations in head and neck surgical oncology: United Kingdom National Multidisciplinary Guidelines. *J Laryngol Otol*. 2016;130(S2):S191-S197.
45. Ren ZH, Wu HJ, Wang K, Zhang S, Tan HY, Gong ZJ. Anterolateral thigh myocutaneous flaps as the preferred flaps for reconstruction of oral and maxillofacial defects. *J Craniomaxillofac Surg*. 2014;42(8):1583-1589.
46. Rettig EM, D'Souza G. Epidemiology of head and neck cancer. *Surg Oncol Clin N Am*. 2015;24(3):379-96.
47. Robey AB, Snyder MC. Reconstruction of the paralyzed face. *Ear Nose Throat J*. 2011;90(6):267-275.

48. Saad A, Sadeghi A, Allen RJ. The anatomic basis of the profunda femoris artery perforator flap: a new option for autologous breast reconstruction-a cadaveric and computer tomography angiogram study. *J Reconstr Microsurg.* 2012;28(6):381-6.
49. Scaglioni MF, Kuo YR, Yang JC, Chen YC. The Posteromedial Thigh Flap for Head and Neck Reconstruction: Anatomical Basis, Surgical Technique, and Clinical Applications. *Plast Reconstr Surg.* 2015;136(2):363-75.
50. Schlecht NF, Franco EL, Pintos J, Kowalski LP. Effect of smoking cessation and tobacco type on the risk of cancers of the upper aero-digestive tract in Brazil. *Epidemiology.* 1999;10(4):412-8.
51. Scully C, Field JK, Tanzawa H. Genetic aberrations in oral or head and neck squamous cell carcinoma (SCCHN): 1. Carcinogen metabolism, DNA repair and cell cycle control. *Oral Oncol.* 2000;36(3):256-63.
52. Settle K, Posner MR, Schumaker LM, Tan M, Suntharalingam M, Goloubeva O, Strome SE, Haddad RI, Patel SS, Cambell EV 3rd, Sarlis N, Lorch J, Cullen KJ. Racial survival disparity in head and neck cancer results from low prevalence of human papillomavirus infection in black oropharyngeal cancer patients. *Cancer Prev Res (Phila).* 2009;2(9):776-81.
53. Siebert JW, Anson G, Longaker MT. Microsurgical correction of facial asymmetry in 60 consecutive cases. *Plast Reconstr Surg.* 1996;97(2):354-63.
54. Siebert JW, Longaker MT, Angrigiani C. The inframammary extended circumflex scapular flap: an aesthetic improvement of the parascapular flap. *Plast Reconstr Surg.* 1997;99(1):70-7.
55. Si L, Zeng A, Qiao Q, Liu Z, Zhao R, Wang Y, Zhu L, Wang X. Microsurgical correction of progressive facial hemiatrophy using free anterolateral thigh adipofascial flap. *J Craniofac Surg.* 2012;23(7 Suppl 1):2051-6.

56. Simard EP, Torre LA, Jemal A. International trends in head and neck cancer incidence rates: differences by country, sex and anatomic site. *Oral Oncol.* 2014;50(5):387-403.
57. Slack GC, Tabit CJ, Allam KA, Kawamoto HK, Bradley JP. Parry-Romberg reconstruction: optimal timing for hard and soft tissue procedures. *J Craniofac Surg.* 2012;23(7 Suppl 1):1969-73.
58. Song YG, Chen GZ, Song YL. The free thigh flap: a new free flap concept based on the septocutaneous artery. *Br J Plast Surg.* 1984;37(2):149-159.
59. Tanna N, Wan DC, Kawamoto HK, Bradley JP. Craniofacial microsomia soft-tissue reconstruction comparison: inframammary extended circumflex scapular flap versus serial fat grafting. *Plast Reconstr Surg.* 2011;127(2):802-11.
60. Terzis JK, Konofaos P. Reanimation of facial palsy following tumor extirpation in pediatric patients: our experience with 16 patients. *J Plast Reconstr Aesthet Surg.* 2013;66(9):1219-1229.
61. Thun M, Peto R, Boreham J, Lopez AD. Stages of the cigarette epidemic on entering its second century. *Tob Control.* 2012;21(2):96-101.
62. Townley WA, Royston EC, Karmiris N, Crick A, Dunn RL. Critical assessment of the anterolateral thigh flap donor site. *J Plast Reconstr Aesthet Surg.* 2011;64(12):1621-1626.
63. Vineis P, Alavanja M, Buffler P, Fontham E, Franceschi S, Gao YT, Gupta PC, Hackshaw A, Matos E, Samet J, Sitas F, Smith J, Stayner L, Straif K, Thun MJ, Wichmann HE, Wu AH, Zaridze D, Peto R, Doll R. Tobacco and cancer: recent epidemiological evidence. *J Natl Cancer Inst.* 2004;96(2):99-106.
64. Vokes EE, Agrawal N, Seiwert TY. HPV-Associated Head and Neck Cancer. *J Natl Cancer Inst.* 2015;107(12):d1v344.

65. Warnakulasuriya KA, Johnson NW, Linklater KM, Bell J. Cancer of mouth, pharynx and nasopharynx in Asian and Chinese immigrants resident in Thames regions. *Oral Oncol.* 1999;35(5):471-5.
66. White H, Rosenthal E. Static and dynamic repairs of facial nerve injuries. *Oral Maxillofac Surg Clin North Am.* 2013;25(2):303-312.
67. Wójcicki P, Zachara M. Surgical treatment of patients with Parry-Romberg syndrome. *Ann Plast Surg.* 2011;66(3):267-72.
68. Wolff KD, Howaldt HP. Three years of experience with the free vastus lateralis flap: an analysis of 30 consecutive reconstructions in maxillofacial surgery. *Ann Plast Surg.* 1995;34(1):35-42.
69. Wolff KD. Indications for the vastus lateralis flap in oral and maxillofacial surgery. *Br J Oral Maxillofac Surg.* 1998;36(5):358-364.
70. Wolff KD, Kesting M, Thurmüller P, Böckmann R, Hölzle F. The anterolateral thigh as a universal donor site for soft tissue reconstruction in maxillofacial surgery. *J Craniomaxillofac Surg.* 2006;34(6):323-331.
71. Wu JC, Huang JJ, Tsao CK, Abdelrahman M, Kolios G, Cheng MH. Comparison of Posteromedial Thigh Profunda Artery Perforator Flap and Anterolateral Thigh Perforator Flap for Head and Neck Reconstruction. *Plast Reconstr Surg.* 2016;137(1):257-66.
72. Young D, Xiao CC, Murphy B, Moore M, Fakhry C, Day TA. Increase in head and neck cancer in younger patients due to human papillomavirus (HPV). *Oral Oncol.* 2015;51(8):727-30.

Appendix I.

Appendix II.

Appendix III.